THE TRUSTED JOURNAL OF MEDICAL SCIENCES

Established 1998

ISSN 1993-2863

نگاہِ بلند، سُخن دل نواز، جاں پُرسوز
یہی ہے رَختِ سفر، میرِ کارواں کیلئے
اقبال

INTERNATIONAL Ophthalmology Update

with Ophthalmic & General Sections

Vol. 13, No. 3 | Chief Editor: Prof. Dr. M. Yasin Khan Durrani | July - Sept, 2015

AFFILIATED TO PESHAWAR MEDICAL COLLEGE, RAWALPINDI MEDICAL COLLEGE & RIPHAH INTERNATIONAL UNIVERSITY

Published quarterly by Ophthalmic Newsnet from 267-A, St: 53, F-10/4, Islamabad
Phone: 051-2222922 Ext. 1255
Fax: 051-2291935
Mob: 0333-5158885
E-mail: ophthalmologyupdate@gmail.com
yasin.durrani@gmail.com
Website: www.ophthalmologyupdate.com

Subscription: Rs. 800/– Yearly
International: US $ 100/- Yearly

Ophthalmology Update is a controlled circulation journal for Medical profession. It does not guarantee, directly or indirectly the quality and efficacy of any product or service described in the advertisement or other material which is commercial or otherwise in this issue. All ideas forwarded reflect the individual views of the authors.

Registration: 3405/2/(63) under Press and Publication Ordinance '98, Govt. of Pakistan.

Circulation: Schazoo Pharmaceutical Lab. (Pvt) Ltd., Lahore by Mr. Omer Safdar, Business Unit Manager

Approved and Indexed by:
Pakistan Medical & Dental Council
Higher Education Commission,
ABC Certified

Printed at PanGraphics (Pvt) Ltd., Islamabad.

Contents

OPHTHALMOLOGY NOTEBOOK

وَلَقَدْ فَتَنَّا الَّذِيْنَ مِنْ قَبْلِهِمْ فَلَيَعْلَمَنَّ اللّٰهُ الَّذِيْنَ صَدَقُوْا وَلَيَعْلَمَنَّ الْكٰذِبِيْنَ

اور جو لوگ ان سے پہلے ہو چکے ہیں ہم نے انکو بھی آزمایا تھا اور انکو بھی آزمائیں گے سو اللہ انکو ضرور معلوم کرے گا جو اپنے ایمان میں سچے ہیں اور انکو بھی جو جھوٹے ہیں۔ العنکبوت، آیت ۳

Editorial

Age Related Macular Degeneration - Current Concept

Healthy lifestyles may reduce the risk for AMD

In age-related macular degeneration (AMD), the macular photoreceptors progressively degenerates with age, more quickly in some people than in others which may lead to advanced age-related macular degeneration. AMD is the world's leading cause of the loss of central vision. The dry form is characterized by the appearance of drusens - a proteinaceous collection, leading to atrophic changes of the epithelium and gradually shutting down the delivery of images to the brain. While in wet form, abnormal blood vessels leak blood and fluid causing scarring and further damage to the macula.

Like several other chronic progressive inflammatory diseases associated with aging contributes to the pathogenesis of AMD. The role of inflammation is supported by the detection of products like NLRP3 from the immune system (in drusens). The genome wide association studies have implicated several components of the complement cascade in the pathogenesis of this disease as indicated by the recent publications, one by Doyle et al. and the other by Tarallo et al. These studies are remarkably similar but different in approach. Mutations in NLRP3 have been identified as the cause of uncommon auto-inflammatory diseases known as cryopyrin-associated periodic syndromes. NLRP3 joins two other cytoplasmic proteins, ASC and procaspase-1, to form a complex called the inflammasome. This in turn, activates the enzyme caspase-1, which goes on to activate several intracellular proteins, including interleukin-1β and interleukin-18. Insights gained from these studies of the rare cryopyrin-associated periodic diseases have thus clarified the function of NLRP3 which have contributed to relatively common diseases like gout and rheumatoid arthritis mediated by the inflammasome. Doyle et al. has also found that drusen themselves activate NLRP3.

Now, in age-related macular degeneration the NLRP3-inflammasome is also induced by the complement component C1Q or enhanced by carboxy-ethylpyr-role, a protein modified by oxidative stress. Tarallo et al., found that NLRP3 is activated in patients with AMD, but this group used an RNA motif known as an ***Alu*** repeat to activate the inflammasome in mouse and tissue-culture studies. They had previously reported evidence supporting a role of *Alu* repeats in the pathogenesis of AMD. In most instances in which the inflammasome is activated, interleukin-1 becomes the major "protagonist." For example, the inherited diseases caused by mutations in *NLRP3* were nearly untreatable until recently, but they are now known to respond dramatically to interleukin-1 blockade.

Surprisingly, both groups concluded that the major consequence of activation of the inflammasome in the retina is the production of interleukin-18. Doyle et al., believed that the source is probably myeloid cells. Although NLRP3 is usually expressed predominantly in bone marrow–derived cells, Tarallo et al. contend that the retinal pigment epithelium is primarily responsible for interleukin-18. The two groups arrived at opposite conclusions about the consequence of interleukin-18 in AMD. Tarallo and colleagues found that

interleukin-18 promotes damage to the retinal pigment epithelium in a mouse model that mimics the dry form of AMD. Doyle and colleagues used a mouse model with choroidal neo-vascularization in wet AMD and concluded that interleukin-18 inhibits new vessel formation.

Thus, one group of authors concludes that inflammation in AMD is harmful and the other concludes that inflammation is beneficial. It is possible that both groups are right and that interleukin-18 has a dual role in AMD. If so, interleukin-18 as a therapeutic agent will present a useful dilemma, since delivering it might have a both favorable action (i.e., blocking neovascularization) and an unfavorable action (i.e., destroying the retinal pigment epithelium). In summary, inhibiting interleukin-18 might salvage the problem, as the biology is clarified and the new targets from interleukin-18 will likely emerge.

Age-related macular degeneration is likely to be confused with certain undiagnosed conditions of high cholesterol associated with heart disease, hypertension, hemochromatosis and sometimes with wrongly diagnosed conditions like diabetic cataracts, glaucoma and corneal dystrophies. There are many other symptomwise medical conditions which emulate age-related macular degeneration like choroidal neo-vascularization, retinal drusens and vitreous haemorrhage. These are the most common causes of visual loss among people over the age of 60.

Treatment for AMD has a limited effectiveness especially in advancing age with longevity of life. Early and advanced AMD are consistently more common in people who have specific genotypes (many function to mediate response to inflammation, oxidative stress, lipid metabolism, and angiogenesis). AMD is sometimes observed to be more common in people with a history of chronic diseases such as cardiovascular disease, diabetes, hypertension, obesity or diseases with elevated markers of inflammation.

Smoking has been the most consistently reported as risk factor for AMD, associated with many other unhealthy lifestyle habits, common in smokers. Physical activity has recently been studied in relation to AMD and was related to lower risk for AMD. Healthy diet patterns and physical activity have been related to lower blood levels of C-reactive protein, a marker of systemic inflammation. It has been more common amongst people with low levels of carotenoids in the diet, or with diets high in fat. Also, both physical activity and diet can contribute to better vitamin D status, which has been related to lower risk for AMD. Level of lutein and zeaxanthin is also correlated with intakes of many vitamins and minerals from foods as revealed by WHIOS in a study especially in women aged from 50-80 years

The National Eye Institute–sponsored 'Age-Related Eye Disease Study Research Group' recently reported that there is also an association between dietary antioxidants such as omega-3 fatty acids intake and progression of age-related macular degeneration. They concluded that dietary omega-3 intake is an easily modifiable factor that may influence the progression of retinal disease. Carrots, spinach, nuts, oranges, fish, whole grains in a healthy diet really are good for your eyes. Other supplements contain 500 mg of vitamin C, 400 IU of beta-carotene, 80 mg of zinc and 2 mg of copper. The supplements of lutein and zeaxanthin may also be helpful, although they are not part of the 'Age-Related Eye Disease Study (AREDS)' formula. Researchers suggest that these nutrients may reduce the risk of age-related macular degeneration. Although there is no known way to prevent macular degeneration yet leading a healthy lifestyle can reduce the risk of developing AMD.

Most common risk factors are increasing age, smoking, family history of AMD, obesity, white races people are much more likely to suffer AMD than other races, women appear to be at greater risk than men, people with light colored irises are at a higher risk than those with dark colored iris, exposure to sunlight , high cholesterol, hypertension, poor dietary intake of lutein and zeaxanthin and cataracts). These traits are likely to pass on to subsequent generations through genes.

Recently, a herbal treatment with **Yanbofang** has become very popular medication in China. Its composition is Rehmannia Glutinosa, Barbary Wolfberry Fruit, Plantago Asiatica, Indian Buead, Angelica Sinensis and White Paeony Root, etc. *(Ref: Beijing Baicao Jisheng Research Center of Macular Degeneration.)*

According to a study, out of 281 effected eyes, the clinical observation of treatment with natural herbs on 152 cases of age-related macular degeneration, from January 2009 to June' 2013, using "Yanbofang", 78 male cases, aged 50-75 years and 74 female cases, mean age 61.5 years with macular degeneration treated for 60 days, the visual acuity enhanced within 24 hours by ≥3 rows after treatment and the bleeding and leakage was stopped as noted in FFA. 160 eyes were clinically cured with a percentage of 56.93**%**; 91 eyes were improved with a percentage of 32.38**%**; 30 eyes were ineffective with a percentage of 10.67**%**; the total effective rate was 89.32. There were no side effects of medication and it was proven to be safe. *(Ref: The Chinese Journal of Modern Applied Pharmacy)*

Summary: In order to improve the quality of life, low-visual aids and therapy can help you use the vision more effectively. Modifying behaviors of diet, smoking, and physical activity and the subsequent prevalence of age-related macular degeneration (AMD) might reduce risk for early AMD as much as 3-fold and lowering the risk for advanced AMD in a person's lifetime.

Recommendations:

1. Exercise at a low intensity for 1-2 hours per day.
2. Take abundant plant foods (dark leafy green vegetables, fruits, and whole grains).
3. Take daily protein sources in moderation and variety (beans, nuts, fish, dairy, eggs, meat, and poultry).
4. Limits foods high in sugar, fat, alcohol, refined starches, and oils.
5. Modifying healthy lifestyles may lower AMD risk by lowering systemic inflammation, which is widely thought to contribute to AMD pathogenesis.
6. Lutein and zeaxanthin supplementation from foods can clearly increase macular pigment density, but the ability to increase macular pigment varies considerably among persons. Physical activity might contribute to greater macular pigment density by reducing inflammation and oxidative stress directly or by reducing obesity.
7. Obesity is related to lower macular pigment density and may increase oxidative stress.

REFERENCES

1. Smiddy WE. Relative cost of a line of vision in age-related macular degeneration. Ophthalmology. 2007;114(5):847-854. FULL TEXT | WEB OF SCIENCE | PUBMED
2. Schneider EL, Guralnik JM. The aging of America: impact on health care costs. JAMA. 1990;263(17):2335-2340. FREE FULL TEXT
3. Ding X, Patel M, Chan C-C. Molecular pathology of age-related macular degeneration. ProgRetin Eye Res. 2009;28(1):1-18. FULL TEXT | WEB OF SCIENCE | PUBMED
4. Hoffmann K, Zyriax B-C, Boeing H, Windler E. A dietary pattern derived to explain biomarker variation is strongly associated with the risk of coronary artery disease. Am J ClinNutr. 2004;80(3):633-640. FREE FULL TEXT
5. Sun C, Klein R, Wong TY. Age-related macular degeneration and risk of coronary heart disease and stroke: the Cardiovascular Health Study. Ophthalmology. 2009;116(10):1913-1919. FULL TEXT | WEB OF SCIENCE | PUBMED
6. Tan JS, Mitchell P, Smith W, Wang JJ. Cardiovascular risk factors and the long-term incidence of age-related macular degeneration: the Blue Mountains Eye Study. Ophthalmology. 2007;114(6):1143-1150. FULL TEXT | WEB OF SCIENCE | PUBMED
7. Feke GT. Cardiovascular disease, its risk factors and treatment, and age-related macular degeneration: Women's Health Initiative sight exam ancillary study. Am J Ophthalmol. 2007;144(3):482-483. WEB OF SCIENCE | PUBMED
8. Klein R, Peto T, Bird A, Vannewkirk MR. The epidemiology of age-related macular degeneration. Am J Ophthalmol. 2004;137(3):486-495. FULL TEXT | WEB OF SCIENCE | PUBMED
9. Doyle SL, Campbell M, Ozaki E, et al. NLRP3 has a protective role in age-related macular degeneration through the induction of IL-18 by drusen components. Nat Med 2012;18:791-798 CrossRef | Web of Science
10. Tarallo V, Hirano Y, Gelfand BD, et al. DICER1 loss and Alu RNA induce age-related macular degeneration via the NLRP3 inflammasome and MyD88. Cell 2012;149:847-859 CrossRef | Web of Science

Prof. M.Yasin Khan Durrani, FRCOphth (Lond)
Editor in Chief
E.mail: ophthalmologyupdate@gmail.com
0512222925, Ext:1255

ORIGINAL ARTICLE


Intezar Hussain

Efficacy & Safety of Clear Lens Extraction With Intraocular Lens Implantation in High Myopia

Intezar Hussain FCPS, FRCS[1], Shahid Mehmood FCPS[2]
Shabana Chaudhry FCPS, FRCS[3]


Shahid Mehmood

ABSTRACT

Purpose of the Study: To evaluate the visual results and operative postoperative complications in high myopic patients who underwent clear lens extraction by Phacoemulsification with foldable intraocular lens implantation.

Patients & Methods: We performed a retrospective, observational and descriptive study in 23 eyes of 12 patients between June 2006 and February 2014. We evaluated preoperative and postoperative best corrected visual acuity, operative, early and late postoperative complications. Apart from these, IOP, preoperative and postoperative refractive error, axial length and detailed fundus examination were also recorded. All the patients underwent Phacoemulsification with foldable IOL. The follow up range was 8 months to 8 years and 2 months with a mean of 4 years and 3 months.

Results: There were 2 male and 10 female patients. Age range was from 18 years to 34 years with a mean of 24.9 years. Mean preoperative spherical equivalent was -12.83 diopter and postoperatively it was -0.369 diopter. Pre-operative best corrected visual acuity was 6/9 or better in 10 eyes and postoperatively it improved in 16 eyes to 6/9 or better. No intra operative complications occurred. Postoperatively 6 eyes had IOP more than 21 mmHg, 11 eyes had posterior capsule opacification and 9 eyes underwent YAG capsulotomy. There were no post-operative retinal detachment.

Conclusion: The clear lens extraction in high myopia by phacoemulsification with foldable IOL implantation has good visual outcomes if alternative procedures are not feasible with no serious postoperative complications.

Key Words: Clear lens extraction, High myopia, Phacoemulsification.

INTRODUCTION

The clear lens extraction with or without intraocular lens implantation is the procedure that has been used to treat the high myopia for a long time.[1] The pioneer of clear lens extraction is considered Fukala.[2] This procedure is indicated for those high myopes who are intolerant to glasses and contact lenses and who are not suitable candidates for the Excimer laser due to less central corneal thickness and high refractive error. The clear lens extraction is becoming more acceptable procedure for these patients due to advancement in surgical techniques and lens technology.[3] The primary concern with this procedure is its association with an increased risk of retinal detachment and its incidence following clear lens extraction for high myopic patients has been reported up to 8%.[4] With the better surgical procedures and availability of modern multi focal and toric foldable intraocular lens and good preoperative peripheral retinal assessment for lattice degeneration and peripheral laser retinal barrage, the incidence of retinal detachment has decreased markedly and postoperatively results are much satisfactory than in the past.

This study was carried out to assess the postoperative best corrected visual acuity and the operative and postoperative complications in the clear lens extraction for high myopic patients who were not suitable for Excimer laser.

The clear lens extraction in high myopia by phacoemulsification with foldable IOL implantation has good visual outcomes if alternative procedures are not feasible with no serious postoperative complications.

PATIENTS & METHODS

This study was carried out at the Department of Ophthalmology Services Institute of Medical Sciences and Services Hospital Lahore, Kh. M. Safdar Medical College, Sialkot and Ittefaq Trust Hospital Lahore between June 2006 and September 2014. The purpose of the study was to assess the visual results and operative and postoperative complications in high myopic patients who underwent clear lens extraction by phacoemulsification with foldable intraocular lens implantation.. Each patient who was ***included*** in this study had stable myopia for at least one year and contact lens wearing intolerance. Each patient had high myopia in which excimer laser was inappropriate due to reduced central corneal thickness to correct the refractive error

[1]Associate Professor, Department of Ophthalmology, Kh. M. Safdar Medical College Sialkot. [2]Assistant Professor, Department of Ophthalmology, [3]Assistant Professor, Department of Ophthalmology, Lahore General Hospital and PGMI, Lahore

Correspondence: Dr. Intezar Hussain FCPS, FRCS Associate Professor, Department of Ophthalmology, Kh. M. Safdar Medical College Sialkot. E-Mail: intzardr@hotmail.com, Cell: 0321 4488124

Received: February 2015 Accepted: March 2015

completely. Patients under the age of 18 years were excluded. Also ***excluded*** were those with corneal diseases, cataract, glaucoma, Uveitis or a history of retinal detachment. A detailed history was taken and complete eye examination, including anterior and posterior segment, was performed. Special attention was given to the presence of any peripheral retinal lesions. The eyes deemed to be at risk with peripheral retinal degenerations or breaks were treated with 360 degree prophylactic argon laser photocoagulation at least one month prior to surgery. Previous refractive prescriptions were examined to confirm the stability.

A counselling session was performed with patients and their attendants regarding surgical outcomes and chances of residual myopia. An informed consent was obtained. Dioptric power of the posterior chamber IOL was calculated by SRK-T formula, target of surgery was emmetropia. All surgeries were performed by the same surgeon using peribulbar and/or topical anesthesia. After scrubbing the eye with 5% povidone iodine, sterile drapes were applied. A small clear corneal tunnel was created in the steeper meridian using slit knife 3.2 pointed bevel up. In all cases lens was aspirated with phacoemulsification using vacuum only. Thin layers of cortex were removed using Simco cannula. Foldable IOL was implanted into the capsular bag with injector. Subconjunctival injection of Dexamethasone 0.5 mg and Gentamycin 20 mg were given at the end of surgery and eye pad was applied. Eye pad was removed next day. A combination of Moxiflxacin and dexamethasone eye drops was advised. All patients were followed up on first postoperative day then at one week, one monthly, two months and six months thereafter. Best corrected visual acuity, Intraocular pressure, Slit lamp and fundus examination were done at every follow up visit. All the collected data was analyzed using SPSS version 10.0.

RESULTS

The number of patients included in our study were 12. Patient's age ranged from 18 to 34 years with a mean of 24.9 years (Graph 1). 2 patients (16.66 %) were male and 10 (83.44%) were female (Graph 2). All the patients underwent phacoemulsification and foldable IOL implantation.

On average, preoperative refraction was -12.834 sphere dioptres (Graph 3), whereas mean postoperative refraction was -0.369 sphere dioptre (Graph 4).Out of 12 patients 7 were using contact lenses, and of these 7 patients two were using only contact lenses and not the glasses while one patient was neither using glasses nor contact lenses. Preoperative axial length measurements were ranged from 24.97 mm to 29.85 mm with a mean of 27.88 mm (Graph 5). Preoperative refractive error (spherical equivalent) ranged from -8.00 dioptres to -18.50 dioptres (mean -12.83 dioptres), and postoperatively the mean refractive error was, with a range of zero to -1.50 dioptres. Best corrected visual acuity was 6/9 or better in 10 eyes preoperatively and postoperatively it improved in 16 eyes to 6/9 or better (Graph 6). Four eyes were amblyopic, and myopic macular degenerative changes were seen in five study eyes. Preoperatively, posterior vitreous detachment was documented as present in four eyes. Peripheral retinal degenerative changes were seen in 7 eyes before surgery, and these included 5 cases of lattice degeneration with retinal holes, two cases of pavingstone degeneration. Of these, prophylactic laser treatment was performed in five eyes in the past. No intraoperative complication was recorded. The interval from surgery to review for the purpose of this study ranged from 8 months to 8 years 2 months (mean 4 years and 3 months).

There were no postoperative retinal detachments. In 6 eyes IOP raised above 21 mmHg and it was noted upto 34 mmHg and was treated with topical antiglaucoma and returned to normal after the cessation of topical steroid. 11 eyes developed postoperatively posterior capsule opacification and YAG laser posterior capsulotomy had been performed in 9 eyes (Graph 7).

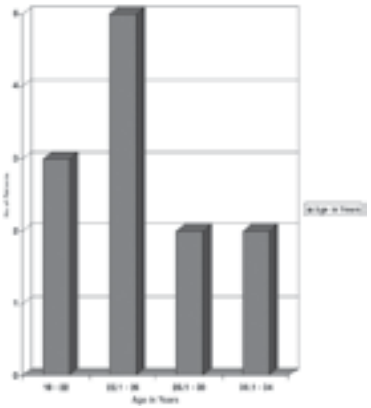

Graph-1: Age Distribution

Graph-2: Gender Distribution



Graph-3: Pre-Operative Spherical Equivalent



Graph-4: Post Op Spherical Equivalent

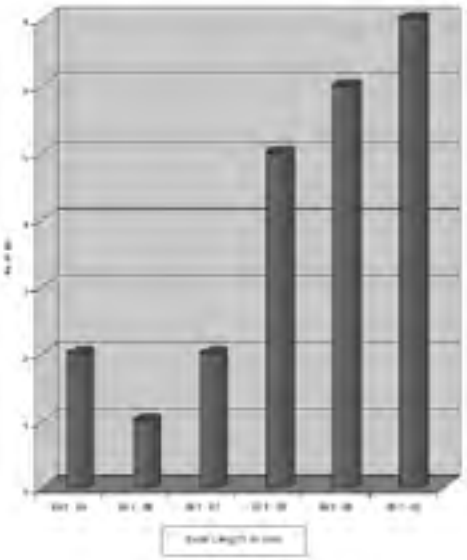

Graph-5: Distribution of Axial Length



Graph-6: Comparison of Pre-Operative & Post- Operative BCVA

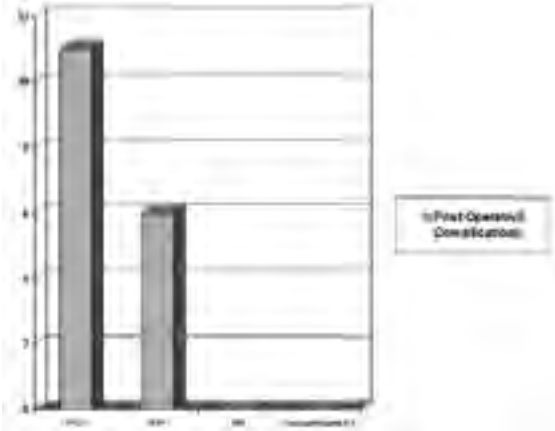

Graph-7: Post- Operative Complication

DISCUSSION

High refractive errors pose a problem to patients with regards to quality of vision and life. Surgical correction of high ametropia is a controversial issue.[5-8] Refractive lens exchange is an effective form of refractive surgery, which may be considered in patients with high myopia in whom Excimer laser is inappropriate but has some significant complications limiting its wide spread acceptability, such as an increased risk of retinal detachment, posterior capsule opacification and loss of accommodation in young patients.

In our study, preoperative BCVA 6/9 or better was in 10 eyes and postoperatively it improved in 16 eyes to 6/9 or better. In 9 eyes BCVA was unchanged pre and postoperatively while in 14 eyes it improved 1-2 Snellen lines postoperatively. This was probably because of elimination of aberrations introduced by high spectacle correction by the IOL. Gris et al[9] reported BCVA

of 6/9 or better increased from 64.9% preoperatively to 88.5% postoperatively in their patients. In the study by Vega et al[10] final best spectacle corrected visual acuity (BSCVA) was better than preoperative best spectacle corrected visual acuity in 83.68%, equal in 12.63% and worse in 3.68% cases. At six months postoperatively, refraction was stable, the mean spherical correction being -1.25D with a range of -0.50 to -2.0. Guell et al[11] also confirm the same results of clear lens extraction. Their study mentions the improvement in BSCVA and mean postoperative spherical equivalent of -1.05D. In the study by Iqbal et al Preoperative BSCVA was 6/12 or better in 50% of the eyes which increased to 70% postoperatively.[12]

Minimizing risk is critical to the success of refractive lens exchange and refractive surgery in general, since these are entirely elective procedures. In our study 6 eyes had postoperatively increase in IOP above 21 mmHg. In these eyes IOP ranged from 22 to 34 mmHg and it became in normal range with discontinuation of topical steroid and temporary use of topical antiglaucoma therapy and it proved that IOP elevation was due to steroid responder in very high myopes.11 eyes had postoperative posterior capsule opacification and in 9 eyes YAG laser posterior capsulotomy was performed in this study and none of the patients developed retinal detachment in our series. We attributed this to careful preoperative screening using indirect ophthalmoscope with indentation where necessary, avoiding doubtful cases, very careful polishing of the posterior capsule and the anterior leaf of the capsule to remove epithelial cells, our choice of IOL with an edge design believed to retard the occurrence of posterior capsule opacification, However the benefit of prophylactic treatment of any type of retinal lesion is not established. Retinal tears and subsequent detachment can occur in previously normal areas of retina or at the edge of photocoagulation scars. The incidence of retinal detachment after clear lens extraction reported in other studies[13-15] is variable, ranging from 0% to 8%. It has been proposed that the causes of this variability are different patient characteristics and study designs. These and other previously reported studies have found associations between the risk of retinal detachment and one or more of several factors, including younger age, axial length, history of retinal detachment or surgery in the contralateral eye or lesions predisposing to retinal detachment, surgical technique and integrity of the posterior capsule, use of Nd: YAG capsulotomy, and longer follow-up time after surgery.

In the study by Stonecipher. Retinal detachment occurred postoperatively in one patient (0.3%) and cystoid macular oedema (CME) in two (0.6%).Sanders suggests that the 1,372 subjects of 14 peer-reviewed articles who underwent refractive lens exchange by Phacoemulsification with posterior chamber IOL implantation comprise a more pertinent comparison group. Retinal detachments in this group numbered,[14] for a cumulative rate of 1%. A still more recent publication by Fernandez-Vega reports a retrospective case series of 190 eyes of 107 patients with a minimum axial length of 26.00 mm that underwent refractive lens exchange with posterior chamber IOL implantation and had a mean follow-up of 4.78 years (3.1–8.03 years)[16] The reported YAG capsulotomy rate was 77.89% (148 eyes). Retinal detachment developed in four eyes with a mean axial length of 30.44 mm (29.60–32.30 mm), all of which had undergone YAG capsulotomy. The overall incidence of retinal detachment was 2.1%.

This series suggests that clear lens extraction by Phacoemulsification with foldable IOL can be offered as a relatively safe option for patients who are not good candidates for less invasive refractive surgical procedures. Keys to success include careful preoperative screening and treatment for retinal pathology, the use of modern phacoemulsification equipment and techniques with vigilant follow-up.

CONCLUSION

Clear lens extraction by phacoemulsification with foldable posterior chamber IOL implantation is a suitable alternative option for those high myopes who are not suitable for Excimer laser, has good visual outcomes with improvement in best-corrected visual acuity and no serious postoperative complications like retinal detachment.

REFRENCES

1. El-Sahn F. Mossalam E. Anterior chamber phakic lOLs for the correction of high myopia. Bull Ophthalmol soc Egypt 2000;93:127-29.
2. Schmidt D, Grzybowski A,Vincenz Fukala (1847–1911) and the Early History of Clear-lens Surgery in High Myopia.Journal of Refractive Surgery 2011: 27: 636-637
3. Packer M, Fine IH,Hoffman RS. Refractive lens exchange with the Array multifocal lens. J Cataract Refract Surg 2002; 28:421-424
4. Colin J, Robinet A, Cochener B. Retinal detachment after clear lens extraction for high myopia: seven-year follow-up. Ophthalmology. 1999; 106:2281-2284
5. Baikoff G, Joly P. Comparison of minus power anterior chamber intraocular lenses and myopic epikeratoplasty in phakic eyes. *Refract Corneal Surg*. 1990; 6:252–260
6. Colin J, Mimouni F, Robinet A, Conrad H, Mader P. The surgical treatment of high myopia: Comparison of epikeratoplasty, keratomileusis and minus power anterior chamber lenses. *Refract Corneal Surg*.1990; 6:245–251.
7. Fechner PU, Strobel J, Wichmann W. Correction of myopia by implantation of a concave Worst-iris claw lens into phakic eyes. *Refract Corneal Surg*. 1991; 7:286–298.
8. Garrana RM, Azar DT. Phakic intraocular lenses for correction of high myopia. *Int Ophthalmol Clin*. 1999; 39:45–57.

9. Gris O, Guell JL, Manero F, Muller A. Clear lens extraction to correct high myopia. J Cataract Refract Surg. 1996; 22: 686-9.
10. Vega LF, Alfonso JF, Villacampa T. Clear lens extraction for the correction of high myopia. American Academy of Ophthalmology. 2003; 110: 2349-54.
11. Guell JL, Andres F, Rodriguez A, et al. Phacoemulsification of the crystalline lens and implantation of an intraocular lens for correction of moderate and high myopia: Four year follow-up. J Cataract Refract Surg. 2003; 29: 34-8.
12. Iqbal S,Khan M.Visual Outcome of Clear Lens Extraction (Phacorefractive) in Myopia Above -12.0 Dioptres. *Pak J Ophthalmol. 2008; 24:59-62.*
13. Colin J, Robinet A. Clear lensectomy and implantation of low-power posterior chamber intraocular lens for the correction of high myopia. Ophthalmology. 1994; 101:107–112.
14. Barraquer C, Cavelier C, Mejia LF. Incidence of retinal detachment following clear-lens extraction in myopic patients. Retrospective analysis. Arch Ophthalmol. 1994; 112:336–339.
15. Fritch CD. Risk of retinal detachment in myopic eyes after intraocular lens implantation: A 7 year study. *J Cataract Refract Surg*. 1998;24:1357–1360.
16. Fernandez-Vega L, Alfonso JF, Villacampa T.Clear lens extraction for the correction of high myopia. Ophthalmology 2003; 110:2349–2354

Javed Rasul

ORIGINAL ARTICLE

Common Ocular Problems in Children Presented in a Private Setup during one year

Javed Rasul FCPS[1], Nazullah Khan FCPS[2]
Muhammad Kashif Kamran MBBS[3], Imran Ahmad FCPS[4]

ABSTRACT

Objective: To highlight the commonly prevalent ocular problems in children of Bannu during one year period in a private clinic.

Materials and Method: It was a descriptive cross-sectional study. Incidental non- probability technique of sampling was adopted. Sampling was done from January 2013 till July 2014. Patients were screened in private clinic setup. Proper record was maintained in a separate register of children up to 15 years of age. They were recorded according to their specific condition in a separate section in that register.

Results: A total 898 patients were seen, out of which 596 (66.3%) were males and 302 (33.6%) were females. Age ranges from 10 days to 12 years with mean of 4.2 years.

Nasolacrimal duct obstruction was the most frequent condition (28.2%) followed by vernal keratoconjunctivitis (27.8%), squint in 18.9%, refractive error in 11.58%, congenital cataract 9.3%, nystagmus in 1.7%, retinitis pigmentosa in 1% and ptosis in 1.1%.

Conclusion: In this study, boys were found to be more often affected with eye diseases and the presentation to a health facility was most often late. Most pediatric eye diseases need special care and early intervention; therefore it is crucial that good provincial and district pediatric ophthalmology centers should be set up.

INTRODUCTION

There are about 1.5 million blind children in the world and more than one million children in Asia alone,[1,2] half of which are preventable blindness.[3] Children in the school-going age group (6-15 years) represent 25% of the population in the developing countries.[4] Cataract is the leading cause of preventable blindness.[5] Globally 190,000 children are blind from cataract alone.[4] Strabismus or squint is less common in Asians as compared to Caucasians.[6] Pediatrics age group is major part of our population. Diseases in this age group especially when it is of ophthalmic in nature are always difficult to diagnose because they are unnoticed by them and they always use their uninvolved eye, until and unless there is white pupillary reflex, strabismus or bilateral involvement etc. Diseases like cataract, strabismus, congenital nasolacrimal duct obstruction, refractive error and allergic eye diseases are common ophthalmic conditions in pediatrics age group.

Children adjust to the poor eyesight by sitting near to the blackboard, holding the books closer to their eyes, squeezing the eyes and even avoiding work requiring visual concentration. This warrants early detection and treatment to prevent permanent disability.[7] Our aim is to highlight the common ocular problems in children of Bannu presented to private clinic setup, so that we may be able to make proper management for them and not waste our energy on focusing on less prevalent conditions.

[1]Assistant Professor of Ophthalmology, Pak-International Medical College Peshawar. [2]Senior Registrar, Department of Ophthalmology, Hayatabad Medical Complex, Peshawar. [3]Postgraduate Trainee,[4] Medical Officer, Pakistan Institute of Community Ophthalmology, Hayatabad Medical Complex, Peshawar.

Correspondence: Dr. Imran Ahmad FCPS, Medical Officer, Pakistan Institute of Community Ophthalmology (PICO) Hayatabad Medical Complex Peshawar, Mob No. 0333-9255244, E-mail: doctorimranahmad@gmail.com, House No. 40, Street No 2, Sector H-1, Phase 2, Hayatabad, Peshawar. Cell: 0333-9300543

Received: March 2015 Accepted: April 2015

Boys are found to be more affected with ocular diseases and often late presentation. Most pediatric eye diseases need special care and early intervention.

MATERIALS AND METHODS

Study design: *It was a descriptive cross-sectional study.*

Sampling Technique*: Accidental non- probability technique of sampling was adopted.*

Study Duration*: Sampling was done from January 2013 till July 2014.*

Data collection*: Patients were screened in private clinic setup. Proper record was maintained in a separate register of children up to 15 years of age. They were recorded according to their specific condition in a separate section in that register.*

RESULTS

A total of 898 patients were seen, out of which 596 (66.3%) were males and 302 (33.6%) were females. Age ranges from 10 days to 12 years with mean of 4.2 years. In order of frequency the most common diseases that were found in children were nasolacrimal duct obstruction, allergic conjunctivitis, squint, refractive

error, congenital cataract, nystigmus, retinitis pigmentosa and ptosis respectively. The three most common conditions were nasolacrimal duct obstruction, allergic conjunctivitis and squint as shown in graph No.1.

In our study the most frequent ocular pathology was nasolacrimal duct obstruction with predominance in 62.2% males and 37.85% females (Table No.1). Most of the cases 70.86% were below 1 year of age in both genders and 150 (59%) were unilateral nasolacrimal duct obstruction (table No.2). Ratio of male to female was 1.6.

Second most common condition was allergic conjunctivitis which was noted in 250 patients (27.8%) with predominance in males 188 (75.2%), whereas 62 (24.8%) were females (Table No.1). Most common age group was from 2-7 years (80%) and the rest from 8-12 years (Table No.2).

Squint was the third common ocular condition, noted in 170 (18.9%) patients with 104 males (61%) and 66 (29%) females with most frequent age group of 2-7 year. Congenital cataract though very common, but few presented to our clinic. Total patients were 84 (9.3%) with 56 (66.65%) male and 28 (33.3%) females. Refractive errors were noted in 104 (11.58%) in which 66 (63.5%) were males and 38 (36.5%) were females. Male to female ratio was 1.7. 31(30%) were myopes and 63 (60%) were hypermetropes. Nystagmus, Retinitis Pigmentosa and Ptosis were least common diseases with frequency of 16 (1.7%), 10 (1.1%) and 10 (1.1%) respectively.

Table:1 Gender wise frequency distribution in different diseases

Diseases	Male	Female	Total
Vernal kerato-conjunctivitis	188 (20.9%)	62 (6.9%)	250 (27.8%)
Nasolacrimal-duct obstruction	158 (17.6%)	96 (10.69%)	254 (28.2%)
Squint	104 (11 .58%)	66 (7.3%)	170 (18.9%)
Congenital cataract	56 (6.2%)	28 (3.1%)	84 (9.3%)
Retinitis pigmentosa	8 (0.8%)	2 (0.2%)	10 (1.1%)
Nystagmus	8 (0.8%)	8 (0.8%)	16 (1.7%)
Refractive error	66 (7.3%)	38 (4.2%)	104 (11.58%)
Ptosis	8 (0.8%)	2 (0.2%)	10 (1.1%)
Total	596 (66.3%)	302 (33.6%)	898 (100%)

Table:2 Age wise frequency distribution in different diseases

Diseases	<1 years	2-7 years	8-12 years
Vernal-kerato conjunctivitis	0	200 (22.27%)	50 (5.5%)
Nasolacrimal-duct obstruction	180 (20%)	74 (8.2%)	0
Squint	30 (3.3%)	80 (8.9%)	60 (6.6%)
Congenital cataract	60 (6.6%)	20 (2.2%)	4 (0.4%)
Retinitis pigmentosa	4 (0.4%)	6 (0.6%)	0
Nystagmus	10 (1.1%)	5 (0.5%)	1 (0.1%)
Refractive error	35 (3.8%)	50 (5.5%)	19 (2.1%)
Ptosis	1 (0.1%)	5 (0.5%)	4 (0.4%)

Figure: 1 Most common condition in our study



DISCUSSION

The evidence seen in these results are self-explanatory. A great deal needs to be done in the field of pediatric ophthalmology, but in order to proceed; the current situation in this field needs to be identified. Primarily, the commonly seen eye diseases in children should be determined. Boys were more affected in all the diseases encountered. This is probably due to the fact that boys are greatly valued in our culture and are more often brought to the hospital. This unfortunate fact can be tackled with the help of counseling.

In a population based cross-sectional survey done in Karachi from July to August 2003, a total number of 5110 children examined. It was found that errors of refraction (2%) made up the majority followed by conjunctivitis (1.2%) and squint (0.6%).[8] while in our study the most common conditions were nasolacrimal duct obstruction (28.2%), vernal-keratoconjunctivitis (27.8%) and squint (18.9%). Worldwide, the main cause

of visual impairment and blindness among children are genetic conditions[9], even though it is difficult to generalize the study to this extent as there is no uniform survey and the results differ in different parts of the world. But in our setup, along with genetic diseases, there is the added burden of preventable eye diseases as well.

Epiphora due to nasolacrimal duct blockage was the most frequent presentation and was unilateral in 59% of patients. In children, the duct may not be completely developed at birth. Parents were initially counseled and given instructions for massage of the lacrimal sac area. Persistent cases after the age of one year were dealt with probing and syringing.

This congenital tear duct blockage clears spontaneously by 6 months of age.[10] If it does not clear on its own, the outcome is still likely to be good with treatment. According to present literature, the majority (61%) of lacrimal drainage obstruction in children is developmental; others are caused by infections (24%), trauma (12%), and dysfunction (3%). The condition is bilateral in almost one third of the cases.[10]

According to Georgiou et.al Asians are significantly more likely to present with Keratoconus and these are mostly Northern Pakistani origin.[11] VKC is the preventable blinding condition that can cause keratoconus, keratoglobus, corneal ulcer and opacification of cornea. These are the devastating conditions and can be easily prevented by educating the parents regarding VKC and its complication and its control through medications.[12] Squint affected boys more than girls and presentation was more in the older age group. Most parents are able to recognize squint, but due to financial restraints, were not able to make the trip to a far away tertiary care hospital. With proper spread of information and counseling, these children do not have to live with the stigma that often accompanies squint.

Errors of refractions are responsible for one quarter of blindness in children and half of low vision.[13] Hypermetropia was seen in 11.58% of children in our study which is consistent with the majority of the studies done, as hypermetropia is more common during childhood.[14] At the clinic, it was common to see children up to the age of four with hypermetropia of three or four diopters. Children who presented with hypermetropia of more than four diopters, glasses were prescribed.

Cataract was in 9.3% of patients. Cataract surgery is one of the most cost effective public health interventions[15], yet many children all over the world are blind simply from cataract. In our setup, there are many reasons for this, as many of the children seen in the clinic belonged to lower socioeconomic status and many came from far away areas. A large number of parents believed that congenital blindness, regardless of the cause is untreatable and therefore never seek help. Fear of the parents plays a crucial role for not bringing children to the hospital. Fear mainly revolves around surgery in such a young child and fear of the child dying during the operation.[15] Children were brought rather late to the clinic at the age of three or four years and was difficult to diagnose whether the cataract was congenital or acquired. In some children it was obvious as they already had developed nystagmus. There was no means of determining the causative factors but according to a study carried out in western India, 4.6% cases of congenital cataract is due to rubella.[16] Rubella is a common cause of congenital cataracts in this region and accounts for more than 25% of all new cases of congenital cataract in Western India.[16]

A very small percentage of patients which ranges from 1.1-1.7% were that of nystagmus, retinitis pigmentosa and ptosis. Nystagmus is a comorbid condition often presented in late stage of other diseases which have made a child potentially blind, like cataract, refractive errors, retinitis pigmentosa etc. Retinitis pigmentosa is a genetic disorder and carry worse prognosis, but the patients can be counseled for low vision aids which are sophisticated, expensive and its use needs proper motivation which is very difficult to handle. Ptosis is a potentially blinding condition as it can cause amblyopia if unilateral and can be cured with surgical intervention if done in time. Involvement of parents plays a positive role in the well being of a child. Good visual outcome does not only depend on competency and good surgical skills because in children frequent regular post-op follow up is highly essential.[17,18]

CONCLUSION

In our study, boys were found to be more affected with ocular diseases and presentation to the health facility was often late. Most pediatric eye diseases need special care and early intervention; therefore it is crucial that good provincial and district pediatric ophthalmology centers need to be set up.

REFERENCES:

1. Oduntan AO. Prevalence and causes of low vision and blindness worldwide. S Afr Optom 2005; 64: 44-54.
2. Kaid Johar SR, Savalia NK, Vasavada AR. Epidemiology based etiological study of pediatric cataracts in Western India. Indian J Medical Sciences Trust.2004; 58: 115-1213.
3. Clare G, Haroon A. Blindness in children Editorial, BMJ. 2003; 327: 760-1.
4. Naik R, Gandhi J, Shah N, Prevalence of Ocular Morbidity among School Going Children (6-15 years). Sch. J. App. Med. Sci., 2013; 1(6):848-851

5. Hugh RT, Jill EK. World blindness: a 21st century perspective, Br J Ophthalmol. 2001; 85: 261-6.
6. Teoh CH,Yow CS. Prevalence of squint and visual defects in Malaysian primary one school children. Med. J. Malaysia 1982; 37(4): 336-37
7. Danish Assistance to the National Programme for Control of Blindness. New Delhi, India: Vision screening in school children. Training module 1.
8. Sheikh SP, Aziz TM. Pattern of Eye diseases in children of 5-15 years at Bazzertaline Area in Karachi, JCPS Pakistan. 2005; 15: 145-8.
9. Oduntan AO. Prevalence and causes of low vision and blindness worldwide. S Afr Optom 2005; 64: 44-54.
10. Gilbert C, Foster A. Childhood blindness in the context of VISION 2020 - The Right to Sight. Bull World Health Organ. 2001; 79.
11. Georgiou T, Funnell CL, Cassels-Brown A, O'Conor R. Influence of ethnic origin on the incidence of keratoconus and associated atopic disease in Asians and white patients. Eye. 2004; 18: 379–83.
12. Oraszewska-Matuszewska B, Pieczara E, Sameochowiec-Donocik E, Filipek E. Vernal keratoconjunctivitis in children. Klinika Oczna 2005; 107(1-3): 86-9.
13. Hugh RT, Jill EK. World blindness: a 21st century perspective. Br J Ophthalmol. 2001; 85: 261-6.
14. Gilbert C, Awan H. Blindness in children (Editorial). BMJ. 2003; 327: 760-61.
15. Muhit MA. Childhood Cataract: Home to Hospital. Community Eye Health. 2004; 17: 19-22.
16. Kaid Johar SR, Savalia NK, Vasavada AR. Epidemiology based etiological study of pediatric cataracts in Western India. Indian J Medical Sciences Trust. 2004; 58: 115-1213.
17. Clare G, Haroon A. Blindness in children Editorial. BMJ. 2003; 327: 760-1 Shamanna BR. Childhood Cataract: Magnitude, Management, Economics and Impact (Editorial). Com
18. Shamanna BR. Childhood Cataract: Magnitude, Management, Economics and Impact (Editorial). Community Eye Health Journal. 2004; 17: 17-8.

Hand–foot Syndrome after Capecitabine administration in stage IV breast cancer

Loss of Fingerprints

A 65-year-old woman with stage IV breast cancer. She had undergone treatment for triple-negative breast cancer (a tumor characterized by the lack of expression of estrogen receptor, progesterone receptor, and human epidermal growth factor receptor type 2 with capecitabine and bevacizumab. During the first cycle, grade 1 of the hand–foot syndrome (palmar–plantar erythrodysesthesia) developed and was successfully treated with topical agents. The hand–foot syndrome is a side effect of certain chemotherapeutic agents that is characterized by redness, swelling, and pain on the palms of the hands or soles of the feet. After the third cycle of chemotherapy, the symptoms worsened, with limitation of self-care activities. Positron-emission tomography–computed tomography revealed a 50% reduction in metabolic activity of the lung metastases; capecitabine administration was delayed and subsequently continued at a reduced dose. The patient had no further acute toxic effects, but the fingerprints of her thumb and fingers were erased.

D.D.,Vitamin E deficiency, Chemotherapy
Scleroderma, Chronic inflammatory demyelinating polyneuropathy, Mercury toxicity

Curtsey: Yanin Chavarri-Guerra, M.D. & Enrique Soto-Perez-de-Celis, M.D.
Instituto Nacional de Ciencias Medicas y Nutricion, Mexico City, Mexico

Bilal Khan

ORIGINAL ARTICLE

Role of Injectable Methyl Prednisolone in Patients with Optic Neuritis

(A Two Years Prospective Study)

Bilal Khan FCPS[1], Asif Iqbal FCPS[2], Muhammad Idris FCPS[3]
Mehfooz Hussain FRCS[4], Junaid Sethi FCPS, FRCS[5], Mir Ali Shah FCPS[6]

ABSTRACT

Objective: To know about the role of injectable methyl prednisolone in patients with optic neuritis.

Methodology: This cross sectional study was conducted in Ophthalmology Department of Lady Reading Hospital Peshawar from January 2012 to January 2014 with total 2 year duration. After taking consent from the ethical research committee data collection was started in those patients who were admitted with optic neuritis in the mentioned duration and treated with injectable methylprednisolone with sudden loss of vision, unilaterally with periocular pain specially with ocular movements. All the data was analyzed by SPSS version 20 and results were represented by graphs and charts.

Results: Total 31 patients were included in this study in which 20(64.51%) females while remaining 11(35.49 %) were males. All the patients were in the age range of 20 to 50 years having mean age of 30 ± 5 SD. 23 (74.19 %) patients had visual acuity less than 6/36 while 8(25.81 %) had visual acuity greater than 6/18. Out of these 20 (64.51 %) showed 2 lines visual acuity improvement all those presented within the 2 weeks of visual loss while remaining 11 (35.49%) no visual improvement which presented after 2 weeks of visual loss.

Conclusion: Optic neuritis is common in young to middle age females patients presenting within the 2 weeks of symptoms when treated with injectable methyl prednisolone show good visual improvement though there are less chances of recovery.

Key words: Injectable methyl prednisolone, idiopathic Optic neuritis.

INTRODUCTION

Optic neuritis is an inflammatory condition affecting the optic nerve, usually affecting young adults, especially females, between 18 and 45 years of age. Although it has been reported from almost all parts of the world, regions with the highest incidence include northern Europe, southern Australia and middle part of North America. Its overall incidence is 1-5 cases per 100,000 patents / year. Most common cause is idiopathic in nature having frequency of 49.1- 83.9% followed by demyelinating lesions of which multiple sclerosis (MS) is the most common cause which causes 6.5- 25.5 %. Other less common etiologies include infectious and para-infectious causes, inflammatory and para-vaccination immunological responses.[1,2,3,4,5,6,7] Its origin is inflammatory and the pathophysiology of this condition includes a peripheral activation of T-cells that may cross the blood brain barrier causing a delayed type IV hypersensitivity reaction. This process also leads to destruction of myelin with also the involvement of the axon, something that can be confirmed by means of an optical coherence tomography (OCT) examination. All this process has a negative impact on visual acuity (VA) .[8,9]

The clinical presentation of this pathology usually includes sudden loss of visual acuity (VA) which may be unilateral or bilateral, visual field restriction, pain with eye movements, dyschromatopsia, a relative afferent pupillary defect and optic disk swelling[10]. The diagnosis of optic neuritis is a clinical one, made in a patient of appropriate age with the clinical features mentioned above. Although no investigations are necessary for confirming the diagnosis, investigations are needed to assess the risk of developing MS and to rule out other disorders. In atypical cases an additional workup to identify the etiology should be considered just like baseline chest x-ray for tuberculosis, serology for syphilis, bartonella and toxoplasmosis, Mantoux test, blood culture, cerebrospinal fluid (CSF) examination and blood tests should be done to rule out infective and inflammatory cases. The choice of radiological investigations depends upon the clinical picture, for example, MRI of the optic nerves in suspected cases of compressive optic neuropathy, computerized tomography (CT) of the orbits in bony orbital lesions, orbital ultrasound for posterior scleritis, optical coherence tomography, fluorescein angiography, and electro-retinography for retinal diseases. Specialized tests, e.g., toxin screens and serum B12 for toxic optic neuropathy, markers for autoimmune diseases, antibody to aquaporin-4 and MRI spine in NMO, genetic analysis for mitochondrial mutation in cases of Leber's hereditary optic neuropa-

[1]Resident, Vitreo-Retina, Lady Reading Hospital Peshawar. [2,3]Medical Officers,Ophthalmology, PGMI, LRH, Peshawar. [a]Assistant Professor, Ophthalmology. LRH, Peshawar. [5]Senior Registrar, Ophthalmology, LRH, Peshawar. [6]Associate Professor, LRH, Peshawar

Correspondence: Dr. Bilal Khan, Resident Vitreo retina, Ophthalmology Department Lady Reading Hospital, Peshawar. Cell: 0300-5981806, Email: drbilalokz@gmail.com

Received: March 2015 Accepted: May 2015

thy are required in suspected conditions.[5]

Although the treatment depends upon the etiology of optic neuritis but for acute attack of idiopathic optic neuritis different forms of treatment options are available in the form of intra venous plus oral corticosteroids, immune-modulators like interferons, glatiramer acetate and therapeutic plasma exchange but the first line of treatment is provided in the form of steroids . Now a day's new developments aimed at designing better treatments for patients who fail to recover, focusing on recent research elucidating mechanisms of damage and recovery in optic neuritis . Future therapeutic directions may include enhancing repair processes, such as re-myelination or adaptive neuro-plasticity for optic neuritis due to multiple sclerosis, or alternative methods of immune-modulation. Pilot studies investigating the safety and proof of principle of stem cell treatment are currently underway.[11,12]

Rationale of the current study is to know about role of injectable methyl prednisolone in idiopathic optic neuritis . this study is important for this reason that in our local set up very little workup has been done on this topic further more internationally a lot of work has been done on optic neuritis due to multiple sclerosis so it will create the local statistics of burden of idiopathic variety and effectiveness of injectable methyl prednisolone for visual recovery based on duration of treatment. Furthermore it will create a base for future researchers.

Optic neuritis is common in young to middle aged females patients. When treated with injectable methyl prednisolone there are less chances of recovery. It leads to only partial visual improvement only in selected cases but the complete visual recovery seems difficult.

METHODOLOGY

This cross sectional study was conducted in Ophthalmology Department of Lady Reading Hospital, Peshawar from January 2012 to January 2014 with total 2 year duration. After taking consent from the ethical research committee, data collection was started in those patients who were admitted with optic neuritis with sudden loss of vision unilaterally with periocular pain specially with ocular movements in the mentioned duration and treated with injectable methyl prednisolone. All the data was analyzed by SPSS version 20 and results were represented by graphs and charts.

All the patients had undergone through complete history, detailed clinical and visual acuity, pupillary reflex for presence or absence of RAPD, color desaturation, light brightness, contrast sensitivity, visual field and fundoscopy to see the conditions of retina and disc. Then patients were put on injectable prednisolone having dose of 1 gram for three days and after 3rd day again visual acuity was checked then followed by oral predisolone for 11 days and then tapered over three days. The ethical approval was taken from the hospital ethical committee, "Postgraduate Medical Institute, Institutional Research and Ethics Board". Role of injectable prednisolone in patients of optic neuritis was determined.

RESULTS

Total 31 patients were included in this study in which males were predominant having 20(64.51%), females while remaining 11(35.49 %) were males Fig no 1. All the patients were in the age group of 20 to 50 years having mean age of 30 ± 5 SD. When all patients, pre injection vision was analyzed it was found that 23 (74.19 %) patients had visual acuity less than 6/36 while 8(25.81 %) had visual acuity greater than 6/18, Fig no 2. When the patients were admitted for treatment of acute attack of optic neuritis, intra venous methyl prednisolone was used for it consecutively for 3 days we found that those patients who presented within 2 weeks of onset of symptoms showed 2 lines improvement in visual acuity in 20 (64.71%) while those who presented after 2 weeks of starting the symptoms of development did not show any improvement in visual acuity and the total number of patients in that category were 11(35.29%) Fig no 3.

Fig No 1: Gender wise distribution of patients N=31

Fig No 2: Dstribution of patients based on severity of visual loss N=31

Visual acuity	Number of patients	Percentage
CF 3m-6/36	23	74.19 %
Better than 6/18	8	25.81 %

Fig no 3. Visual outcome after injectable methyl prednisolone used for 3 days N=31



DISCUSSION

We conducted a cross sectional study on 31 patients of idiopathic optic neuritis in Ophthalmology Department Lady Reading Hospital Peshawar while given the treatment of injectable methyle prednisilon to them for consecutive 3 days and on 3rd day we checked the patients for any improvement in visual acuity in hospital while still admitted we found that all patients were in the age group of 20 to 70 years having mean age of 33 ± 5 SD. Males were effected more than the females having total cases of 20 (64.51 %) while males were 11 (35.49 %) with males to females ratio 1.81;1. Naeem A et al[13] in his three retrospective study on optic neuritis has documented that females 18 (64.3%) are most commonly effected as compared to males 10 (35.7%) with female/male having 1.80;1 from optic neuritis which resembles our study. Similarly in their study patients were in age range of 20-45 years with mean age of 31.25 years which also resembles our resembles our study. Other international studies have also documented females dominancy in optic neuritis as compared to males.[14,15]

In our study 21 (68 %) had visual acuity in range of counting fingers to 6/36 while remaining 10(32%) patients were had visual acuity better than 6/18 at the initial presentation. Naseem et al [13] has also showed in their study that the patients in their initial presentation with optic neuritis having visual acuity ranging from counting fingers to 6/36 had frequency 23 (64 %) in total 28 patients which is in accordance to our results. When all the patients were treated with injectable methyl prednisolone having dose of 1gm/day for three days then again on fourth day in the ophthalmology ward visual acuity was again rechecked for any improvement we found that visual acuity was improved by two lines in 20 (64.71%) patients and these patients presented within 2 weeks and remaining 11 (35.29 %) patients showed no improvement in visual acuity because of late presentation more than 2 weeks of period. In ONTT study the total recovery in visual acuity was 74% in the group of patients receiving injectable methyl prednisolone followed by oral methyl prednisolone. The main reason in difference of results is that in ONTT study the follow up period was much more greater than our study which was 10 years and total number of patients in their study was much greater than our series.

Beck RW[17] has showed in his study that methyl prednisolone leads to the visual improvement in optic neuritis patients . Sellebjerg F et al [18] has mentioned in his study that at 1, 3, and 8 weeks of oral prednisolone 31%, 54%, and 65% patients showed partial visual improvement. Durelli L et al [19] documented in their study that high dose methyleprednisolone in patients of multiple sclerosis suffering from optic neuritis shows partial visual improvement in 3 days and 6 days which is also shown by our study that intravenous methyleprednisolone can partially improve visual acuity for few lines when checked at 3rd day of treatment. Brusaferri F et al[20] in their study of 716 patients of optic neuritis which were treated by methyleprednisolone and followed for 30 days, has documented partial visual improvement. Filippini G et al[21] in 2000 has published their 6 trial work up in the form of study they have documented that methyleprednisolone has good effect on visual acuity when it was checked on 5th week of the treatment. In all these studies it has been documented that methyl prednisolone is beneficial in short term with partial visual recovery when given to the patients of optic neuritis but complete visual recovery is difficult.

CONCLUSION

Optic neuritis is common in young to middle age females patients presenting within the 2 weeks of symptoms when treated with injectable methyl prednisolone show visual improvement with less chances of recovery. Methyl prednisolone leads to only partial visual improvement only in selected cases and complete visual recovery is extremely difficult.

REFERENCES

1. Rosati G. The prevalence of multiple sclerosis in the world: an update. Neurol Sci. 2001;22:117–39.
2. Pugliatti M, Sotgiu S, Rosati G. The worldwide prevalence of multiple sclerosis. Clin Neurol Neurosurg. 2002;104:182–91.
3. Wang JC, Tow S, Aung T, Lim SA, Cullen JF. The presentation, aetiology, management and outcome of optic neuritis in an Asian population. Clin Experiment Ophthalmol. 2001 Oct;29(5):312-5.
4. Lim SA, Goh KY, Tow S, Fu E, Wong TY, Seah A, et al. Optic neuritis in Singapore. Singapore Med J. 2008 Sep;49(9):667-71.
5. Menon V, Saxena R, Misra R, Phuljhele S. Management of optic neuritis. Indian J Ophthalmol. 2011 Mar-Apr;59(2):117–22.
6. Rodriguez M, Siva A, Cross SA, O'Brien PC, Kurland LT.

Optic neuritis: A population-based study in Olmsted County, Minnesota. Neurology. 1995;45:244–50.
7. MacDonald BK, Cockerell OC, Sander JW, Shorvon SD. The incidence and lifetime prevalence of neurological disorders in a prospective community-based study in the UK. Brain. 2000;123:665–76.
8. Bertuzzi F, Suzani M, Tagliabue E, et al. Diagnostic validity of optic disc and retinal fiber layer evaluations in detecting structural changes after optic neuritis. Ophthalmology. 2010; 117:1256-64.
9. Shams PN, Plant GT. Optic neuritis: a review. Int MS J. 2009; 16:82-9.
10. Pérez-Cambrodí RJ, Gómez-Hurtado Cubillana A, Merino-Suárez ML, Piñero-Llorens DP, Laria-Ochaita C. Optic neuritis in pediatric population: a review in current tendencies of diagnosis and management. J Optom. 2014 Jul-Sep;7(3):125-30.
11. Jenkins TM, Toosy AT. New developments in the treatment of optic neuritis. June 2010;2010:83-94.
12. Bonhomme GR, Mitchell EM. Treatment of Pediatric Optic Neuritis. Curr Treat Options Neurol. 2011;14(1):93-102.
13. Naseem A,Khan S, Khan MN, Mohammad S. Optic neuritis ; a three years retrospective study. J Postgrad Med Inst Oct - Dec 2006;20(4):361-5.
14. Ulrich J, Grooble LW. The optic nerve in multiple sclerosis; a morphological study with retrospective clinico pathological correlations. Neuro Opthalmol. 1983;3:149-59.
15. Trap BD, Peterson J. Axonal transaction in the lesions of multiple sclerosis. N Eng J Med. 1998;338:378-85.
16. Optic neuritis study group. Visual function more than 10 years after optic neuritis ; experience of optic neuritis treatment trail. Am J Ophthalmol. 2004;137:77-83.
17. Beck RW. The optic neuritis treatment trial. Arch Ophthalmol. 1988;106:1051–3.
18. Sellebjerg F, Frederiksen JL, Nielsen PM, Olesen J. Double-blind, randomized, placebo-controlled study of oral, high-dose methylprednisolone in attacks of MS. Neurology. 1998 Aug;51(2):529-34.
19. Durelli L, Cocito D, Riccio A, Barile C, Bergamasco B, Baggio GF, et al. High-dose intravenous methylprednisolone in the treatment of multiple sclerosis: clinical-immunologic correlations. Neurology. 1986 Feb;36(2):238-43.
20. Brusaferri F, Candelise L. Steroids for multiple sclerosis and optic neuritis: a meta-analysis of randomized controlled clinical trials. J Neurol. 2000 Jun;247(6):435-42.
21. Filippini G, Brusaferri F, Sibley WA, Citterio A, Ciucci G, Midgard R, et al. Corticosteroids or ACTH for acute exacerbations in multiple sclerosis. Cochrane Database Syst Rev. 2000;(4):CD001331.

Mohammad Idris

ORIGINAL ARTICLE

Efficacy of using Cynoacrylate Glue (n-butyl 2-cyboacrylate) for Closure of Skin Wound in External Dacryocystorhinostomy in terms of Safety & Comfort of the Patient

Mohammad Idris FCPS[1], Hasan Yaqoob FCPS, FRCS[2], Sher Akhbar FCPS[3]
Bilal Khan FCPS[4], Khalid Jamal MBBS[5], Jamal Hussain MBBS[6]

ABSTRACT

Objective: To determine the effectiveness of wound closure in external dacryocystorhinostomy (Ext DCR) with use of cyanoacrylate glue (c-glue) for skin wound closure in terms of safety, convenience, operating time, wound scar, dehiscence, infection, bleeding, and patient comfort.

Study design: prospective, interventional case Series.

Material and Methods: The study was carried out at Department of Ophthalmology, Govt. Lady Reading Hospital, Peshawar from July 2011 to Jan 2013. We received 50 cases from outdoor department for management and were admitted for ext DCR. Data was collected on special proforma and was analyzed with the help of SPSS Version16.

Results: The study population comprised of 50 cases. Females were in majority (60%). old patients than 40 years were common. Mean age was 62+/- 11 years common postoperative complications were wound Dehiscence and opening of wound (20%). redness and itching around wound area were the commonest postoperative complaints (24%).

Conclusion: Use of glue is a useful friendly option for the surgeon and the patient. It requires proper follow up for wound related problem like dehiscence or scar formation.

Key words: cyanoacrylate glue, external dacryocystorhinostomy, wound closure.

INTRODUCTION

To determine the effectiveness of wound closure in external dacryocystorhinostomy (DCR) with use of cyanoacrylate glue (c-glue) for skin wound closure in terms of safety, convenience, operating time, wound scar, dehiscence, infection, bleeding, and patient comfort.

Physicians have long sought an efficient method of wound repair that requires little time and minimizes discomfort for their patients, yet produces a good cosmetic outcome. Cyanoacrylate tissue adhesives is a tissue adhesive, may well meet these criteria. They have been shown to have negligible histotoxicity, to form a strong bond to wound edges and to provide long-term cosmesis equivalent to, or better than, traditional methods of repair. In addition, they require less than one half the time for wound closure.[1]

Advantages of an adhesive over sutures include maximum bonding strength at two and one-half minutes, equivalent in strength to healed tissue at seven days post repair, can be applied using only a topical anesthetic, no needles., faster repair time, better acceptance by patients and last but not the least, glue does not require removal of sutures.[2]

Cyanoacrylate tissue adhesives combine cyanoacetate and formaldehyde in a heat vacuum along with a base to form a liquid monomer.[3] When the monomer comes into contact with moisture on the skin's surface; it chemically changes into a polymer that binds to the top epithelial layer. This polymer forms a cyanoacrylate bridge, binding the two wound edges together and allowing normal healing to occur below. The conversion from monomer to polymer occurs rapidly, preventing seepage of the adhesive below the wound margins as long as the edges are well apposed. Heat is often generated during the change from monomer to polymer, and this heat may be felt on occasion by patients during application to the skin. Cyanoacrylate have also been shown to have antimicrobial properties.[4,5]

Randomized controlled clinical trials[6,7] have shown that infection rates are not significantly different between wounds that have been sutured and wounds that have been closed with glue. However, if adequate wound cleansing and preparation are compromised because of the ease of use of a tissue adhesive, an increase in infection rates could occur.

This tissue adhesive should not be used on animal bites, severely contaminated wounds, ulcers, puncture wounds, mucous membranes (including mucocutaneous junctions) or areas of high moisture

[1,6]Medical Officer, Ophthalmology Unit, PGMI, LRH Peshawar.
[2]Consultant, Ophthalmology Unit, North West General Hospital, Peshawar,
[3,4]Trainee Vitreoretina, Ophthalmology Unit, PGMI, LRH Peshawar,
[5]Camp Coordinator, Prevention of Blindness Trust, Peshawar,

Correspondence: Dr. Mohammad Idris FCPS, Medical Officer, Ophthalmology Unit, PGMI, Lady Reading Hospital, Peshawar, Cell: 0333-9417051, Email: idrisdaud80@gmail.com

Received: March 2015 Accepted: May 2015

content, such as the groin or axillae. The adhesive may be used on selected parts if these areas are kept dry and immobilized.[2,8] In our study we used glue instead of sutures for skin wound closure and studied its usefulness and possibilities in patients undergoing Ext. DCR.

Use of glue is a useful friendly option for the surgeon and the patient. It requires proper follow up for wound related problem like dehiscence, infection or scar formation.

MATERIAL AND METHODS

Study Design: prospective, interventional case series.

Place and duration: The study was conducted at the Department of Ophthalmology, Govt Lady Reading Hospital, Peshawar from July 2011 to Jan 2013.

***Sampling Technique*:** Convenience (non probability sampling).

***Sample size*:** 50 patients admitted for Ext DCR

Data Collection Procedures: Patients were selected from the Ophthalmology Out Patients Department of the Govt Lady Reading Hospital, Peshawar according to selection criteria. Patients were admitted to the Ophthalmology ward of the hospital. Diagnosis was based on history and routine ophthalmic examination. Detail assessment of eyelid as well as of face neck and intraocular structures were made. Written consent of all the patients ***included*** in the study was taken after fully explaining the procedure and purpose of the study to the patients.

Follow-ups: Patients had a follow-up on day one, at 4 month, 6 months and then last follow up at 1 year.

Before the start of the study, permission was taken from the hospital ethical committee. A written informed consent was obtained from the patients after fully explaining the procedure. All surgeries were performed by one surgeon. Same technique, size and position of skin incision were used. All patients were prescribed systemic antibiotics and post operative dexamethasone ointment for skin application. Patients were followed post operatively on day one, first month and sixth month. All patients who refused to give consent, infected cases, repeated surgeries and those having age more than ninety years were ***excluded*** from the study because of altered skin characteristics and healing.

Technique of Ext. DCR: All these patients were hospitalized and detailed clinical examinations were carried out. The site of obstruction was evaluated with regurgitation and lacrimal sac irrigation test. Other diagnostic procedure like External dacryocystography and Jones test were not performed. Viral profile was carried out before surgery. Most of the operations were carried out under local anesthesia using xylocaine 2% and also injected locally in those patients who underwent general anesthesia. This was done to avoid bleeding during surgical procedure. A nasal packed soaked with 4% xylocaine and two vials of injection.

Adrenaline was applied in ipsilateral nasal cavity in almost all cases. About 02 cm vertical skin incisions were given 8mm anterior to respective medial canthus and lacrimal fossa exposed. About 01cm circumferential bony window made between lacrimal fossa and middle meatus of the nasal cavity. Nasal mucosa and lacrimal sac opened and flaps were made. Anterior flap of the nasal mucosa and lacrimal sac were sutured using 4/0 catgut or 6/0 vicryl. Post operative medications included systemic antibiotics, analgesic and tranxaminic acid. Each patient discharged from the hospital after 24 hours

Postoperatively and was reviewed for syringing two days postoperatively in non intubated patients. In cases, where intubation was done, the lacrimal tube was removed after 06 months of surgery. The success criteria were absence of watering and patency of lacrimal pathway on syringing.

Technique of Glue Application: Following steps of wound closure with glue were followed and wound edges were approximated after cleaning area with antiseptic. Addhesive was brushed gently over the wound in 3 layers. Avoid pushing adhesive into wound . The glue covered the wound plus about 5–10 mm of skin on either side. Polymerization takes 30–45 seconds. Two additional layers should be used, with 10–15 seconds between each layer. Full strength was achieved after 2.5 minutes. Care should be taken not to get the glue near or in the eye. Eyes should be protected with gauze to prevent eyelid attachment or corneal deposition. Antibiotic ointment or petroleum jelly can facilitate removal of glue if corrections are required. Some patients are allergic to the cyanoacrylate or residual formaldehyde so to take a history in every case is important.

Data analysis: The data were analyzed by software SPSS (version 10.0).

Frequencies and percentages were calculated for age, gender and patient complaints and signs.

RESULTS

We used cyanoacrylate glue for the skin closure after Ext DCR and we studied the results of skin closure. Results were assessed in terms of mean operating time, pain, wound infection, wound dehiscence, scaring, wound healing, immediate postoperative complaints

and need for removal of stitches.

In table 1 gender distribution is shown. Female were in majority. 20 (40%) patients were male and 30 (60%) patients were female. In table 2 age distribution is shown in groups for ease of description. Age of the patient was divided into three groups, up to 20 years in 04 (8%) patients, 21-40 years 15 (30%) patients and more than 40 years 31 (62%) patients. So majority of the patients were older than forty years age. Finally the various aspects of wound closure of skin incision after dacryocystorhinostomy were studied in table 3. Different characteristics are shown. Mean operating time of skin closure was noted to be less than 2 min. Pain during wound closure was reported in only 04 (8%) patients. Post operative wound Dehiscence and opening of wound was noted in 10 (20%) patients. Significant scaring and patient satisfaction in 06 (12%) patients, Post operative wound healing was more rapid in young and infection of the wound was not noted in any patient. Common postoperative complaints were itching and redness at wound area. It was reported in 12 (24%) patients. Finally there were no sutures used and there was no need of removal of stitch.

Table 1: Gender distribution. (n=50)

Gender	n	%
Male	20	40
Female	30	60
Total	**25**	**100**

Table 2: Age distribution (n=50)

Age in years	n	%
Up to 20	04	8
21-40	15	30
41 and above	31	62
Total	**50**	**100**

Table 3: Comparison of wound characteristics of external dacryocystorhinostomy after skin closure by C- glue (n=50)

Key features	Findings
Mean operating time of wound closure	Less than 2 mints
Pain during wound closure	04 (8%)
Post operative wound Dehiscence and opening of wound	10 (20%)
Significant scaring	06 (12%)
Post operative wound healing	Rapid (young age)
Wound infection (post operative)	0 (0%)
Common postoperative complaint	Itching and redness at wound area 12 (24%)
Need for removal of suture	no

DISCUSSION

Dacryocystorhinostomy is a gold standard procedure for the treatment of blocked nasolacrimal duct obstruction. Different techniques are in use regarding dacryocystorhinostomy operation. Endoscopic DCR have its own advantage of less tissue trauma, no scar, less bleeding, early healing and rehabilitation but having failure chances more than conventional external dacryocystorhinostomy technique.[9] According to a study, major postoperative complications after Ext DCR included hemorrhage (3.9%) and scarring (2.6%).[10] Closure of wounds is often needed to promote wound healing and to produce an acceptable cosmetic result. Traditionally sutures and also adhesive strips have been used. Skin glues are safe and effective but wound selection is important.[11,12]

We determine the usefulness of glue instead of suture for wound closure. We have taken 50 patients. Female were in majority. This is because nasolacrimal duct obstruction is common in female gender.[13] Patients were divided into different age groups to determine study results in different age groups. The nasolacrimal duct obstruction is common in middle to old age. So our patients in study sample were also in majority in this age group. in our study the mean age of the patient was 62+/- 10 years According to a study mean age of patients who undergone Ext DCR was 64.5 years.[13]

Tissue glue is useful in many aspects like no-suture-related-complications; no bleeding at wound site in the skin, early rehabilitation. Wound infection is minimal because glue has antimicrobial properties. But scar size is sometime larger if not applied properly. So there is need for proper learning and technique of application. Therefore operating with glue or vicryl, these things should be kept in mind. In literature, glue has been used widely and safely for repair of skin wounds and traumatic laceration. One study has shown that the current adhesive properties have a bursting strength equivalent to 4/0 nylon in an intracuticular wound closure.[14] It has fewer complications when used externally only.

In our study main complication was scaring (significant scaring) but as discussed earlier can be easily avoided if applied with skillful hands. According to literature, not much study available to compare glue as an option in Ext. DCR skin closure. Complication like skin granuloma formation is minimal which is otherwise common when suture is used is well documented.

According to a study, scar formation is a frequently cited complication of external dacryocystorhinostomy (Ext DCR).[15] Mean operating time was very less.

Pain, significant scaring, wound dehiscence and post operative wound infection was also less as shown in table 3. According to studies wound infection can occur after Ext DCR.[16]

A study reported that wound closure with glue is achieved in several steps. The adhesive peels off in five to 10 days. Deep wounds without subcutaneous sutures seem to have a higher dehiscence rate.[17] In our studies, 4% of wounds reopen with skin glues compared to 1–2% with sutures. This was thought to be due to a combination of poor technique, poor wound selection, but most importantly breakage of bonds or sloughing from the skin surface. Dehiscence may cause delayed healing, poor cosmetic result and possible infection.[11,14] Cosmetic appearance with skin glues is comparable to outcomes with sutures and strip approximation.[11] Most of the trials have used a blinding method with photographs assessed by plastic surgeons, other doctors and patients themselves. Comparisons were made of appearance, absence of step-off, margin irregularities, separation, edge inversion and wound distortion. The results universally recorded that final cosmetic appearance for skin glues was similar to sutures.[18, 19] Procedure time is reduced.[11, 14], Studies reported that the time of the actual wound repair in all settings was less than formal suturing. Applying skin glue is painless. In about 20% of patients there is a report of a sensation of mild heat but no actual pain.[11] Wound infection rates are low (less than 3%) and are not increased with skin glues.[20]

Wound healing was more rapid in young age group only when we used glue. It is because natural growth process is rapid in young people. One of the major finding reported by the patient was cosmetic unawareness unlike sutures on the wound site of the face. We noted itching and redness of the skin as the commonest postoperative complaint in cases where we used glue to the site. It is because of the fact that glue is a chemical and if it gains access to the inside of the wound, it acts as a foreign body and results in inflammation of the skin wound. It explains why careful application of glue with technical hands is very important.[21] Finally since no sutures are used so there is no need of suture removal and second visit to operation theatre is not needed. Patient satisfaction with skin glues was higher than with sutures in most studies. Reasons included lack of pain, ease of wound care and no need for follow-up and suture removal. [22]

Overall glue was found useful and was preferred according to our study in terms of more benefits to the patients and their satisfaction. Skin glues are a safe and effective method to close selected wounds. They can also help prevent infection. Ideally, wounds should be less than 4 cm, not contaminated or infected and have skin edges that are not under tension. Wounds should be closed within 12 hours. Dehiscence is slightly higher with skin glues than with sutures, but the cosmetic outcome is comparable and skin glues are painless. A larger study is needed to be conducted to evaluate for further elaboration and justification of the use of glue in ophthalmology especially oculoplasty.

Fig 1: Very minimal scar after external dacryocystorhinostomy skin wound closure with glue (photo by the author.)

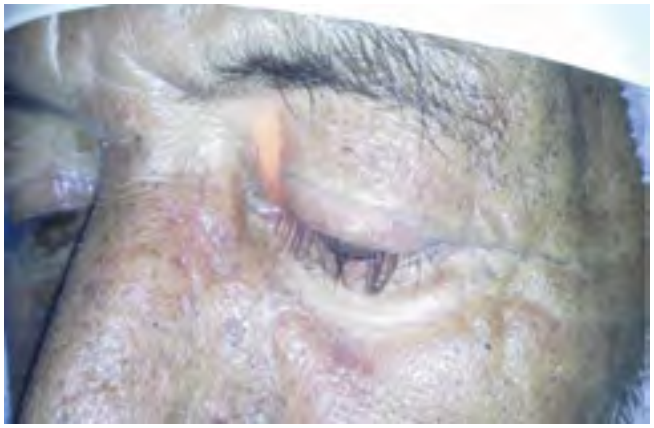

Fig 2: Redness and itching as commonest postoperative complaints of the patient after glue application.

CONCLUSION

Use of glue is a useful and surgeon and patient friendly option and require proper follow up and no need of removal of stitch after one week. Other Advantages are that postoperative results were good, less pain, less operating time and results were especially more rapid in young patients. Wound related problems like dehisce, or scar formation need early treatment and so follow up is important. Glue needs to be applied in selected clean wounds with skill to avoid deep penetration of the material into wound.

REFERENCES

1. Quinn JV, Drzewiecki A, Li MM, Stiell IG, Sutcliffe T,

Elmslie TJ, et al. A randomized, controlled trial comparing a tissue adhesive with suturing in the repair of pediatric facial lacerations. Ann Emerg Med. 1993;22:1130–5.
2. Quinn J, Wells G, Sutcliffe T, Jarmuske M, Maw J, Stiell I, et al. A randomized trial comparing octylcyanoacrylate tissue adhesive and sutures in the management of lacerations. JAMA. 1997;277:1527–30.
3. Quinn JV. Tissue adhesives in wound care. Hamilton, Ontario: Decker, 1998:34.4-Toriumi DM, Raslan WF, Friedman M, Tardy ME. Histotoxicity of cyanoacrylate tissue adhesives.Arch Otolaryngol Head Neck Surg. 1990;116:546–50.
5. Howell JM, Bresnahan KA, Stair TO, Dhindsa HS, Edwards BA. Comparison of effects of suture and cyanoacrylate tissue adhesive on bacterial counts in contaminated lacerations. Antimicrob Agents Chemother. 1995;39:559–60.
6. Singer AJ, Hollander JE, Valentine SM, Turque TW, McCuskey CF, Quinn JV. Prospective, randomized, controlled trial of tissue adhesive (2-octylcyanoacrylate) vs. standard wound closure techniques for laceration repair. Acad Emerg Med. 1998;5:94–9.
7. Maw JL, Quinn JV, Wells GA, Ducic Y, Odell PF, Lamothe A, et al. A prospective comparison of octylcyanoacrylate tissue adhesive and suture for the closure of head and neck incisions. J Otolaryngol. 1997;26:26–30.
8. Bruns TB, Robinson BS, Smith RJ, Kile DL, Davis TP, Sullivan KM, et al. A new tissue adhesive for laceration repair in children. J Pediatr. 1998;132:1067–70.
9. Hartikainen J[1], Grenman R, Puukka P, Seppä H. Prospective randomized comparison of external dacryocystorhinostomy and endonasal laser dacryocystorhinostomy. Ophthalmology. 1998 Jun;105(6):1106-13.
10. Tarbet KJ, Custer PL. External dacryocystorhinostomy: surgical success, patient satisfaction, and economic cost. Ophthalmology. 1995;102(7):1065–1070.
11. Farion KJ, Russell KF, Osmond MH, Hartling L, Klassen TP, DurecT, et al. Tissue adhesives for traumatic lacerations in children and adults. Cochrane Database Syst Rev 2009;1:CD003326.
12. Göktas N, Karcioglu O, Coscun F, Karaduman S, Menderes A. Comparison of tissue adhesive and suturing in the repair of lacerations in the emergency department. Eur J Emerg Med 2002;9:155-8.
13. Pandya VB, Lee S, Benger R, et al. External dacryocystorhinostomy: assessing factors that influence outcome.Orbit. 2010;29(5):291–297.
14. Singer AJ, Quinn JV, Hollander JE. The cyanoacrylate topical skin adhesives. Am J Emerg Med 2008;26:490-6.
15. Tear Trough Incision for External Dacryocystorhinostomy. Davies BW, McCracken MS, Hawes MJ, Hink EM, Durairaj VD, Pelton RW. Ophthal Plast Reconstr Surg. 2014 Sep 11. [Epub ahead of print]
16. Dolman PJ. Comparison of external dacryocystorhinostomy with nonlaser endonasal dacryocystorhinostomy. Ophthalmology. 2003 Jan;110(1):78-84.
17. Quinn J, Wells G, Sutcliffe T, Jarmuske M, Maw J, Stiell I, et al. A randomized trial comparing octylcyanoacrylate tissue adhesive and sutures in the management of lacerations. JAMA. 1997;277:1527–30.
18. Zempsky WT, Parrotti D, Grem C, Nichols J. Randomised controlled comparison of cosmetic outcomes of simple facial lacerations closed with Steri Strip skin closures or Dermabond tissue adhesive. Pediatr Emerg Care 2004;20:519-24.
19. Eaglstein WH, Sullivan T. Cyanoacrylates for skin closure. Dermatol Clin 2005;23:193-8.
20. Chow A, Marshall H, Zacharakis E, Paraskeva P, Purkayastha S. Use of tissue glue for surgical incision closure: a systematic review and meta-analysis of randomised controlled trials. J Am Coll Surg 2010;211:114-25.
21. Toriumi DM, O'Grady K, Desai D, Bagal A. Use of octyl-2-cyanoacrylate for skin closure in facial plastic surgery. Plast Reconstr Surg. 1998; 102: 2209–19.
22. Man SY, Wong EM, Ng YC, Lau PF, Chan MS, Lopez V, et al. Cost-consequence analysis comparing 2-octyl cyanoacrylate tissue adhesive and suture for closure of simple lacerations: a randomised controlled trial. Ann Emerg Med 2009;53:189-97.

Omar Ilyas

ORIGINAL ARTICLE

Mean Rise of IOP after IOL Implantation using 2% Hydroxypropyle Methylcellulose (HPMC) & 1% Sodium Hyaluronate (NAHA) Viscoelastics

Omar Ilyas MBBS[1], Mubashir Rehman FCPS[2], Farooq Khan MBBS[3]
Mohammad Sajid Khan MBBS[4], Sadia Sethi FCPS[5]

ABSTRACT:
Objective: To compare mean intraocular pressure rise after phacoemulsification with implantation of intraocular lens using 2% HPMC and 1% NaHa as viscoelastics.
Study design: Randomized control trial.
Place and duration of study: Ophthalmology Department, Khyber Teaching Hospital Peshawar from 1st August 2013 to 1st January 2014.
Patients and methods: A detailed slit lamp examination was performed in all patients to look for any signs of intraocular inflammation or evidence of previous intraocular surgery. Those who fit the inclusion criteria were then randomly allocated into 2 groups. One group had been receiving 1% sodium hyaluronate as viscoelastic while second group 2% hydroxypropyle methylcellulose as viscoelastic. All surgeries were done by a single ophthalmologist. IOP was measured by the same ophthalmologist 1 day prior to surgery, then 1 day post operatively using Goldman applanation tonometer.
Results: Mean age in Group A was 62 year with standard deviation ± 2.06, while in Group B was 64 year with standard deviation ± 2.87. In Group A 60% patients were male and 40% patients were female, while in Group B 57% patients were male and 43% patients were female. The mean rise of IOP in Group A was 4.36 ± 2.02 mmHg while the mean rise of IOP in Group B was 3.02± 2.36 mmHg.
Conclusion: Our study concluded that Sodium Hyaluronate causes significantly higher increase in intraocular pressure in early post-operative period after cataract surgery inspite of maximum aspiration of viscoelastic substance from the eye following phacoemulsification surgery.
Key Words: Intraocular pressure, phacoemulsification, viscoelastics.

INTRODUCTION

The development of new surgical phaco techniques is aimed at restoring visual acuity (VA) in order to secure a fast return to normal social life and work. Small incision phaco procedures have minimized postoperative astigmatism.[1]

Application of viscoelastic substances has improved quality of anterior chamber surgery. The first use of viscoelastic agents in cataract surgery was described in 1972 by Balaz et al.[2] Viscoelastics, or ophthalmic visco-surgical devices (OVDs), facilitate cataract surgery by maintaining the depth and shape of the anterior chamber. This provides a workspace for the surgeon and provides a viscous barrier that protects the delicate corneal endothelium from surgical instruments, from cataractous lens debris, and from the intraocular lens during insertion.[3]

An ideal viscoelastic substance possesses certain important rheological properties like viscosity, elasticity and pseudoplasticity. Viscosity makes a material protective and lubricating, while elasticity provides protection from vibration and other mechanical impacts. Pseudoplasticity causes the material to deform which allows safe manipulation of tissues. An ideal viscoelastic substance must be sterile, optically clear, non-inflammatory, dilutable, hydrophilic and biologically inert.[4]

Early OVDS were classified as either cohesive or dispersive, on the basis of objective rheological properties.[5] A cohesive hyaluronate OVD with high molecular weight, such as Healon, contains long polysaccaride chains with glycosidic connections, which gives it higher viscosity, pseudoplasticity and cohesiveness. Cohesive OVDs are good at maintaining space and stabilizing tissue during surgery. They are easy to inject and to remove from the anterior chamber.[1]

Dispersive viscoelastic substances like 2% HPMC has lower viscosity with short molecular chains that have less tendency to entangle. They have better adherence to the corneal endothelium against fluid during phacoemulsification.[4]

The major complication of viscoelastic material

[1,3,4]Trainee Medical Officer, Ophthalmology Department, Khyber Teaching Hospital, Peshawar. [2]Medical Officer, Ophthalmology Department, Lady Reading Hospital, Peshawar. [5]Associate Professor, Ophthalmology Department, Khyber Teaching Hospital, Peshawar

Correspondence: Dr. Omar Ilyas, Trainee Medical Officer, Ophthalmology Department, Khyber Teaching Hospital, Peshawar. Mob: 0345-9063628, E-mail: drdeath944@gmail.com House No: K-3974, Mohallah Kotla Feelbanan, Tehsil, Peshawar.

Received: April 2015 Accepted: June 2015

usage within first 24 hours after cataract surgery is perhaps responsible of higher post operative intraocular pressure. Leaving a significant amount of an agent in the anterior chamber with obstruction to the outflow of aqueous humor from the anterior chamber may cause intraocular pressure rise. This may be due to mechanical obstruction of trabecular meshwork or functional or instructional damage of trabecular meshwork.[2]

The rise in intraocular pressure most commonly occur between 4-7 hours post-operatively and often returns to normal within 24-48 hours.[4] Residual OVD left in the eye can clog the trabecular meshwork, leading to a transient elevation in postoperative intraocular pressure.[5] The rationale of this study will be to evaluate the short term effect of these two different viscoelastics on post operative intraocular pressure. Due to the great variation of result between national and international studies this study will help us in generation of our own data regarding post operative IOP using different viscoelastics and will influence our management towards patients in future as regard to the preference of one particular type of viscoelastic.

***Study design*:** It was a Randomized control trial.

Sodium Hyaluronate causes significantly higher increase in IOP as compared to hydroxypropyl methylcellulose in early post-operative period in spite of maximum aspiration of viscoelastic substance, following phacoemulsification surgery.

METHODS

All those patients who were admitted for phacoemulsification with implantation of IOL as per indication of senile immature cataract through OPD to Eye Ward of KTH were evaluated. Before evaluation all the patients were provided with complete information about the study and informed written consent was taken from each.

A detailed slit lamp examination was performed in all these patients to look for any signs of intraocular inflammation or evidence of previous intraocular surgery. Gonioscopy and fundus examination was done for glaucoma. All patients having normal preoperative intraocular pressure (11mm Hg-21mm Hg), gonioscopically open angle (Shaffer's Grade III & IV), immature senile cataract with age 45-70 years were included in the study. Patients with history of previous intraocular surgery, glaucoma, intraocular inflammation, diabetes mellitus and hypertension were excluded from the study.

Those who fit the inclusion criteria were then randomly allocated into 2 groups. One group had been receiving 1% sodium hyaluronate as viscoelastic while second group 2% hydroxymethylcellulose as viscoelastic. A comprehensive proforma was devised to record patient's particulars. All the surgeries were done by a single ophthalmologist. IOP was measured by the same ophthalmologist 1 day prior to surgery, then 1 day post operatively using Goldman applanation tonometer while pressure lowering drug was not used during this time.

All the data was collected and analyzed by SPSS version 12 for windows. Student T test was used to compare the mean IOP of each group at each time interval. T test was also applied for comparison of results between the two groups. A P-value of < 0.05 was used as significance cut off point. For gender male to female ratio was also be calculated. The results obtained were presented through tables, charts and graphs.

RESULTS

This study was conducted at Ophthalmology Department, Khyber Teaching Hospital Peshawar in which a total of 80 patients (40 in each group) were observed to compare mean intraocular pressure rise after phacoemulsification with implantation of intraocular lens using 2% HPMC and 1% NaHa as viscoelastics and the results were analyzed.

Age distribution among two groups was analyzed as in Group A, 8(20%) patients were in age ranging from 45-55 years, 17(43%) patients were in age ranging from 56-65 years and 15(37%) patients were in age ranging from 66-70 years.

Mean age was 62 year with standard deviation ± 2.06. Where as in Group B 9(23%) patients were in age ranging from 45-55 years, 16(41%) patients were in age ranging from 56-65 years and 15(36%) patients were in age ranging from 66-70 years. Mean age was 64 year with standard deviation ± 2.87. (as shown in Table No 1). Gender distribution among two groups was analyzed as in Group A 24(60%) patients were male and 16(40%) patients were female. Where as in Group B 23(57%) patients were male and 17(43%) patients were female. (as shown in Table No 2).

Rise in the mean IOP between two groups was analyzed as in Group A, the baseline IOP was 16.01 ± 1.84 mmHg but after 24 hours follow up the mean IOP was 20.37 ± 1.93 mmHg so the mean rise of IOP was 4.36 ± 2.02 mmHg. Where as in Group B the baseline IOP was 16.06 ± 1.97 mmHg but after 24 hours follow up the mean IOP was 19.08± 2.01 mmHg so the mean rise of IOP was 3.02± 2.36 mmHg. (as shown in Table No 3).

TABLE NO 1. Age distribution (n=80)

AGE	GROUP A	GROUP B
45-55 years	8(20%)	9(23%)
56-65 years	17(43%)	16(41%)
66-70 years	15(37%)	15(36%)
Total	40(100%)	40(100%)
Mean and SD	62 year ± 2.06	64 year ± 2.87

Chi square test was applied in which P value was 0.002
Group A : 1% sodium hyaluronate. Group B: 2% hydroxymethylcellulose

TABLE NO 2. Gender Distribution (N=80)

GENDER	GROUP A	GROUP B
Male	24(60%)	23(57%)
Female	16(40%)	17(43%)
Total	40(100%)	40(100%)

Chi square test was applied in which P value was 0.002
Group A : 1% sodium hyaluronate. Group B: 2% hydroxymethylcellulose

TABLE 3: Mean IOP (N=80)

IOP	GROUP A	GROUP B	P value
Baseline Mean Std. Deviation	16.01 mm Hg ± 1.84	16.06 mm Hg ±1.97	0.000
At 1 day Mean Std. Deviation	20.37 mm Hg ± 1.93	19.08 mm Hg ±2.01	0.003
Mean intraocular pressure rise after phacoemulsification	4.36 mm Hg ± 2.02	3.02 mm Hg ± 2.36	0.004

Student T test was applied in which P value are mentioned above
Group A: 1% sodium hyaluronate, Group B: 2% hydroxymethylcellulose.

DISCUSSION

Sodium hyaluronate (NaHa) is a biopolymer occurring in many connective tissues throughout the body, including both the aqueous and vitreous humors. Its basic structural unit is a disaccharide, joined by a β_{1-4} glucosidic bond, which is linked in a repeating fashion with β glucosidic bonds to form a long unbranched chain. This mucopolysaccharide chain subsequently forms a random coil when placed in a solution, such as physiologic saline. As the concentration of large sodium hyaluronate molecules is increased (>0.5 mg/mL), individual molecular coils start to overlap and are compressed. This crowding of the chains increases the chances for various noncovalent chain–chain interactions. This, in turn, causes a considerable increase in the viscosity of the solution. For example, the kinematic viscosity of a 2 mg/mL concentration of sodium hyaluronate in physiologic buffer is only in the 100-cSt range: at 10 mg/mL, it is in the 100,000 cSt range. Therefore, a fivefold increase in the concentration causes a 1000-fold increase in the viscosity of the solution. With this increase in viscosity, the elastic properties of the solution also increase. This forms the rationalization of Amvisc Plus and Healon GV.

The elastic behavior of a concentrated (>0.5mg/mL) sodium hyaluronate solution is greatly dependent on the mechanical energy (shear force) applied to the solution. On a molecular level, this means that under the imposed strain, the polysaccharide coils slip by each other, and conformational and configurational rearrangements occur while the solution exhibits viscous flow. The hyaluronate acid fraction (NIF-NaHa) used for ophthalmic procedures has a high molecular weight (2–5 million d), a low protein content (<0.5%), and carries a single negative charge per disaccharide unit.

This fraction is highly purified and has been shown to be sterile, nontoxic, nonantigenic, noninflammatory, and pyrogen-free. In primate vitreous humors, sodium hyaluronate has a half-life of approximately 72 days. In primate aqueous humors the half-life is 2 to 7 days depending on the viscosity. Clinical observations in humans have supported this result.[6] Hydroxypropyl Methylcellulose (HPMC) is yet another viscoelastic material used for intraocular procedures. Unlike the previous two compounds, it does not occur naturally in animals but is distributed widely as a structural substance in plant fibers, such as cotton and wood. It is a cellulose polymer composed of D-glucose molecules linked together by β-glycosidic bonds.[7]

Special care must be taken in the filtration of this material to ensure a highly purified preparation, as Rosen et a1. noted the presence of vegetable fibers and other contaminates in samples they examined. Methylcellulose is a non-physiologic compound and, as such, does not appear to be metabolized intra-ocularly but is eliminated from rabbit anterior chambers in approximately 3 days. It is also quite hydrophilic and hence can be irrigated from the eye.[7]

Our study shows that the mean age in 1% Sodium Hyaluronate Group was 62 years with standard deviation ± 2.06, while the mean age in 2% Hydroxypropyl Methylcellulose Group was 64 years with standard deviation ± 2.87. In 1% Sodium Hyaluronate Group 60% patients were male and 40% patients were female, while in 2% Hydroxypropyl Methylcellulose Group 57% patients were male and 43% patients were female.

The mean rise of IOP in 1% Sodium Hyaluronate Group was 4.36 ± 2.02 mmHg while the mean rise of IOP in 2% Hydroxypropyl Methylcellulose Group was 3.02± 2.36 mmHg.

Similar results were observed in another study conducted by Waseem M1 et al[8] in Peshawar in which there was no significant difference in the pre-operative intraocular pressure between the two groups (p=0.483). Twenty four hours after surgery, the mean IOP increased by 2.84+/-SD 2.12 mm Hg in 2% Hydroxypropyl Methylcellulose group and 4.54+/-2.07 mm Hg in 1% Sodium Hyaluronate group. The increase was significantly higher in 1% Sodium Hyaluronate group as compared to 2% Hydroxypropyl Methylcellulose group (p=0.003). Seven days after surgery the mean intraocular pressure returned to near pre-operative levels in both the groups. He concluded that Sodium Hyaluronate causes significantly higher increase in intraocular pressure in early post-operative period after cataract surgery inspite of maximum aspiration of viscoelastic substance from the eye following phacoemulsification surgery.

In one international study a total of 80 eyes underwent manual small incision cataract surgery. The highest mean IOP increase occurred at 8 hours postoperatively (5.3±6.4 mmHg) in the sodium hyaluronate 1% group and at 2 hours postoperatively (7.8±6.1 mmHg) in the hydroxypropyl methylcellulose 2% group. Overall, the IOP increase was higher with hydroxypropyl methylcellulose 2% (P = 0.005). Intraocular pressure spikes to ≥30 mmHg occurred in 5 eyes (13%) in the sodium hyaluronate 1% group and 13 eyes (33%) in the hydroxypropyl methylcellulose 2% group[9].In another study carried out at Combined Military Hospital Peshawar showed that mean intraocular pressure elevation (IOP) at 24 hours post operatively after surgery was significantly higher in 1% sodium hyaluronate group(4.54±2.07) as compared to 2% hydroxypropyl methylcellulose group(2.84±2.12) with p value <0.001 that was statistically significant[4].

CONCLUSION:

Our study concludes that Sodium Hyaluronate causes significantly higher increase in intraocular pressure as compared to hydroxypropyl methylcellulose in early post-operative period after cataract surgery in spite of maximum aspiration of viscoelastic substance from the eye following phacoemulsification surgery.

REFRENCES:

1. Kanski JJ. Lens. In: Kanski JJ Clinical Ophthalmology. A systemic approach 6th ed. Butterworth Heinemann Elsevier 2007;337-70.
2. Zaman M, Iqbal S, Khan YM, Khan MT, Jadoon MZ, Qureshi MB, et al. Manual small incision cataract surgery (MSICS). Review of first 500 cases operated in microsurgical training center. Pak J Ophthalmol 2006;22:14-22.
3. Khan AQ, Qureshi B, Khan MD. Rapid assessment of cataract blindness in age 40 years and above in District Skardu, Baltistan, Northern Areas of Ptakistan. Pak J Ophthalmol 2003;19:84-9.
4. Qazi ZA. Corneal endothelium tissue that demands respect. Pak J Ophthalmol 2003;19:1-2.
5. Ahmad A, Ahmad J. Combined phacoemulsification, intraocular lens implantation and trabeculectomy. Pak J Ophthalmol 2000;16:26-8.
6. Lever J, Dahan E. Opposite clear corneal incision to correct preexisting astigmatism in cataract surgery. J Cataract Refract Surg 2000;26:803-5.
7. Tadros A, Habib M, Tejwani D, Lany HV, Thomas P. Opposite clear corneal incisions on the steep meridian in phacoemulsification: early effects on the cornea. J Cataract Refract Surg 2004;30:414-7.
8. Waseem M1, Rustam N, Qamar ul Islam. Intraocular pressure after phacoemulsification using hydroxypropyl methylcellulose and sodium hyaluronate as viscoelastics J Ayub Med Coll Abbottabad. 2007 Jan-Mar;19(1):42-5.
9. Chakrabarti A, Singh S. Phacoemulsification in eyes with white cataract. J Cataract Refract Surg 2000;26:1041-7.

سر فروشی کی تمنا اب ہمارے دل میں ہے
دیکھنا ہے زور کتنا بازوئے قاتل میں ہے

مولانا ظفر علی خانؒ

ہر چارہ گر کو چارہ گری سے گریز تھا
ورنہ ہمیں جو درد تھے، وہ لادوا نہ تھے

Bilal Khan

ORIGINAL ARTICLE

Frequency of Ocular Co-morbidity in Patients with Age - related Cataract in A Tertiary Care Hospital of KPK

Bilal Khan FCPS[1], Muhammad Usman Khan MBBS[2], Mohammad Idris FCPS[3]
Ashfaq ur Rehman MBBS[4], Jamal Hussain MBBS[5]

ABSTRACT

Objective: To determine frequency of ocular co morbidity in patients with age related cataract in a tertiary care hospital of Khyber Pakhtunkhwa.

Material and Methods: This study was conducted at Eye Department, Khyber Institute of Ophthalmic Medical Sciences, Postgraduate Medical Institute, Lady Reading Hospital, Peshawar. Study design was descriptive (cross sectional) study and the duration of the study was 6 months. The sample size was 156. Non probability consecutive sampling technique was used for sample collection.

Results: In this study mean age was 60 years with standard deviation ± 2.57. Fifty three percent patients were male and 47% patients were female. The incidence of ocular co morbidity was 42% patients in which refractive error found in 43% patients, ARMD found in 14% patients, glaucoma found in 9% patients, diabetic retinopathy found in 7% patients, others include CVS and general diseases 27%.

Conclusion: Ocular co morbidities are highly prevalent among persons undergoing cataract surgery in this rural area setting, and their presence is significantly associated with poorer visual outcomes.

Key Words: Ocular co-morbidity, age related, cataract surgery.

INTRODUCTION

Visual impairment is a global health problem.[1] It is estimated that 37 million of the world population is blind and 124 million have severe visual impairment.[1] According to previous studies cataract is responsible for 50% of blindness worldwide.[2] The number of people blind from cataract is expected to rise due to the increase in life expectancy.[3] Increasing age is also known to influence the visual acuity achieved after cataract surgery.[4]

Cataract surgery yields excellent visual outcomes for the majority (71%) of patients.[5] The outcome of cataract surgery is dependent on a complex interplay of systemic, ocular, operative and postoperative factors. The greatest influence on visual outcome is due to ocular co morbidity resulting in complex surgery and postoperative complications.[6]

With the incidence of ocular diseases such as age-related macular degeneration, glaucoma and diabetes rising as populations around the world age, an increasing number of patients who require cataract surgery may present with a complex situation.[6]

[1]Trainee Medical Officer, Vitreoretina, Ophthalmology Unit, PGMI, LRH Peshawar, [2]Medical Officer, Khyber Eye Foundation, Peshawar, [3]Medical Officer, Khyber Eye Foundation, Peshawar, [4]Medical Officer, Basic Health Unit, Hangu, [5]Trainee Medical Officer, Ophthalmology Unit, PGMI, LRH Peshawar

Correspondence: Dr. Mohammad Idris FCPS, Medical Officer, Ophthalmology UNIT, PGMI, LRH Peshawar, KPK
Cell: 0333-9417051, E-Mail: idrisdaud80@gmail.com

Received: January 2015 Accepted: March 2015

The rationale of the study is that ocular co morbidity has impact on the final visual outcome for patients, many of whom may have unrealistic expectations from the surgery. Conversely, the preoperative examination for cataract surgery may serve as the only opportunity to diagnose and manage treatable ocular conditions. Also failure to recognize these conditions may result in complications during surgery. The study will document the frequency of ocular co morbidity in patients with age related cataract which will be shared with the ophthalmologic community. It will suggest strategies to improve the preoperative detection and management of ocular co-morbidities.

Objective: To determine frequency of ocular co morbidity in patients with age related cataract in a tertiary care hospital of Khyber Pakhtunkhwa.

Ocular co morbidities are highly prevalent among persons undergoing cataract surgery in this rural area setting, and their presence is significantly associated with poorer visual outcomes.

MATERIAL AND METHOD

Setting: Eye Department, Khyber Institute of Ophthalmic Medical Sciences, Postgraduate Medical Institute, Lady Reading Hospital, Peshawar.

Study Design: Descriptive (cross sectional) study

Duration of Study: 6 months.

Sample Size: Using WHO sample size calculator, where confidence level=95%, Absolute precision = 4.5%, Popu-

lation proportion (P) of diabetic retinopathy in patients with age related cataract = 9%[9,13] So the sample size= 156

***Sampling Technique*:** Non probability consecutive sampling

Inclusion criteria:

1. Adults with age related cataract of either gender.
2. Patients over 50 years of age.

Exclusion Criteria:

1. History of previous intraocular or refractive surgery.
2. Patients with dense cataract with no view of retina on slit lamp examination
3. History of systemic illness e.g. cardiovascular, renal or neurological disease.
4. Other causes of cataract such as trauma, use of oral steroids, etc.
5. The above mentioned conditions act as confounders and if included had introduce bias in the results.

Data Collection Procedure: An approval from the ethic committee of the hospital was sought. Each patient was included in the study through the outpatient department with age related cataract as examined on slit lamp biomicroscopy. An informed written consent was sought from the patient for inclusion into the study. A detailed history and systemic examination of the patient was carried out followed by visual acuity testing on a Snellen's chart, refraction and routine ophthalmological (slit-lamp) examination including a fundus examination. This was allowed for detection of confounders which were excluded to control bias in the study results. The examination was done by an experienced and qualified surgeons.

Data Analysis: The data was analyzed using SPSS (Statistical package for Social Sciences) version 10.0. Frequencies and percentages were calculated for categorical variables i.e. gender and ocular co morbidities (refractive error, age related macular degeneration, glaucoma, diabetic retinopathy). Mean +/- standard deviation was computed for numeric variables that is age. Ocular co morbidity was stratified among age and gender to see the effect modifiers. All the results were presented in tables and graphs.

A separate data collection proforma is designed (Annexure 1). Personal data, demographics, laterality, presence or absence and name of ocular comorbidity was consigned to the proforma.

RESULTS

This study was conducted at Eye Department, KIOMS, Lady Reading Hospital, Peshawar, in which a total of 156 patients were observed. Age distribution among 156 patients was analyzed as n=72 (46%) patients were in age ranged from 51-60 years and n=84 (54%) patients were above 60 years. Mean age was 60 years with standard deviation ± 2.57. (as shown in table no 1) Gender distribution among 156 patients was analyzed as n=83(53%) patients were male while n=73 (47%) patients were female. (as shown in table no 2) Ocular co morbidity was found in n=66(42%) patients while no morbidity was found in n=90 (58%) patients. (as shown in table no 3)Co- morbidity condition among 66 patients was analyzed as refractive error found in n=28 (43%) patients, ARMD found in n=9 (14%) patients, Glaucoma found in n=6 (9%) patients, Diabetic Retinopathy found in n=5 (7%) patients, and others include CVS and general diseases 27%. (as shown in table no 4)

Stratification of co morbidity condition with age distribution was analyzed as in 28 cases of refractive error, 11 patients were in age ranged from 51-60 years and 17 patients were above 60 years. In 9 cases of ARMD, 3 patients were in age ranged from 51-60 years and 6 patients were above 60 years. In 6 cases of glaucoma, 2 patients were in age ranged from 51-60 years and 4 patients were above 60 years. In 5 cases of diabetic retinopathy, 2 patients were in age ranged from 51-60 years and 3 patients were above 60 years. (as shown in table no 5)

Stratification of co morbidity condition with gender distribution was analyzed as in 28 cases of refractive error, 16 patients were male and 12 patients were female. In 9 cases of ARMD, 5 patients were male and 4 patients were female. In 6 cases of glaucoma, 3 patients were male and 3 patients were female. In 5 cases of diabetic retinopathy, 3 patients were male and 2 patients were female. (as shown in table no 6)

Table-1: Age Distribution (N=156)

Age distribution	Frequency	Percentage
51-60 years	72	46%
> 60 years	84	54%
Total	156	100%

Mean age was 60 years with standard deviation ± 2.57.

Table-2: Gender Distribution (n =156)

Gender distribution	Frequency	Percentage
Male	83	53%
Female	73	47%
Total	156	100%

Table-3: Ocular Co-morbidity (n =156)

Ocular Co Morbidity	Frequency	Percentage
Present	66	42%
Absent	90	58%
Total	156	100%

Table-4: Co-morbidity Condition (n = 66)

Co morbidity condition	Frequency	Percentage
Refractive error	28	43%
ARMD	9	14%
Glaucoma	6	9%
Diabetic Retinopathy	5	7%
Others others include CVS and general diseases	18	27%
Total	66	100%

Table-5: Stratification of Co-morbidity Condition With Age Distribution(n = 66)

Co Morbidity Condition	51-60 years	>60 years	TOTAL
Refractive error	11	17	28
ARMD	3	6	9
Glaucoma	2	4	6
Diabetic Retinopathy	2	3	5
Others others include CVS and general diseases.	8	10	18
Total	26	40	66

Chi square test was applied in which P value was 0.003

Table-6: Stratification of Co-morbidity Condition with Gender Distribution (n = 66)

Co Morbidity Condition	Male	Female	TOTAL
Refractive error	16	12	28
ARMD	5	4	9
Glaucoma	3	3	6
Diabetic Retinopathy	3	2	5
Others	11	7	18
Total	38	28	66

Chi square test was applied in which P value was 0.002

DISCUSSION

Cataract remains the leading cause of blindness in the world,[1] though studies have demonstrated excellent potential for return to normal vision with extraction of the cataractuous lens in both the developed and developing worlds. However, an important limitation on the excellent visual results usually associated with cataract surgery is the presence of ocular co morbidities.

Our study shows that mean age was 60 years with standard deviation ± 2.57. Fifty three percent patients were male and 47% patients were female. The incidence of ocular co morbidity was 42% patients in which refractive error found in 43% patients, ARMD found in 14% patients, glaucoma found in 9% patients, diabetic retinopathy found in 7% patients. Similar results were found in other studies as epidemiological studies are consistent in reporting an overall 26% to 49% incidence of ocular co morbidity in cataract patients.[7,8,9] Refractive error is the most common co morbidity (59.7%).[10] Other conditions include Age related macular degeneration (ARMD) (17.3%),[11] glaucoma (10.6%)[9] and diabetic retinopathy (9 %).[7,11]

In the literature, ARMD is the most common co morbidity that decreases visual outcome after cataract surgery. Yorston D[12] reported that a higher prevalence of pre-existing ocular diseases—for example, age-related maculopathy—may affect cataract surgery outcomes in very elderly patients. Progression of ARMD after cataract surgery has been suggested.[13, 14] Coexisting ocular abnormalities have been shown to have a negative effect on postoperative visual results.

The 42% prevalence of co-morbidities in operated eyes among our rural areas subjects is within the range of 26% to 49% reported for studies from the developed world.[15] Though few data on co morbidities are available from rural Asia, our results are generally in line with those reported by Bourne et al from Bangladesh. Among operated eyes failing to achieve good (6/18) presenting vision, non-refractive co-morbidities (Bangladesh 28%, current study 33%) were the second-leading cause, after refractive error (60% in Bangladesh, 72% in our study).[16] (Note that, due to the presence of both refractive and non-refractive co-morbidities in several eyes in our studies, the sum exceeds 100%.) Among operated eyes, preoperative vision was strongly associated with the presence of co-morbidities: patients without coincident ocular disease were some 5 times as likely to have preoperative vision _ 6/60. Access to eye care, as indicated by having been fit for glasses (a service not currently offered by our program), was strongly protective against the presence of co morbidities in this cohort, with such persons having one third the odds of having an ocular co morbidity, after adjusting for age and gender. These glasses were largely for reading (Congdon NG, Rao SK, Fan H, et al. Visual function and post-operative care after cataract surgery in China: the Sanrao Study of Cataract Outcomes and Up-take of Services), and very few subjects brought their glasses to the postoperative examination, so it is unlikely that this effect was mediated through a reduction in refractive error, the most common co morbidity in operated eyes in this cohort.[17]

A principal aim of the current study was to identify strategies to reduce the impact of co morbidities. Although preoperative vision was strongly associated with the presence of co morbidities, 86% of subjects were blind in the operative eye before surgery, so a

strategy of not operating on subjects with poor vision would be ineffective and undesirable in this program. Similarly, though access to eye care outside of our program, as indicated by having been fit for glasses, had a protective effect on co morbidities in this cohort, only 40% of our subjects had ever received glasses (Congdon NG, Rao SK,) Fan H, et al. Visual function and post-operative care after cataract surgery. In this setting, regular access to eye care is unlikely to be available for the majority of patients.[13]

The study conducted at china however; provide the basis for a program strategy to reduce the burden of ocular co morbidity: over 30% of operated eyes had co morbidities amenable to treatment, with some 40% of eyes with any co morbidities having at least one treatable condition. Programs to provide supplementary training in the recognition and treatment of common co morbidities could be expected to have a significant effect on visual outcomes in this program, given that 67% of eyes with best-corrected postoperative vision 6/18 had ocular co morbidity as a contributing reason. It is also important to remember that many of the co morbidities detected, such as most cases of glaucoma, may have no effect on central vision currently, but can severely impact vision eventually if untreated. According to the observed distribution of co morbidities in the current study, training programs should focus principally on diabetic retinopathy, OAG, and closed-angle glaucoma and would thus be expected to cover gonioscopy, management of the narrow angle, techniques of retinal examination, and laser treatment for proliferative retinopathy and edema.[13]

Refractive error accounted for 72% of the eyes failing to achieve 6/18 acuity. We report elsewhere that the proportion of patients in this setting who had refraction within _1 D of the target (_0.50 D) was 73.2%, well within international norms. Despite this, modest refractive error was quite common, though patient willingness to accept spectacles was low. Among the 87% of patients who could improve by _2 lines in the operated eye at near or distance with spectacles, only 35% of such persons would accept spectacles, the key reason being lack of perceived need. Visual function and postoperative care after cataract surgery in rural China: the Sanrao Study of Cataract Outcomes and Up-take of Services (SCOUTS). Efforts to redress the co morbidity of refractive error will probably need to focus on educational efforts emphasizing the visual benefits of wearing glasses.[12]

The results of this study must be interpreted in the context of the limitations of SCOUTS. Not all persons eligible for interview and examination as part of the cohort operated during the study period could actually be contacted, so it is at least possible that those examined were not representative of all persons operated at Sanrao, let alone of persons undergoing cataract surgery elsewhere in rural Asia.[15]

It is known, however, that examined and contacted subjects did not differ from one another with regard to a number of critical demographic and clinical factors. Although all subjects underwent thorough examination by an experienced glaucoma specialist, VF tests and other ancillary examinations were not performed as part of the SCOUTS protocol. Thus, it is quite possible that the figures given here represent an underestimate of the true burden of co morbid ocular disease. However, the current research was designed to elucidate the scope and impact of co morbidities potentially detectable by a well-trained ophthalmologist in a modestly equipped rural hospital, and not to constitute a prevalence study. Despite its limitations, the current study remains one of the few to give information on the burden of ocular co morbidities among cataract-operated persons in rural areas.

CONCLUSION

Ocular co morbidities are highly prevalent among persons undergoing cataract surgery in this rural area setting, and their presence is significantly associated with poorer visual outcomes. The fact that the great majority of co morbidities encountered in this program are treatable suggests that strategies to reduce their impact can be successful.

REFRENCES

1. Foster A, Resnikoff S.The impact of Vision 2020 on global blindness. Eye 2005;19:1133–5
2. Polack S, Kuper H, Wadud Z, Fletcher A, Foster A. Quality of life and visual impairment from cataract in Satkhira district, Bangladesh. Br J Ophthalmol 2008;92:1026-30
3. Mehmet B, Abuzer G.Results of Cataract Surgery in the Very Elderly Population. J Optom 2009;2:138-141
4. Krajcova P, Chynoransky M, Strmen P. Posterior capsule opacification following the implantation of various types of IOL-part II. Different intraoperative findings. Cesk Slov Oftalmol 2008;64:13-5
5. Malik AR, Qazi ZA, Gilbert C. Visual outcome after high volume cataract surgery in Pakistan. Br J Ophthalmol. 2003 ; 87: 937–40
6. Naeem M, Khan A ,Khan MZ, Adil M, Abbas SH,et al. Cataract: trends in surgical procedures and visual outcomes; a study in a tertiary care hospital. J Pak Med Assoc. 62: 209; 2012
7. Pham TQ,Wang JJ, Rochtchina E, Franzco AM, Franzco PM. Systemic and ocular comorbiditity of cataract surgical patients in a western Sydney public hospital. Clin Experiment Ophthalmol 2004;32:383–7
8. Noertjojo K, Mildon D, Rollins D, Law F, Blicker J, et al. Cataract surgical outcome at the Vancouver Eye Care Centre: can it be predicted using current data? Can J Ophthalmol 2004;39:38–47
9. Liu Y, Congdon NG, Fan H, Zhao X, Choi K, et al. Ocular Co-morbidities among Cataract-Operated Patients in Rural China. Ophthalmology 2007;114:e47–e52
10. Wang J, Fong CS, Rochtchina E. Risk of age related macular

degeneration 3 years after cataract surgery:Paired eye comparisons. Ophthalmology 2012;119:2298–2303
11. Arevalo JF, Garcia-Amaris RA; Intravitreal bevacizumab for diabetic retinopathy. Curr Diabetes Rev. 2009 ; 5: 39-46.
12. David Y. Cataract complications. Community Eye Health. 2008;21:1–3.
13. Z Jadoon SP, Bourne B, Khan M. Cataract prevalence, cataract surgical coverage and barriers to uptake of cataract surgical services in Pakistan: the Pakistan National Blindness and Visual Impairment Survey. Br J Ophthalmol. 2007;91:1269–73.
14. Fletcher AE, Ellwein LB, Selvaraj S. Measurements of vision function and quality of life in patients with cataracts in southern India: report of instrument development. Arch Ophthalmol 1997; 115:767–74.
15. Zhou ZX, Congdon N, Zhang ZM. Distribution and visual impact of postoperative refractive error after cataract surgery in rural China: the Study of Cataract Outcomes and Up-take of Services (SCOUTS), report #4. J Cataract Refract Surg. In press.
16. Guzowski M, Rochtchina E, Wang JJ, Mitchell P. Refractive changes following cataract surgery: the Blue Mountains Eye Study. Clin Experiment Ophthalmol 2002; 30:159–62.
17. Cook CD, Stulting AA. Prevalence and incidence of blindness due to age related cataract in the rural areas of South Africa. S Afr Med J. 2001;85:26-7.

Leptospira interrogans inflammation, hyphema in leptospirosis

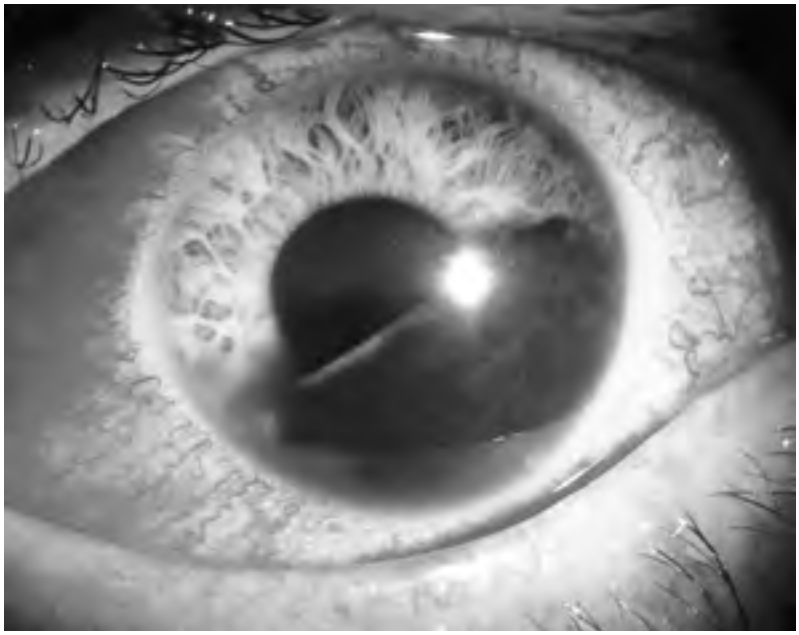

A 33-year-old farmer complained of sudden blurred vision, pain, redness, and photophobia in both eyes with a history of persistent fever (temperature, 39.4 C°) for the last 10 days, malaise, and body aches. Ophthalmologic examination revealed bilateral iridocyclitis. He was treated with prednisolone and eye drops which alleviated the pain and photophobia, but the next morning he had hyphema in the anterior chamber. Laboratory testing revealed a γ-glutamyl-transferase level of 129 U per liter (normal value, <55), an alanine Amino-transferase level of 49 U per liter (normal value, <45), and a white-cell count of 11,700 per cubic millimeter. Clinical and laboratory findings suggested a diagnosis of leptospirosis. Serologic tests revealed IgM and IgG antibodies against Leptospira interrogans. Hyphema is usually caused by ocular trauma, but in rare cases, it can be the result of infection. With continued local treatment and the addition of systemic treatment with amoxicillin, the patient's symptoms became less severe and his laboratory values and vision returned to normal within 2 weeks. The hyphema and eye redness resolved completely in 1 month.

Curtsey: Beate J. Langner-Wegscheider,
Robert Krause, M.D.
Medical University of Graz, Austria

Abdul Sami Memon

ORIGINAL ARTICLE

Comparison of Optical Coherence Tomography & Slit Lamp Biomicroscopy in detection of Diabetic Macular Edema

Abdul Sami Memon FCPS[1], Umair Qidwai FRCS, FCPS[2]

ABSTRACT

Aim: To compare accuracy of optical coherence tomography and slit lamp biomicroscopy in detection of diabetic macular edema.

Methods: It was an observational case series, carried out at Al-Ibrahim Eye Hospital, Karachi from August 2011 to November 2012. Patients with mild non proliferative diabetic retinopathy on fundus were included in the study, they underwent biomicroscope slit lamp examination and fundoscopy using 90 diopter condensing lens followed by macular scan through optical coherence tomography. 2x2 tables were uses for statistical analysis of the results of biomicroscope slit lamp examination with 90 diopter and with macular scans by OCT.

Results: 142 eyes of 85 patients were included in the study according to the inclusion and exclusion criteria. The probability of correct diagnosis of diabetic macular edema by slit lamp examination was 61.68%. the accuracy of identifying diabetic macular edema in OCT was 71.12%.

Conclusion: Optical coherence tomography can detect diabetic macular edema even earlier than slit lamp biomicroscopy and thus prevent further visual deterioration by undergoing early treatment.

Keywords: Diabetic macular edema, optical coherence tomography, slit lamp biomicroscope.

INTRODUCTION

Diabetic retinopathy is one of the leading causes of blindness in the present world. The global prevalence for diabetic retinopathy is 34.6%,[1] and in Pakistan the prevalence is 15.7%.[2] in one hospital based study performed in our hospital in which we observed that diabetic retinopathy was the most frequent cause of referral of the patients to retina clinic, 38.8% of the patients had diabetic retopathy.[3] Among the causes of decreased vision in patients with diabetic retinopathy, diabetic macular edema is the most common. Global prevalence of diabetic macular edema is 6.81% while in our study conducted at our hospital it was we observed that 45 % patients of the diabetic retinopathy had clinically significant macular edema.[3] Diabetic macular edema is one of the indications of treatment in patients with diabetic retinopathy. When diabetic macular edema is treated early, better visual prognosis is expected.[4] Thus, early detection of diabetic macular edema is very important in preventing the vision loss due to diabetic macular edema. Early Treatment Diabetic Retinopathy Study Research Group established a criterion for clinical assessment of diabetic macular edema using biomicroscope slit lamp examination with 90 diopter lens. In last few years the advent of optical coherence tomography and its usefulness in the early detection of many ocular diseases such as glaucoma and macular edema cannot be denied. In this study we have compared the effectiveness of the clinical detection using slit lamp biomicroscope with 90 diopter lens with the optical coherence tomography. Thus, the better of two methods for earliest detection of diabetic macular edema can be used for early detection followed by treatment resulting in less visual impairment due to diabetic macular edema.

[1]Assistant Professor, Department of Pediatric Ophthalmology & Vitero Retina Al-Ibrahim Eye Hospital, Isra Postgradute Institute of Ophthalmology, Gaddap Town Malir Karachi 75040. [2]Clinical Fellow Ophthalmology / Oculoplastics, Department of Ophthalmology, Institute of James Paget University Hospital, U.K.

Correspondence: Dr. Abdul Sami Memon, Assistant Professor, Pediatric Ophthalmology & Vitero Retina, Al-Ibrahim Eye Hospital, Isra Postgradute institute of Ophthalmology, Gaddap Town, Malir, Karachi-75040. Email: drabdulsami@hotmail.com Cell: 0321-8221172, 0321-2417913

Received: April 2015 Accepted: May 2015

The significance of slit lamp examination in diagnosing diabetic macular edema cannot be denied but with the advent of OCT we can detect diabetic macular edema even earlier than slit lamp biomicroscopy, thus preventing further visual deterioration by undergoing early treatment.

MATERIALS AND METHODS

The study was carried out at Al-Ibrahim Eye Hospital, Karachi from August 2011 to November 2012. Ethical approval was taken from the Ethical Committee Al-Ibrahim Eye Hospital, Karachi. It was an observational case series and non-probability purposive

sampling. Patients with mild non proliferative diabetic retinopathy on fundus examination (according to ETDRS study), [4]either gender were included in the study, while patients having moderate, severe non proliferative diabetic retinopathy or proliferative diabetic retinopathy or patients having other media opacities that might hinder the clear fundus examination such as cataract or corneal opacity were excluded from the study. Informed written consent was taken from every patient included in the study. The patients included underwent a detailed ocular examination by a senior Ophthalmologist, which included visual acuity assessment, refraction, best corrected visual acuity assessment, and biomicroscope slit lamp examination and fundoscopy using 90 diopter condensing lens. Every patient afterwards underwent macular scan through optical coherence tomography. Data was collected in preformed proforma. Statistical analysis was done by SPSS version 20.0. Frequencies and percentages were calculated for gender and eyes involved. Mean +/_ Standard deviation were calculated for qualitative variables like age. 2x2 tables were used for statistical analysis of the results of biomicroscope slit lamp examination with 90 diopter and with macular scans by OCT.

2x2 table for calculation of accuracy

Macular scan with optical coherence tomography(OCT)		Macular edema present	Macular edema absent
Biomicroscope slit lamp examination with 90 d lens	Macular edema present	A =66	B = 0
	Macular edema absent	C= 41	D=35

Accuracy of SLE in DME diagnosis = A+D / A+B+C+D
True positive rate DME = A / A+C
+SLE=slit lamp examination
DME= Diabetic macular edema

RESULTS

42 eyes of 85 patients were included in the study according to the inclusion and exclusion criteria. Out of these 85 patients, 47 (55.29%) were males while 38 were females (44.70%). Mean age of the patients was 52.07 (standard deviation=5.54) with minimum age of 39 years and maximum age of patients was 67 years. Out of 142 eyes, diabetic macular edema was seen in both optical coherence tomography and slit lamp examination is in 66 (47.48%) patients and in optical coherence tomography only in 41 (28.87%) of the patients. In 35 (24.65%) of the patients, diabetic macular edema was not seen in either optical coherence tomography nor in slit lamp examination is. 2x2 chart is shown in table-1. The probability of correct diagnosis of diabetic macular edema by slit lamp examination is is 61.68%, the accuracy of identifying diabetic macular edema in slit lamp examination is 71.12%.

Figure: 1 Comparision of assesment with SLE and Oct



TABLE-1 2x2 table for calculation of accuracy

Macular scan with optical coherence Tomography (OCT)		Macular edema present	Macular edema absent
Biomicroscope slit lamp examination with 90 D lens	Macular edema present	A (macular edema present in both sle+ and OCT)	B (macular edema present in sle+ only)
	Macular edema absent	C (macular edema present in OCT only)	D (macular edema absent in both sle+ and OCT)

Accuracy of SLE in DME diagnosis = A+D / A+B+C+D = 66+35 / 142 = 71.12%
True positive rate DME = A / A+C = 66 / 66+41 = 61.68%

DISCUSSION

Although slit lamp biomicroscope can detect diabetic macular edema satisfactorily but detection of diabetic macular edema using optical coherence tomography is much more accurate. Thus, optical coherence tomography can help in the detection of diabetic macular edemas that are not even visible clinically using slit lamp biomicroscope and so help in early detection of diabetic macular edema and thus prevent decrease in vision by offering early treatment. Our study shows that the accuracy of diagnosing diabetic macular edema using optical coherence tomography is much greater than slit lamp biomicroscopic examination. Some other studies have shown similar results as well. Afef Maalej reported the very high sensitivity of optical coherence tomography in diagnosing diabetic macular edema (98.6%).5They

also reported that optical coherence tomography can also help identify other associated features such as epiretinal membrane or vitreomacular traction that may be aggravating the diabetic macular edema. 5Another study by David J. Browning, they compared the diagnosis of diabetic macular edema (DME) by stereoscopic slit-lamp biomicroscopic examination of the fundus with a 78-diopter noncontact lens with diagnosis by optical coherence tomography (OCT) and showed that the clinical detection of diabetic macular edema was less than detection by OCT.6 Michael R. H also showed the significance of OCT in diagnosing the diabetic macular edema over slit lamp examination techniques. The main limitation of our study was that it was conducted in a single centre and that only single racial background patients were included in the study.

CONCLUSION

The significance of slit lamp examination in diagnosing diabetic macular edema cannot be denied but with the advent of optical coherence tomography we can detect diabetic macular edema even earlier than slit lamp biomicroscopy and thus prevent further visual deterioration by undergoing early treatment.

REFRENCES

1. Yau JW, Rogers SL, Kawasaki R, Lamoureux EL, Kowalski JW, Bek T, Chen SJ,et al. Global prevalence and major risk factors of diabetic retinopathy. Diabetes Care. 2012 Mar;35(3):556-64. doi: 10.2337/dc11-1909. Epub 2012 Feb 1.
2. Jamal-u-Din, Qureshi MB, Khan AJ, Khan MD, Ahmad K. Prevalence of diabetic retinopathy among individuals screened positive for diabetes in five community-based eye camps in northern Karachi, Pakistan. J Ayub Med Coll Abbottabad. 2006 Jul-Sep;18(3):40-3.
3. Aimal K, Qamar R. Fayaz S. Qidwai U "Frequency and Patterns of Eye Diseases in Retina Clinic of a Tertiary Care Hospital in Karachi", Pak J Ophthalmol 2011, Vol. 27 No. 3
4. Early Treatment Diabetic Retinopathy Study Research Group.Photocoagulation for diabetic macular edema: Early Treatment Diabetic Retinopathy Study report number 1. Arch Ophthalmol.1985;103:1796–806.
5. Afef Maalej, Wathek Cheima, Khallouli Asma, Rannen Riadh and Gabsi Salem.Optical Coherence Tomography for Diabetic Macular Edema: Early,Diagnosis, Classification and Quantitative Assessment. J Clinic Experiment Ophthalmol 2012. Special Issue: Ocular Diseases: Immunological and Molecular Mechanisms
6. David J. Browning. Michael D. McOwen. Robert M. Bowen. Tisha L. O'Marah.Comparison of the Clinical Diagnosis of Diabetic Macular Edema with Diagnosis by Optical Coherence TomographyOphthalmology 2004;111:712–715
7. Michael R. H. Carmen A. P. Jay S. D.Elias R.Jeffrey G. C.Jason R. W. et al. Topography of Diabetic Macular Edema with Optical Coherence Tomograph. Ophthalmology. 1998 February; 105(2): 360–370.

آج بھی ہو، جو ابراہیم کا ایمان پیدا
آگ کر سکتی ہے اندازِ گلستاں پیدا

کافر کی یہ پہچان کہ وہ آفاق میں گم ہے
مومن کی یہ پہچان کہ گم اس میں ہے آفاق
اقبالؔ

Sadia Bukhari

ORIGINAL ARTICLE

Ahmed Glaucoma Valve - Implantation in Children with Refractory Glaucoma, Success & Complications

Sadia Bukhari FCPS[1], Israr Bhutto FCPS[2], Riffat Ghazala FCPS[3]
Umair Qidwai FCPS, FRCS[4], Abdul Sami Memon FCPS[5]
Muhammad Faisal Fahim M.Sc[6]

**Department of Pediatric Ophthalmology, Al-Ibrahim Eye Hospital,
Isra Postgradute Institute of Ophthalmology, Gaddap Town, Malir, Karachi 75040**

ABSTRACT

Purpose: To evaluate the efficacy of Ahmed glaucoma valve (AGV) in children with refractory Glaucoma.

Materials & Methods: This prospective study was carried out at Pediatric Ophthalmology Department Al-Ibrahim Eye Hospital between July 2013 to June 2014. 24 eyes of 21 patients under 16 year of age were included in the study. The main outcome measure was control of intraocular pressure (IOP) without additional medication or surgery and without serious complications like loss of vision. IOP control was defined as IOP of less than 20mmHg and more than 5mmHg at minimum follow up of 6 months post AGV implantation.

Results: After Ahmed valve implantation, most of the patients, 17(70.8%) had no complications reported, while 3 (12.5%) had choroidal detachment and early hypotony. Mean IOP before Ahmed valve implantation was 38.21mmHg ± 7.962, with minimum IOP of 26 mm Hg and maximum IOP of 50 mm Hg. On first follow up after Ahmed valve surgery, mean IOP reduced to 6.87 mm Hg ± 3.25, with minimum IOP of 2 mm Hg and maximum IOP of 16 mm Hg. Final IOP during follow up period was 12.67 mm Hg ± 5.46 with minimum IOP of 8 mm Hg and maximum IOP of 32 mm Hg. Two patients had failed device with IOP rise and need further surgery.

Conclusion: AGV is an effective and relatively safe method in treatment of refractory Glaucoma in children.

INTRODUCTION

Pediatric glaucoma constitutes a group of diseases characterized by raised intraocular pressure with optic nerve damage. It may result from an intrinsic disease or structural abnormality of the aqueous outflow pathway (primary Glaucoma) or from abnormalities affecting other regions of eye (secondary glaucoma). Pediatric glaucoma is a potentially blinding disease which does not respond adequately to medical treatment. It accounts for about 18% of blindness in blind institutes and 5% of overall pediatric blindness worldwide.[1,2.] In US the incidence of pediatric glaucoma was 2.29/100000.[3] Primary congenital glaucoma is the most common type of glaucoma seen in pediatric population.[4.] Other common causes include post traumatic angle recession, after cataract surgery (pseudophakia, aphakia), post uveitic, Struge Weber syndrome, aniridia and anterior segment dysgenesis. Surgical intervention is the treatment of choice for glaucoma in pediatric age group. Angle surgery (goniotomy and trabeculotomy) are associated with good early success rate, eventually 20% of these patients require additional surgery to control IOP.[5,6,7]

Other surgical procedures are trabeculectomy with or without adjunctive antimetabolites, combined trabeculectomy- trabeculotomy, drainage devices and cyclo-destructive procedures. Trabeculectomy with mitomycin-C has shown success rate varying from 50-95%.[8] However use of these anti-metabolites has also resulted in long term complications such as bleb leak, bleb failure and endophthalmitis.[9,10]

Ahmed glaucoma valve (new world medical inc. Rancho Cucamonga, California) is a tube shunt device with unidirectional flow restrictive mechanism to decrease early post-operative hypotony. The valve mechanism consists of 2 thin silicon elastomer membranes which allows one way regulation of flow with a goal of keeping the IOP between 8-10mm Hg in early post-operative period. The success rate of AGV in childhood glaucoma ranges from 58-93% in mixed variety of childhood glaucoma including PCG, aphakic or pseudophakic glaucoma, uveitic glaucoma, sturge weber syndrome, aniridia and anterior segment dysgenesis.[11,12,13,14]

[1]Associate Professor, Pediatric Ophthalmology. [2,4,5]Assistant Professors. [3]Senior Registrar
[6]Statistician, Research Department

Correspondence: Dr. Sadia Bhukhari, Associate Professor, Pediatric Ophthalmology, Al-Ibrahim Eye Hospital, Isra Postgradute institute of Ophthalmology Gaddap Town Malir Karachi 75040, Email: drsadiabukhari@gmail.com & drabdulsami@hotmail.com Al-Ibrahim Eye Hospital, Isra Postgradute institute of Ophthalmology Gaddap Town, Malir Karachi-75040. Mobile: 0321-8221172, Phone: 0213-34560708 House: 588, St:2, DOH-1, Malir Cantt, Karachi. Cell: 0321 -2417013

Received: March 2015 Accepted: April 2015

The aim of this study is to evaluate the efficacy of AGV in refractory pediatric glaucoma including PCG with at least one failed drainage surgery, angle dysgenesis, aniridia, pseudophakic/aphakic glaucoma, post traumatic and uveitic glaucoma.

MATERIALS & METHODS

This was a prospective case series of patients under 16 years of age having refractory glaucoma that underwent AGV implantation from July 2013 to June 2014 at department of pediatric ophthalmology Al-Ibrahim Eye Hospital. All patients with primary congenital glaucoma (PCG) having failed drainage surgery once or twice, children with secondary glaucoma including pseudophakic or aphakic glaucoma, uveitic glaucoma and post traumatic glaucoma were included in the study. The patients in whom AGV was implanted as a primary procedure were not ***included*** in the study. Those patients who lost to follow-up or having follow-ups less than 6 months were also ***excluded*** from the study. The study was approved by Research Ethical committee (REC) of Isra Postgraduate Institute of Ophthalmology.

AGV is effective and relatively safe procedure in treatment of refractive pediatric glaucoma with low rate of serious short term complications.

Data was collected on a predesigned performa. Pre-operative data include age, sex, laterality of eye, cause of glaucoma, prior medical treatment, prior surgery and pre-operative IOP. Post-operative data include IOP measurement after 1 week, 1 month, 3 months and 6 months post-operatively. IOP measurements were taken with Goldman applanation tonometer in elderly children and Perkins tonometer in young children.

Intra-operative, immediate post-operative and late post-operative complications, additional anti glaucoma medications used were also recorded. Visual acuity was obtained at post-operative visits and final BCVA was recorded at 3-6 months post-operatively.

The primary outcome measure was defined as IOP less than 20mm Hg and more than 5mm Hg. Failure was established when IOP was outside the range at least in 6 months after AGV implantation or in the case of severe complications including loss of light perception, endophthalmitis, suprachoroidal hemorrhage, pupil block and phthisis bulbi.

Surgical Technique: The AGV was implanted in all patients under general anesthesia by a single surgeon. A fornix based flap of conjunctiva and tenon capsule was created in superior-temporal or superior-medial quadrant depending upon the scar of previous surgery. The valve was irrigated with balanced salt solution (priming) to ensure patency before fixing with sclera. Plate was sutured with sclera with the anterior edge of plate at least 8mm posterior to limbus using 5-(0) interrupted non absorbable prolene. A 6x8 mm^2 partial thickness limbal based scleral flap was made. The tube was trimmed so that it extends 1-2mm beyond the limbus. Anterior chamber paracentesis done by making port on nasal or temporal limbus and anterior chamber was formed with viscoelastic (sodium hyaluronate), anterior chamber was punctured with 15^0 knife at surgical limbus under partial thickness scleral flap and tube was inserted in anterior chamber with plain forceps.Scleral flap was sutured with 4x10 (0) nylon sutures and conjunctiva flap sutured with 8-(0) nylon sutures. Anterior chamber was irrigated and viscoelastic was removed and anterior chamber was formed with balanced salt solution.

Post-operatively all patients were put on topical antibiotic Vagamox and steroid Maxidex drops for 6 weeks. Anti-glaucoma medications were removed. Patients were examined at 1^{st}post-operative day, after 1week, 2weeks, 1month, 3month and 6months whenever required patients were examined under general anesthesia. On every follow-up all the parameters were documented.

Statistical Analysis: Data was analyzed through the software statistical package for social sciences (SPSS) Version 20.0. All the categorical variable were presented in frequencies and percentages. To check the difference between the IOP's we used paired sample T-test.

P-value < 0.05 considered to be statistically significant.

RESULTS:

Mean age of the patients was 7.5 ± 3.72 years with minimum age of 3 years while maximum age was 15 years. Out of 21 patients, 13 (66.7%) were male and 8 (33%) were female. Right eye surgery was done in 12 (50%) eyes and rest of the 12 (50%) had it in left eye. Among the reasons leading to Ahmed Valve implantation, primary trabeculectomy failure was most common, 10 (41.7%) eyes had failed trabeculectomy after primary congenital glaucoma.

Secondary glaucoma due to ocular trauma is highly resistant to traditional trabeculectomy procedures thus Ahmed Valve was implanted in 5 (20.8%) of eye with secondary glaucoma due to blunt trauma. Anirdia was also a common reason for failed trabeculectomies, thus 4 (16.7%) had Ahmed valve as their primary glaucoma surgery. 3 (12.5%) eyes had secondary glaucoma due to uveitis. 1 (4.2%) of eyes each had aphakic and pseudophakic glaucoma.

After Ahmed valve implantation, most of the patients, 17(70.8%) had no complications reported, while 3 (12.5%) had choroidal detachment. Table-1 Mean IOP before Ahmed valve implantation was 38.21mm hg ± 7.962 , with minimum IOP of 26 mm Hg and maximum IOP of 50 mm Hg. On first follow up after Ahmed valve surgery, mean IOP reduced to 6.87 mm Hg ± 3.25, with minimum IOP of 2 mm Hg and maximum IOP of 16 mm Hg. Final IOP during follow up period was 12.67 mm Hg ± 5.46 with minimum IOP of 8 mm Hg and maximum IOP of 32 mm Hg. See graph 1 for comparison of means.

Figure 1: Comparison of IOP between pre-Operative IOP and Post operative IOP



***P-value < 0.05 considered to be statistically significant.**

Table 1: Early Complications after Ahmed Glaucoma Valve Implantation Surgery

Complications	n (%)
None	17 (70.8%)
Choroidal Detachment	3 (12.5%)
Early hypotony	1 (4.2%)
Shallow A/C Cataract	1 (4.2%)
Macular Edema Pucker	1 (4.2%)
Tube block with inflammatory membrane	1 (4.2%)
Total	24 (100%)

***Data were presented in Frequency and percentages.**

Table 2: Final Post-Operative complications

Final Post-Operative complications	n (%)
Cataract	1 (4.2%)
Macular pucker	1 (4.2%)
None	20 (83.3%)
Raised IOP	2 (8.3%)
Total	24 (100%)

***Data were presented in Frequency and percentages.**

Figure 2: Success Rate



DISCUSSION

Pediatric glaucoma not only includes primary congenital glaucoma but also secondary glaucoma such as pseudophakic or aphakic glaucoma, anterior segment dysgenesis, anaridia and post traumatic glaucoma. The safety and efficacy of glaucoma drainage devices in pediatric glaucoma have been reported.[11, 12,13,14,15,16]. Although glaucoma drainage devices shows good success in childhood glaucoma it is difficult to compare success rate of surgery as the studies vary according to population studied, lengths of follow-up and type of device implanted. In a retrospective case series by O'Malley Schotthoefer et al[17] success rate at 1 year was 92% and 90% in the congenital and aphakic glaucoma groups respectively but fell by 10 years to 42% and 55% respectively. Other study by Morad et al[14] reported 93% success rate of AGV in pediatric glaucoma at 12 months follow-up. Andrew Chen et al reported success rates at 1 and 10 years for all patients were 87.5% and 34.1% respectively, mean IOP was reduced from 29.3mm Hg pre-operatively to 16.6 and 15.0mm Hg after 1 and 10 years post-operatively[18]. Another studyby J C Das

et al., from India the mean IOP in pediatric sub-group was reduced from pre operative mean of 32.4± 4.5 to 16.60± 4.4mm Hg at 24 months post-operatively with an overall success rate of 85.2% at 12 months and 82.1% at 24months[19]. Our short term study shows success rate of 91% with mean IOP reduction of 25.54 mm Hg at 6 months follow-up.

The most common post-operative complication reported in literature after Ahmed Glaucoma Valve are tube related complications like tube retraction, tube corneal touch, valve plate extrusion and tube blockage[20,21,22,23]. We have not come across through these complications although one patient had tube blockage with inflammatory membrane and raised IOP on final follow-up which needs further surgery. In literature the reported incidence of tube blockage is between 0% to 14% after AGV [24,25,26,27,28]. One of our patient with total aniridia had tube-lens touch and formation of cataract. Tube erosion has been reported in pediatric glaucoma. Tube exposure after conjunctival erosion in AGV is major risk factor for development of end ophthalmitis[29]. In our short term follow-up of 6 months we have no case with post-operative endophthalmitis. The most common complication that we have encountered in our patients is choroidal detachment which was seen in 3(12.5%). Hypotony was seen in early-postoperative period was completely resolved in 6 weeks. All patients with hypotony were managed conservatively. The reported incidence of hypotony following AGV ranges from 11% to 42%[12,14,20,30]. One patient had macular edema in early postoperative period which ultimately leads to macular pucker formation and significant drop in visual acuity although IOP was 10mm Hg on last follow-up. Other severe complications like choroidal hemorrhage, loss of vision and phthisis bulbi were not noted in our patients.

CONCLUSION:

AGV is effective and relatively safe procedure in treatment of refractive pediatric glaucoma with low rate of serious short term complications.

Conflict of interest: There was no conflict of interest between the authors.

REFERENCES

1. Gilbert CE,Canvos R, Kocksch de Canovas R, Foster A. Causes of blindness and severe visual impairment in childrenin chili. Dev.Med.Child Neurol.1994.36 326-333.
2. Gilbert, C.E., Rahi, J.S., Quinn, G.E., 2003. Visual impairment and blindness in children. In: Johnson, G.J., Minassian, D.C., Weale, R.A., West S.K. (Eds). The Epidemiology of Eye Disease, second-ed., Arnold, London, pp. 260-286.
3. Aponte, E.P., Diehl, N., Mohney, B.G. Incidence and clinical characteristics of childhood glaucoma: a population-based study. Arch ophthalmology 2010; 128(4): 472-482.
4. Taylor, R.H., Ainsworth, J.R., Evans, A.R., Levin, A.V. The epidemiology of pediatric glaucoma: the Tornoto experience. J. AAPOS 1999(3), 308-315.
5. Anderson DR. Trabeculotomy compared to goniotomy for glaucoma in children. Opthalmology. 1983:90(7):805-806.
6. deLuise VP, Anderson DR. Primary infantile glaucoma (congenital glaucoma). Surv Opthalmol. 1983:28(1):1-19.
7. Tanimoto SA, Brandt JD. Options in pediatric glaucoma after angle surgery has failed. Curr Opin Opthalmol. 2006:17(2):132-137.
8. Tanaka S. (Medical Editor) American Academy of Ophthalmology Section 6 Paedriatic Ophthalmology and Strabismus 2008-2009 : Peadriatic Glaucoma page 281 Publisher LEO.
9. Beck AD,wilsonWR, LynchMG,LynnMJ, NoeR,Trabculectomy with adjunctive mitomycin –C in pediatric glaucoma. Am j ophthal 1998:126(5)648-657.
10. Sidoti PA,Belmonte SJ, Leibmann JM, Ritch R. Trabeculectomy with mitomycin-c in treatment of pediatric glaucomas. Ophthalmology 2000:107(3)422-429.
11. Coleman AL, Smyth RJ, Wilson MR, Tam M. Initial clinical experience with the Ahmed Glaucoma Valve implant in pediatric patients. Arch Ophthalmol. 1999:127(1):34-42
12. Englert JA, Freedman SF, Cox TA. The Ahmed vavle in refractory pediatric glaucoma Am J Ophthalmol. 1999:127 (1):34-42.
13. Djodeyre MR, Peralta Calvo J, Abelairas Gomez J. Clinical evaluation and risk factors of time to failure of Ahmed Glaucoma Valve implant in pediatric patients. Ophthalmology. 2001:108(3):614-620.
14. Morad Y, Donaldson CE, Kim YM, Abdolell M, Levin AV. The Ahmed drainage implant in the treatment of pediatric glaucoma. Am J Ophthalmol. 2003:135(6):821-829.
15. Rodrigues AM, Corpa MV, Mello PA, de Moura CR. Results of the susanna implant in patients with refractory primary congenital glaucoma. J AAPOS. 2004:8(6):576-579.
16. Munoz M, Tomey KF, Traverso C, Day SH, Senft SH. Clinical experience with the Molteno implant in advanced infantile glaucoma. J pediatr Ophthalmol Strabismus. 1991:28(2):68-72.
17. O'Malley Schottheofer E, Yanovitch TL, Freedman SF. Aqueous drainage device surgery in refractory pediatric glaucomas. I: long-term outcomes . J AAPOS. 2008:12(1):33-39.
18. Andrew Chen, Fei Yu, Anne L Coleman etal. Ahmed glaucoma valves in pediatric glaucoma-10 year outcomes. Invest ophthalmol vis sci 2014:55:E-abstract 3184.
19. JC Das, Z Chaudhuri, P Sharma and S Bhomaj. The Ahmed Glaucoma valve in Refractory glaucoma:experiences in Indian Eyes. Eye(2005) 19, 183-190.
20. Coleman, A.L. Smyth, R.J., Wilson, M.R., Tam M. Initial clinical experience with the Ahmed glaucoma valve implant in pediatric patients. Arch. Ophthalmology 1997:115(2), 186-191.
21. Beck, A.D., Freedman, S., Kammer, J. Aqueous shunt devices compared with trabeculectomy with Mitomycin-C for children in the first two years of life. Am. J. Ophthalmology 2003. 136 (6), 994-1000.
22. Al-Mobarak, F., Khan, A.O. Two-year survival of Ahmed valve implantation in the first 2 years of life with and without intraoperative mitomycin-C. Ophthalmology 2009 116, 1862-1865.
23. Mullaney, P.B., Selleck, C., Al-Awad, A., et al. Combined trabeculectomy and trabeculotomy as an initial procedure in uncomplicated congenital glaucoma. Arch. Ophthalmol 1999 117, 457-460.
24. Rodrigues, A.M., Junior, A.P., Montezano, F.T., d Arruda Melo, P.A., Prata Jr. Comparison between results of trabeculectomy in primary congenital glaucoma with and without the use of mitomycin C.J. Glaucoma 2004 :13 (3), 228-232.
25. Roche, O., Beby, F., Parsa, A., Orssaud, C., Dufier, J.L., Parsa, C.F. Nonpenetrating external trabeculectomy fo congenital

glaucoma: a retrospective study. Ophthalmoloy 2007: 114 (11), 1994-1999.
26. Netland, P.A., Walton, D.S. Glaucoma drainage implants in pedraitic patients. Ophthalmic Surg. 1993: 24, 723-729.
27. Donahue, S.P., Keech, R.V., Munden, P., Scott, W.E. Baerveldt implant surgery in the treatment of advanced childhood glaucoma. J AAPOS 1997: 1, 41-45.
28. Hamush, N.G., Coleman, A.L., Wilson, M.R. Ahmed glaucoma valve implant for management of glaucoma in Sturge-Weber syndrome. Am. J. Ophthalmol. 1999: 128, 758-760.
29. Al-Torbak, A.A., Al-Shahwan, I., Al-Hommadi, A., Edward, D.P. Endophthalmitis associated with the Ahmed glaucoma valve implant. Br. J. Ophthalmol. 2005 : 89, 454-458.
30. Djodeyre, M.R., Peralta Calvo, J., Abelairas Gomez, J. Clinical evaluation and risk factors of time to failure of Ahmed glaucoma valve implant in pediatric patients. Ophthalmology 2001; 108, 614-620.

Becker's Nevus

A healthy 15-year-old boy presented to the dermatology clinic with an area of pigmentation on his chest and present since childhood. During puberty it became darker and developed hair. Examination revealed a well-demarcated tan-colored patch covered with coarse dark hairs, spanning his upper chest and extending onto the right shoulder and back. Physical examination was otherwise unremarkable. A clinical diagnosis of Becker's nevus was made. It is a benign nevoid hypermelanosis, characterized by a circumscribed hyperpigmented patch with an irregular edge. Overlying hypertrichosis frequently develops several years later. The lesion typically develops on the upper trunk, shoulders, or upper arms of adolescent males. Becker's nevi are generally asymptomatic, and no treatment is usually required.

D.D. Becker's nevus, Hypomelanosis of Ito, Mongolian spots, Neurofibromatosis, Speckled lentiginous nev

Curtsey: Lindsey R. Baden, M.D., Editor, Muriel Sadlier, M.B. Grainne M. O'Regan, M.D.
Adelaide and Meath Hospital Dublin, Ireland

Bilal Khan

ORIGINAL ARTICLE

Visual Improvement after Penetrating Keratoplasty in Corneal Scars

Bilal Khan FCPS[1], Ashfaq ur Rehman FCPS[2], Arif Khan FCPS[3]
Muhammad Idrees FCPS[4], Adnan Alam MBBS[5]

ABSTRACT

Objectives: To determine the visual improvement after penetrating keratoplasty in corneal scars of healed corneal ulcers.

Methodology: This was a hospital based descriptive cross sectional study at department of Ophthalmology, Hayatabad Medical complex, Peshawar from 15th October, 2011 to 15th June 2013 having total 1 year and 9 months duration. All those patients were ***included*** in the study in which penetrating keratoplasty for corneal scars of healed corneal ulcers having both genders having age limit: 15-60 years and base line visual acuity of ≤ 6/36 on Snellen's vision chart while those patients having active anterior segment infections, adnexal lesions, associated glaucoma with intraocular pressure of > 21 mm Hg measured by Goldmann applantation tonometer, dry eye diseases, systemic disorders and history of chemical burns were ***excluded.*** Documentation were done on preformed proforma for age, gender, etiology of corneal ulcers, any variation in post visual acuity and post operative complication. Data was analyzed by SPSS 20 and represented in the form of charts and graphs.

Results: There were more males than females, 47 versus 17, with mean age of 30 years (ranging from 14-52). Of these 64 patients 82 % got visual improvement of better than two lines on snellen's visual acuity chart at 3rd month post operatively. Only 2 cases got graft rejection.

Conclusions: 82 % of patients got improvement of better than two lines on snellen's visual acuity chart after penetrating keratoplasty for healed corneal ulcers.

Key Words: Corneal scar, penetrating keratoplasty, healed coreal ulcers.

INTRODUCTION

Arthur von Hippal (1841-1916), in 1886 reported the first partly successful lamellar graft. Eduard Zirm (1863-1944), in 1905 performed the first successful full-thickness corneal transplant.[1] Corneal disease is one of the major causes of blindness worldwide, second after cataract in overall importance.[2] There is a large variation in prevalence of the different corneal diseases between countries and the etiology changes from country to country. There are multiple cause of corneal scars i.e., injuries or trauma bacterial infection, viral, fungal, parasitic or acanthamoeba, herpes simplex virus, conjunctivitis, scleritis, vitamin A deficiency and contact lenses. Similarly other causes which leads to the corneal ulcers these are interstitial keratitis, bacterial hypersensitivity-mediated corneal disease, Mooren's ulcer, peripheral ulcerative keratitis with systemic autoimmune disease. The prevalence of blindness in Pakistan is 0.9 %. Among the prevalent causes of blindness, corneal opacity is the second most common (11.8%) after cataract (51.5%). Corneal opacity may be due to trauma, dystrophies, degenerations or healed corneal ulcers.[3,4,5,6,7,8]

In the world, specifically in the developing countries keratoplasty is the procedure which is cost effective, with good outcome and successful. It needs corneal graft which is harvested on the place of corneal opacity. Keratoplasty can be classified into full thickness or penetrating keratoplasty (PK) and partial thickness or lamellar keratoplasty (LK). Similarly A corneal graft may consist of (a) partial-thickness (anterior or posterior lamellar) or (b) full-thickness (penetrating) keratoplasty (PKP).[9] Penetrating keratoplasty nowadays remains the most commonly performed corneal transplantation procedure, largely because lamellar surgery is difficult and time-consuming, and because interface irregularity can limit visual outcome.

Common indications are keratoconus, pseudophakic bullous keratopathy, Fuchs endothelial and other dystrophies.[10] Regarding donor tissue it should be removed as early as within 12–24 hours of death and prior to transplantation most donor corneas are stored in coordinating 'eye banks', for evaluation and can be stored[7] to 4 weeks depending upon the media provided. Various contra indications of ocular tissue donation like various systemic infections, neurodegenerative diseases Alzheimer disease and other dementias, like various haematological malignancies., brain or spinal surgery etc[7] regarding recipient factors several host factors are there that may

[1]Vitreo-retinal Resident Ophthalmology Department Lady Reading Hospital, Peshawar. [2]Medical Officer, Basic Health Unit, Hangu. [3]Assistant Professor Ophthalmology, PIMS, Islamabad. [4]Medical Officer, Lady Reading Hospital, Peshawar. [5]Medical Officer, Postgraduate Resident.

Correspondence: Dr. Bilal Khan Resident of Vitro retina section of Ophthalmology Department Lady Reading Hospital Peshawar. Cell: 0300-5981806, Email: drbilalokz@gmail.com

Received: March 2015 Accepted: May 2015

adversely affect the prognosis. In general, the most favorable conditions are keratoconus, localized scars and dystrophies conditions which have poor prognosis are active corneal inflammation, absence of corneal sensation, severe stromal vascularization and extreme thinning at the proposed host-graft junction site, Eyelids abnormalities such as blepharitis, ectropion, entropion and trichiasis, Progressive or recurrent forms of conjunctival inflammation, anterior synechiae etc.

Regarding post operative management, full-time eye protection should be done for the first 2 months is essential after penetrating keratoplasty. Eye glasses or sun glasses are worn during waking hours, and an eye shield is taped in place for naps and at bedtime. Activity is restricted within the constraints of the patient's lifestyle. We strongly suggest not straining or lifting objects heavy enough to induce a Valsalva maneuver for the first 2 months. No swimming is allowed for at least 1 month, but a full shower may be taken after the epithelium has healed completely often after the first week. Other ancillary treatment is provided in the form of antibiotics, cycloplegics, antivirals etc. post operative complications can occurs which are giant papillary hypertrophy, persistent epithelial defects, wound leak with iris prolapse and flat anterior chamber, elevation of intraocular pressure, astigmatism, recurrence of previous disease process, retro-corneal membrane formation, cystoid macular edema, corneal graft rejection etc. Treating the rejection as early as possible is essential as this greatly increases the chances of reversing the process of rejection. The most intensive and aggressive therapy is generally acquired for endothelial rejection followed by stromal, subepithelial and epithelial, in order of severity. The drugs which are used in it treatment are topical steroids, cycloplegiscs etc.[7,10,11,12]

Penetrating Keratoplasty is a safe and effective procedure with remarkable optical and visual outcomes for patients with corneal scars who have unacceptable corrected visual acuity.

MATERIAL AND METHODS

The study was conducted after approval from Hospital's Ethical and Research Committee. All patients meeting the inclusion criteria and presenting with corneal scar after healed corneal ulcer as per criteria mentioned in operational definition above, were included in the study through OPD and were admitted in the ward for further evaluation. The purpose and benefits of the study were explained to all patients and a written informed consent was obtained. All patients were worked up with detailed history and clinical examination followed by routine baseline pre operative investigations. All patients were subjected to standard penetrating keratoplasty by single experience ophthalmologist. Post operatively, all patients were followed up at 3rd month to determine the visual improvement on Snellen's chart. Strictly exclusion criteria was followed to control confounders and bias in the study results.

A proforma was designed and completed for all the patients. After the admission of a patient, detailed history was taken about the demographics , and patients complaints , etiology and prior treatment taken and then patients were subjected to thorough ocular examination including visual acuity, pupillary, anterior and posterior segment examination for each eye, examination of conjunctiva, cornea, anterior chamber , fundoscopy, slit lamp biomicroscopy with 78 D or 90 D lens or Goldmann three mirror was also done to look for glaucoma changes. All surgeries were done under peribulbar anesthesia. Manual trephines were used for all cases. In all cases, interrupted suturing with 10/0 nylon was done. Postoperatively, patients were given prednisolone acetate (1%) eye drops, topical antibiotics, and artificial tears. Topical steroids were tapered over with time. For post-herpetic cases, prophylactic oral acyclovir were started. We did not use systemic immunosuppressive. Routine follow-up schedule was 2 weekly for first month, then monthly till final visit at 3rd month. Selective sutures were removed at third month, after assessing laxity or tightness of sutures on slit lamp examination, and calculating astigmatism by retinoscopy and keratometry. Best corrected visual acuity was determined at postoperative 3rd month.

RESULTS

In my study, there were a total of 64 cases. In 39 patients left eye was operated and in 25 cases right eye was operated. All the patients were followed up at 3rd month postoperatively. The minimum age at which the patient presented was 18 years while the oldest patient was 48 years of age with a mean of 30 years and SD ±1.26. 37 (57.81%) patients presented in the age group of 21-30 years, making it the most common decade of presentation for patients with corneal scars. Details regarding age of our study population are given in Table I. Male gender was observed to be dominant (73.47%) as compared to the female gender (26.53%) in the patients included in the study (Figure. 1). The male to female ratio was 2.76:1. Of total 64 cases, 53 patients (82.81%) got visual improvement, 6 patients (9.37%) had no visual improvement while 5 patients (7.81%)

got worsened visual acuity. Out of these 64 patients, 40 patients (62.5 %) had visual improvement with best corrected visual acuity (BCVA) of better or equal to 6/18. 19 patients (29.68 %) had visual improvement with BCVA of better or equal to 6/60., and 5 patients (7.81%) had BCVA of less than 6/60. (Figure II).

Visual improvement was observed more frequently in the age group 16-20 years (n=4; 100 %) as compared to the other age groups (Figure III). Visual improvement was observed in 72.43% cases of all male patients as compared to the females 27.77 %. (Figure IV). 85.71 % of patients with preoperative baseline visual acuity of ≤ 6/60 showed visual improvement. (Fig V) . Bacterial corneal ulcers constituting 24 cases (37.5%) were the most common cause of corneal scars followed by etiology of unknown causes (21.87 %).Table II Most of the corneal scars (44 cases) were deep stromal obscuring the optical zones with more than 5mm in the diameters while in rest (20 cases) corneal scars were of less than 5mm in dimensions. 80 % of donor graft sizes were taken 7.75mm in diameter and in the rest of cases it were 7.50mm. Postoperative complications observed in patients in my study were, post operative astigmatism of more than ±3 DC were observed in 12 cases followed by secondary cataract formation and persistent epithelial defects in 3 cases each. Figure VI.

TABLE 1: Age distribution of patients N= 64

AGE DISTRIBUTION OF THE STUDY POPULATION		
Age (years)	**Frequency (n)**	**Percent (%)**
10-20	4	6.25
21-30	37	57.81
31-40	18	28.12
41-50	5	7.81
Total	**64**	**100.0**

Figure I: Gender Distribution of study population N=64

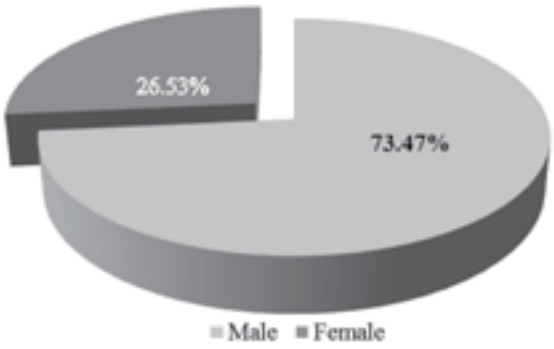

Fig II: Post-Op. Best visual acuity

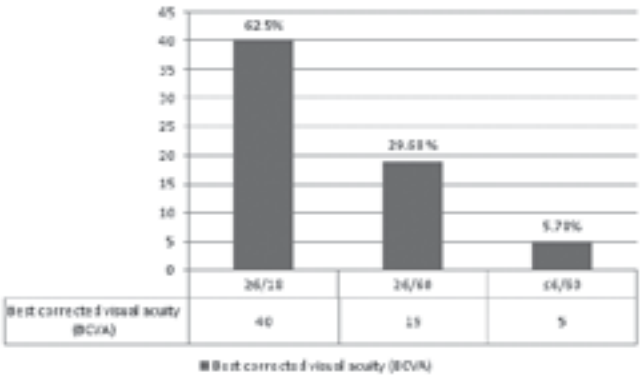

Figure III: postoperative visual outcome in different age group n=ii



Figure IV : Visual improvement based on gender N=64

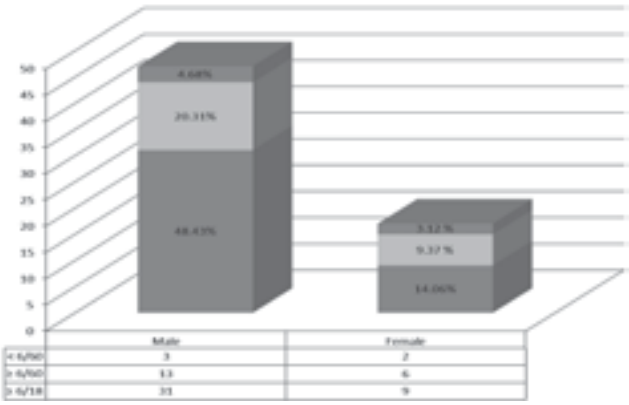

Figure V: Frequency of postoperative visual improvement N=64

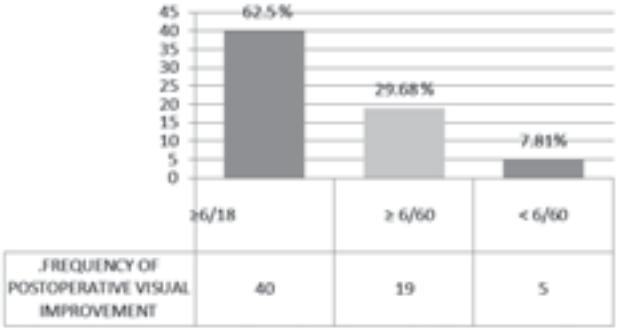

TABLE II: N=64

Etiology of corneal scars	Frequency (n)	Percentage (%)
Bacterial Ulcers	24	37.5
Viral Ulcers	8	12.5
Fungal Ulcers	9	14.0
Shield Ulcers	5	7.81
Post PRK	2	3.12
Post contact lens use	2	3.12
Unknown Causes	14	21.87

Fig VI: Post operative complications N= 64

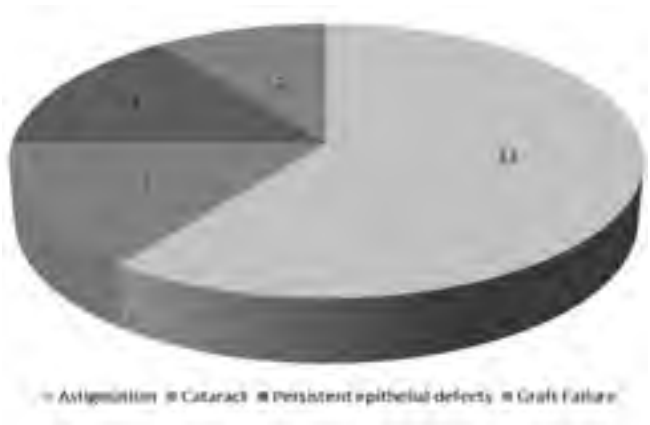

DISCUSSION

Among the prevalent causes of blindness, corneal opacity is the second most common (11.8%) after cataract (51.5%).[4] Corneal opacity may be due to trauma, dystrophies, degeneration or healed corneal ulcers. In the long term, effective strategies with a community-based comprehensive eye-care approach are required to deal with corneal blindness in Pakistan. Though this approach will take time to be established on a large scale. However, to deal with the current situation of corneal blindness in Pakistan, approaches to make visual rehabilitation feasible in these blind as large as possible are required. To restore visual acuity a corneal transplant procedure, is performed. It is the most successful of all tissue transplants and is done routinely in tertiary set ups. It can be either penetrating or lamellar, depending upon the entire thickness or superficial layer of the cornea to be removed and replaced by healthy corneal tissue.

Penetrating keratoplasty (PKP) is an effective treatment for corneal diseases with poor vision. The outcome of PKP depends upon indications, operative techniques and postoperative care. Reports from various graft registries of the developed countries show the indications for surgery being mainly keratoconus, other corneal dystrophies, followed by aphakic and pseudophakic bullous keratopathies.[13,14,15] However, the scenario in developing world is quite different. Firstly the patient profile and indications for surgery differ. In one local study leading indication of PKP was corneal scar 14 (46.7%) followed by keratoconus 09 (30%) and pseudophakic bullous keratopathy 04 (13.3%).[16] According to a study done in Nepal, corneal scars following infectious keratitis, adherent leucomas, and corneal perforations were the major indications for surgery.[17]

Corneal transplant surgery is the most commonly performed allograft and is said to be the most successful solid organ transplants, with short-term survival rates (1 year) as high as 90%.[18] However, the long-term success rate diminishes to 73% at 5 years, 60% at 10 years, and 46% at 15 years as reported in ACGR.[19] A study done in India to analyze survival rate of corneal transplants in a large series shows survival rates at 1, 2, and 5 years for first-time grafts to be 79.6%, 68.7%, and 46.5%, respectively.[20] They are different from the western studies essentially due to differences in patient profile, different indications for surgery, differences in methods of storage of donor corneas, and socio-economic factors affecting healthcare provision. Also, majority of our patients are illiterate, so postoperative care and follow up is a major challenge.

This study presents the results of 64 eyes of 64 patients who received corneal grafts at the Department of Ophthalmology, Hayatabad Medical Complex, Peshawar from 15th October, 2011 to 15th June, 2013.

The main aim of corneal grafting was to improve the vision and hence the degree of visual improvement was the index of success that was considered to be achieved when there is visual improvement of at least 2 lines on snellen's visual acuity chart after best corrected visual correction. There were more male patients 47 (73.47%) as compared to female patients17 (26.53 %). This trend is seen almost in any hospital set up in developed, developing or under developed countries where males are more exposed to various risk factors for corneal diseases and then have comparatively easy accessibility to health care due to various socio economic factors. 64 % of our patients were under the age of 30 years. This is mainly due to various etiological causes for scars like allergy, contact lens use and PRK that were related to this age group, along with socio economic and cultural factors, giving priority to young age.

Comparing survival and final visual acuity between studies is difficult due to difference in population size and follow-up time. Different studies have documented varying rates of survival 36–93%.[20,21,22,23,24,25,26,27,28,29,30] Specific indications for corneal transplantation, in particular KC and corneal dystrophies have comparatively high survival rates.[29,31]

In one local study conducted by Muhammad Nasir Bhatti, Yawar Zaman et al[16] Overall graft survival was 82% at the 3rd month follow-up compared overall graft survival in 61.0% cases with graft clarity in 78.6 % of cases in corneal scars at the final follow-up (mean 12.3 months). In another study by Randleman JB et al[32] 75% of the primary grafts remained clear with graft clearity in 66.7 % of cases having corneal scars at the averaged 21.9 months follow up .In my study 92.18% (59) of grafts were observed clear with graft survival in 96.87% (62) of cases at the 3rd month of follow up, which are far better results as compared with their study results. The reason for this difference might be that they had not adopted strict exclusion criteria with inclusion of various other indications for keratoplasty apart from corneal scars. Also, comparing with 3 months short follow up period in our study, they have analyzed their results after long follow up periods of almost 1 to 2 years.

In our study, a total of 53 patients (82.81%) got visual improvement , 6 patients (9.37%) showed no visual improvement while 5 patients (7.81%) got worsened visual acuity which is comparable with a local study conducted by Bakht Samar et al[33] that showed final visual acuity improvement in 76% of cases. In another study, Al Fawaz et al[34] showed that visual acuity was improved in 107 (84.3%) eyes, remained the same in 12 (9.5%) eyes, and worsened in 8 (6.3%) eyes. Wagoner et al[35] in their large data of 910 eyes also showed improvement in vision occurred in 750 (82.4%) eyes, remained the same in 97 (10.7%) eyes, and worsened in 63 (6.9%) eyes. In a study conducted by Saunders, Lyn M Sibley and his colleagues,[36] 69.9% of patients demonstrated improvement in visual acuity (operative eye) at the 12 month follow up. The results of my study are comparable and even better to results of these studies. Although, their results are based on the large data and prolonged study duration and follow ups. However, ours early follow up results and strict inclusion and exclusion criteria adopted in my study predict that the final outcome results would be comparable in long term as well.

In our study, 62.5% of patients had best corrected visual acuity (BCVA) of better or equal to 6/18 while 29.68% of patients had best corrected visual acuity (BCVA) of in between 6/24 to 6/60., and 7.81% of cases had BCVA of less than 6/60. In one local study [33] 11 (22%) treated eyes had visual acuity ≥ 6/18, 32 (64%) eyes had between 6/60 to 6/24 and 7 (14%) eyes had visual acuity of ≤ 6/60 at 12th month follow up. In another review study, P Beckingsale et al[37] found a best corrected visual acuity of 6/18 or better in 53% of cases at 5 years follow up in their large data of 784 cases. I Rahman et al[38] in their study observed visual improvement in 48% of patients with best-corrected Snellen's visual acuity (BCVA) of 6/12 or better 5 years postoperatively. Our results are comparable and better than their study regarding percentage of visual improvement which are expected for better outcome after stabilization of corneal wound and removal of sutures inducing astigmatism. Of the 6 cases having no visual improvement, 3 patients had developed early secondary cataracts and the rest 3 had underlying retinal pathology, with one having macular hole and the other two patients having cystoids macular edema. While 5 patients having worsened visual acuity post operatively, 3 had persistent epithelial defects and 2 having incidents of graft failure. These cases were then treated with amniotic membrane transplantation and regrafting respectively.

33 eyes (51.56%) were blind before corneal transplantation, whereas 6 eyes (9.37 %) were blind at 3 rd month of follow up that were far better results as compared to study carried out by Dandona L et al [49] where before corneal transplant 80.2% of the eyes were blind (visual acuity < 3/60), whereas at last follow up 41.8% eyes were blind. In this way, in our study we observed that 81.81 % (27 eyes) of all the 51.56% preoperative blind eyes (33 eyes) got visual rehabilitation at 3 months follow up of the procedure. Complications of PK have been regularly reported in the developed and indeed the developing world. In my study also penetrating keratoplasties were beset by few complications. Astigmatism was the most frequent complication that we encountered. High refractive errors with astigmatism of more than 3 diopters were recorded in 12 cases (18.75%) that is greater as compared with (13.7%) noticed by Bakht Samar et al in their study.[33] However, I noticed no case of glaucoma as compared to 37.5 % eyes noticed with glaucoma in their study. The reasons for such differences is our results are interpreted too early without any suture removed post operatively. Skeen et al[23] noticed incidence of secondary glaucoma in 8.8 % of cases while Fawaz et al noticed glaucoma in 27.6 % of cases during their 5 years study period.[38]

The reason for such differences is being the long study duration and long post operative follow up period in their studies. We did not find any relation between preoperative diagnosis and postoperative astigmatism. This confirms that various surgical factors such as trephination, corneal graft placement and suturing techniques are among the most important factors to determine the postoperative astigmatism. In my study

Persistent epithelial defects were recorded in 3 cases (4.68%) and 2 cases (3.12%) were observed with graft failure .These results are better than results obtained by Muhammad Nasir Bhatti and Yawar Zaman et al [33] in their study that had persistent epithelial defect in 04 (13.3%) and primary graft failure in 02 (6.7%). No clear association or reason was not found for 2 cases of corneal grafts failure in our analysis However, surface problems and increased intraocular pressure as causes of graft failure are potentially modifiable risk factors. While paying particular attention to look for the presence of these factors in corneal grafts at-risk and persuading aggressive treatment, it may be possible to reduce the chances of graft failure.

Rahman and Carley et al [38] noticed microbial keratitis (MK) in 16 grafts with an incidence of 7.9%. By the end of 3 months, no cases of microbial keratitis or recurrence were observed in our study, probably due to the fact that the corneal grafting was undertaken in the healed stage of disease with none of the microbial particles would have been left there in keratocytes of corneal stroma. Additionally, we attribute this success to indefinite use of oral antivirals postoperatively. Following initial dose of acyclovir 400 mg four times daily postoperatively, this was tapered over the next 12 months to 400 mg once daily in recipients had having post viral corneal scars. The incidence of endophthalmitis was considerably high in other studies.[340,41] Fortunately, in my study I didn't come across any case of endophthalmitis. Based on these above studies the accepted range for the percentage of cases with visual improvement as compared to the predicted visual improvement is 76% - 84.3%, the average being 80.2%. Our results are well within this range with visual improvement in 82.82% of cases.

Although results of our study are satisfactory but they can further be improved by several factors like advanced improvements in surgical techniques, suturing materials, modern equipments and donor storage. Further improvements in eye banking facilities, adopting Hospital Cornea Retrieval Programme to procure young donor corneas, and better patient counseling to ensure good follow-up are needed to improve long-term survival of corneal grafts and visual improvement postoperatively.

CONCLUSIONS

After completing this study, I arrived at these conclusions.

1. Penetrating keratoplasty is a safe and effective procedure with remarkable optical and visual outcomes for patients with corneal scars who have unacceptable corrected visual acuity.
2. Visual acuity significantly improved from baseline preoperative values after penetrating keratoplasty was done for corneal scars.
3. A total of 53 patients (82.81 %) got visual improvement ,6 patients (9.37%) showed no visual improvement while 5 patients (7.81%) got worsened visual acuity which is comparable with various other studies with low rates of complications.
4. 33 (51.56 %) of the operated eyes were blind before transplantation, of which 27 (42.19 %) got visual rehabilitation whereas 6 eyes (9.37 %) remained blind at 3 rd month of follow up that was a good achievement as compared to other studies.

REFERENCES

1. Armitage WJ, Tullo AB, Larkin. The first successful full-thickness corneal transplant: a commentary on Eduard Zirm's landmark paper of 1906. Br J Ophthalmology. 2006;90:1222-3.
2. Pizzarello L, Abiose A, Ffytche T, Duerksen R, Thulasiraj R, Taylor H,et al. Vision; 2020: The Right to Sight: a global initiative to eliminate avoidable blindness. Archives of Ophthalmology. 2004;122:615-20.
3. Jadoon MZ, Dineen B, Boome RA, Shah SP, Khan MA, Johnson GJ, et al. Prevalence of blindness and visual impairment in Pakistan. The Pakistan National Blindness and impairment survery.Invest Ophthalmo. 2006;47:49-55.
4. Dineen B, Bournee RR, Jadoon Z, Shah SP, Khan MA, Foster A, et al. Causes of blindness and visual impairment in Pakistan. Br J Ophthalmol. 2007;91:1005-10.
5. Kanski J. Clinical Ophthalmology, a systematic approach. Butterworth Heineman.
6. Olson RF, Mattingly TP, Waltman SR, Kaufman HE: Aphakic keratoplasty: Visual acuity and optical errors. Ophthalmolo. 2003;87:680-98
7. Perl T, Charlton KH, Binder PS. Disparate diameter corneal grafting: Astigmatism, intraocular pressure and visual acuity. Ophthalmol. 2003;88:774-45.
8. Troutman RC. Microsurgery of the Anterior Segment of the Eye. In The Cornea: Optics and Surg. 2004; 2:56-78.
9. Kanski J. Clinical Ophthalmology, a systematic approach, Cornea and refractive surgery, Butterworth Heinemann.2011.7.240
10. Kanski J. Clinical Ophthalmology, a systematic approach, Cornea and refractive surgery, Butterworth Heinemann.2011.7.241.
11. Caldwell DR: Postoperative recurrence of Reis-Bücklers corneal dystrophy. Am J Ophthalmol. 200;85:567.
12. Herman S1, Hughes WF: Recurrence of hereditary corneal dystrophy following keratoplasty. Am J Ophthalmol. 2002;75:689
13. Cosar CB, Sridhar MS, Cohen EJ, Held EL, Alvim Pde T, Rapuano CJ, et al. Indications for penetrating keratoplasty and associated procedures, 1996-2000. Cornea. 2002;21:148–51.
14. Siganos CS, Tsiklis NS, Miltsakakis DG, Georgiadis NS, Georgiadou IN, Kymionis GD, et al. Changing indications for penetrating Keratoplasty in Greece, 1982-2006: A multicenter study. Cornea. 2010;29:372–4.
15. Coster DJ, Williams KA. The impact of corneal allograft rejection on the long-term outcome of corneal transplantation. Am J Ophthalmol. 2005;140:1112–22.
16. Bhatti MN, Mahar YZ, Rahman AU , Kamal MF, Hassan MU, et al. Outcome of Penetrating Keratoplasty from a Corneal Unit in Pakistan. Pak J Ophthalmol 2009;2:-54-98.
17. Tabin GC, Gurung R, Paduyal G, Reddy HS, Hobbs CL, Wiedman MS, et al. Penetrating Keratoplasty in Nepal.

Cornea. 2004;23:589–96.
18. Williams KA, Muehlberg SM, Lewis RF, Coster DJ. How successful is corneal transplantation, A report from the Australian Corneal Graft Register. Eye. 1995;9:219– 27.
19. Williams KA, Lowe M, Bartlett C, Kelly TL, Coster DJ. Risk factors for human corneal graft failure within the Australian corneal graft registry. Transplantation. 2008;86:1720–4
20. Dandona L, Naduvilah TJ, Janarthanan M, Raghu K, Rao, Gullapalli N, et al. Survival analysis and visual outcome in a large series of corneal transplants in India. Br J Ophthalmol. 1997;81:726–31.
21. Brahma A, Ennis F, Harper R, Ridgway A, Tullo A. Visual function after penetrating keratoplasty for keratoconus: a prospective longitudinal evaluation. Br J Ophthalmol 2000;84:60–6.
22. Williams KA, Muehlberg SM, Wing SJ, Coster DJ. The Australian Corneal Graft Registry:1990 to 1992 report. Aust NZJ Ophthalmol 1993;21:1–48.
23. Vail A, Gore SM, Bradley BA, Easty DL, Rogers CA. Corneal graft survival and visual outcome: a multicentre study. Ophthalmology. 1994;101:120–7.
24. Price Jr FW, Whitson WE, Collins KS, Marks RG. Five-year corneal graft survival: a large, single-centre patient cohort. Arch Ophthalmol.1993;111:799–805.
25. Bradley BA, Vail A, Gore SM, Rogers CA, Armitage WJ, Nicholls SM et al. Penetrating keratoplasty in the United Kingdom: an interim analysis of the Corneal Transplant Follow-up Study. Clin Transpl. 1993;293–315.
26. Volker-Dieben HJM, D'Amaro J, Kok-van Alpen CC. Hierarchy of prognostic factors for corneal allograft survival. Aust NZJ Ophthalmol. 1987;15:11–8.
27. Epstein RJ, Seedor JA, Dreizen NG, Stulting RD, Waring III GO, Wilson LA et al. Penetrating keratoplasty for herpes simplex keratitis and keratoconus: allograft rejection and survival. Ophthalmol. 1987;94:935–2.
28. Yorston D, Wood M, Foster A. Penetrating keratoplasty in Africa: graft survival and visual Outcome. Br J Ophthalmol. 1996;80:890–4.
29. Sit M, Weisbrod DJ, Naor J, Slomovic AR. Corneal graft outcome study. Cornea. 2001;20:129–33.
30. Thompson RW, Price MO, Bowers PJ, Price. Long term graft survival after penetrating keratoplasty. Ophthalmolo. 2003;119:1398–402.
31. Peleyer U, Steuhl KP, Weidle EG, Lisch W, Thiel HJ. Corneal graft rejection: incidence, manifestation, and interaction of clinical subtypes. Transplant Proc. 1992;24:2034–37.
32. Bradley R, Diane S, David P. Indications for and outcomes of penetrating keratoplasty performed by resident surgeons. American Journal of Ophthalmology. 2003;136:68–75.
33. Khan SB, Aziz N, Hussain L, Alam M. Corneal blindness, Keratoplasty and visual outcome. J Med Sci. 2011;19(1):12-4.
34. Al-Fawaz, Abdullah MD, Wagoner, Michael D. Penetrating Keratoplasty for Trachomatous Corneal Scarring. Cornea. 2008;27(2):129-13.
35. Wagoner MD, Gonnah el-S, Al-Towerki AE. Outcome of primary adult penetrating keratoplasty in a Saudi Arabian population. Cornea. 2009;28(8):882-90.
36. Saunders PP, Sibley LM, Richards JSF, Holland SP, Chow DL, Courtright P. Outcome of corneal transplantation: Can a prioritisation system predict outcome? Br J Ophthalmol .2002;86:57-61.
37. Beckingsale I, Mavrikakis N. Penetrating keratoplasty: outcomes from a corneal unit compared to national data. Br J Ophthalmol. 2006;90(6):728–31.
38. Rahman F, Carley C, Hillarb A, Brahma AB.Penetrating keratoplasty: indications, outcomes, and complications. Eye. 2009;23:1288–94.
39. Skeens HM, Holland EJ. Large-diameter penetrating keratoplasty: indications and outcomes. Cornea. 2010;29(3):296-301.
40. Al-Marjan JI, Pandova MG, Reddy SS. Outcomes and indications for penetrating keratoplasty in Kuwait. Saudi J Ophthalmol. 2005;19:87-92.
41. Taban M, Behrens A, Newcomb RL. Incidence of acute ndophthalmitis following penetrating keratoplasty: a systematic review. Arch Ophthalmol. 2005;123:605-9.

میں خوش ہوں، راندۂ افلاک ہو کر
میرا قد بڑھ گیا ہے، خاک ہو کر

احمد فراز

بزرگی به عقل است نه به سال
تونگری به دل است، نه به مال

Saifullah

ORIGINAL ARTICLE

Assessment of Congenital Color Vision Deficiency Amongst High School Children Age Group 12 to 16 Years

Saifullah BS (Optometry) MPH, Arif Khan FCPS[2]

ABSTRACT

Objective: Human color vision is normally trichromatic in the sense that a suitable mixture of red, green and blue lights which can match any color that we can see. Color blindness occurs when one or more of the cone types are absent, or present but defective. It is a common X-linked genetic disorder. However, most of color blinds remain undetected due to absence of proper screening. To determine the prevalence of congenital color vision deficiency and identify the level of awareness about their color vision defect among high school students aged 12 to 16 years in Union Council MC4 District Charsadda, KPK.

Design: This was basically a cross sectional descriptive study.

Setting: The study was conducted in high schools of union council MC4 district Charsadda from 4th October 2014 to 17th January 2015.

Materials and Methods: A total of 1055 high school students in the selected age group were screened for congenital color vision defect using Ishihara's pseudo-isochromatic test 38 plate edition. The socio-demographic data and results of color vision test and ocular examination collected using pre-tested structured questionnaire. Data was entered and analyzed using SPSS statistical package version 15.0.

Results: A total of 1055 high school children were screened with a mean age of 14 ± 2.0 years which includes 530 male and 525 female. Among these 46 cases (4.36%) (95% confidence interval 2.98 to 5.42) were color blind. Of these 32 cases (69.50%) involved deutan, 09 cases (19.50%) protan, 05 cases (11%) unclassified. Among males the prevalence of color vision deficiency was 42 cases (7.92%) and females 04 cases (0.76%). All of the color blind subjects were not aware of their status of color vision.

Conclusion: The prevalence of congenital color vision deficiency in this study was significantly higher than the estimated prevalence for Asian population. Deutan was the most common defect. Early school screening for color vision defect is recommended.

Key words: Color vision deficiency, Protan, Deutan, Ishihara plates, Charsadda.

INTRODUCTION

Human color vision is normally trichromatic in the sense that a suitable mixture of red, green and blue lights can match any color that we can see. However, most of color blinds remain undetected due to absence of proper screening. Color blindness is the inability to distinguish certain colors. Molecular studies have shown that defects in color vision result from the absence, malfunction, or alteration of one (dichromatism), two (monochromatism) or all (achromatism) of the photopigments. Dichromats base their color vision on only two pigments.[1] The class of dichromats characterized by the entire absence of green cones is called deuteranopia, while those defects characterized by the absence of red cones are called protanopia and those characterized by the absence of blue cones are called tritanopia. Anomalous trichromacy is a relatively mild form of defective color vision. The terms protanomaly, deuteranomaly and tritanomaly is given when there is defect in red, green and blue pigments, respectively.

Protanomaly and protanopia are collectively referred to as protan colour vision defects, and deuteranomaly and deuteranopia are referred to as deutan defects. Protan and deutan colour vision defects are often collectively described as red-green defects. Tritanopia and tritanomaly are often described as the tritan or blue-yellow color vision defects.[1,2,3]

Many people are affected by color blindness but many of them remain undetected as they simply adapt to the environment to certain extent and also because of unawareness of the disease. Unaware about the defect, student may have difficulties in certain aspects while learning in school and student may not be able to reach his/her actual potential. Also color blind person, unaware of his or her defect, may choose certain professions, which may not be suitable for him, like traffic policeman, pilots and air traffic controller, train driver or technician in color industries, which require proper perception of colors which may lead to lesser efficiency in work as well as may cause accidents. So it is important to look at the prevalence of color blindness in children and identify the problems associated. The sooner the color deficiency can be identified the sooner accom-

[1] *Optometrist, DHQ Hospital Charsadda*
[2] *Assistant Professor, Ophthalmology, PIMS, Islamabad.*

Correspondence: *Saifullah, Optometrist, DHQ Hospital Charsadda (KPK) Email: saife.4all@gmail.com, Cell: 0334-9184240*

Received: April 2015 *Accepted: June 2015*

modation can be made to help the child. Considering these aspects, the study was carried out so as to find out prevalence of color blindness in school children so that they can be guided properly in their learning process as well as in choosing and adjusting with the suitable profession.

Congenital protan and deutan defects, which are collectively termed red-green color blindness, are common, affecting about 8.0–10.0% of Caucasian male population.[4] In contrast, congenital tritan defects are rare, affecting less than 1 in 10,000 people.[5] The prevalence of red-green color blindness has been found to vary between different races, tribes and ethnic groups.[6]

The prevalence of color vision defects among non-Europeans is lower than in persons of European ancestry in whom it is reported to be 6.0% for males and 0.25% for females.[7] In some European countries even higher prevalence is reported; 7.8% of school boys in Germany[8], 7.95% among males in Greek[9], and 7.33% in young Turkish[10] men were reported to have congenital color vision defect. A study done in Australia showed prevalence of 7.4% in males and 0.7% in females.[11] In the USA, the average incidence of red-green color blindness was found to be about 8.0% among males and 0.4–0.7% among females.[12] Asian males have a prevalence of color vision defects of 4.9% compared to 0.64% in females. A recent study from India reported a prevalence of 8.73% of males and 1.69% of females among Muslim population.[13] The prevalence in Arab boys of Saudi Arabia is 2.93%.[14] Individuals of African, Native American or Mexican ancestry have an even lower prevalence: 3.1% in males and 0.7% in females.[15] The incidence of red-green color blindness is significantly higher in North Africa than in sub-Saharan Africa which displays a very low incidence. However, in North Africa it is on the whole still appreciably lower than the usual European incidence of 7% to 9%. Studies in some of the countries of North Africa reported a prevalence of 6.56% in Algerians, 5.6% in Tunisians, 5.99% in Libyans and 10.5% in Moroccans among studied male population. The overall incidence of red-green color blindness in sub-Saharan population was reported to be 2.63%.[16] The study of color blindness in Ethiopian population is scarce with only two published studies. According to these studies, the prevalence of congenital color blindness among Ethiopians was reported to be 4.2% among males and 0.2% among females.[17,18]

The prevalence of congenital color vision deficiency among high school children, age group 12 to 16 years, is significantly higher than the estimated prevalence in Asian populations. The majority of school students are not aware of their problem. Early screening of school children for color vision defect is highly recommended, so that the affected individuals would be able to adjust their future career.

METHODOLOGY

It was basically a cross-sectional descriptive study. The study duration was from 4th October 2014 to 17th January 2015 in high schools of union council MC4 district Charsadda. All the students' age 12-16years on the day of examination were ***included*** in the study. All students in the selected age group with VA less than 6/12 and having the previous history of systemic and ocular diseases or drug history of ATT, CNS acting drugs etc will be ***excluded*** from the study and students with poor communication and cooperation.

A sample of 1055 was calculated using the standard formula $n=Z^2 P (1-P)/d^2$. Where n = sample size, Z = z-score for 95% confidence level (1.96), P = estimate of the proportion (0.0554), d = degree of accuracy (0.02). Simple random sampling technique was used.

All students present during the scheduled visits of the research team underwent color-vision screening using the short method consisting of 6 Ishihara pseudo-isochromatic plates. A short lecture on color vision deficiency/color blindness and the nature of the test was given prior to testing. The result was considered normal when all the plates were read correctly and abnormal when any plate was missed. Students who miss one plate in the screening plates were repeated with 38 plate's edition of Ishihara. The data was collected through a self-design questionnaire accompanying with preliminary eye and visual examinations.

In a room adequately lit by daylight, the color vision plates were held about 75 centimeters from the subject, and tilted so that the plane of the paper was at right angle to the line of vision. The correct position of each plate was indicated by the number printed on the back of the plate. Two sets of Ishihara plates with preselected six plates were used in the short method for the large-scale examination. The subjects were randomly assigned to either one: Plates 1, 2, 4, 8, 12, and 14 were used for Set A, while plates 1, 3, 7, 9, 11, and 15 were used for Set B. All investigators alternately took part in the screening. Subjects were tested binocularly. For the repeat examination, the same method was employed except that all 15 plates were used. If 13 or more plates were read normally, the color vision was deemed normal. If 9 or fewer plates were read normally, the color

vision was deemed deficient. In reference to plates 14 and 15, only those who read the numerals 5 and 45 and read them easier than those in plates 10 and 9 were recorded as abnormal readings. All students who were diagnosed to have color vision deficiency were advised regarding the results of the test. The results were also submitted to the teachers and school administrators for possible use in their career-orientation program. Likewise, the parents and guardians were counseled about the implications of the results on future career options of the affected students.

Written consent of the Principal of high school and verbal consent was obtained from Students screened for colour vision deficiency, after informing them about the nature and purpose of study. It was a non invasive and non interventional study, so there was no physical risk to the participants. The information provided by participants remains confidential. Nobody except principal investigator has an access to it. The study participants with color vision defect were explained about their problem and advised about the selection of their future carrier. Figure 1 Shows the sense perceived by normal, Protan, Deutan and Tritan.

Figure 1 Shows the sense perceived by normal, Protan, Deutan and Tritan

RESULTS

A total of 1055 high school children were screened with a mean age of 14 years which includes 530 male and 525 female. Among these 46 cases (4.36%) (95% confidence interval 2.98 to 5.42) were color blind. Of these 32 cases (69.50%) involved Deutan, 09 cases (19.50%) Protan, 05 cases (11%) Unclassified. Among males the prevalence of color vision deficiency was 42 cases (7.92%) and females 04 cases (0.76%). Among males the prevalence of color vision deficiency was 42 cases (7.92%) out of which 29 cases (69%) involved Deutan defect, 08 cases (19.10%) Protan defect, 05 cases (11.90%) Unclassified while among females 04 cases (0.76%) out of which 01 case (25%) involved Protan defect and 03 cases (75%) were Deutan defect. Cases of total color blindness(Achromotopsia) were not detected. All the color vision deficient were not aware of their status of color vision.

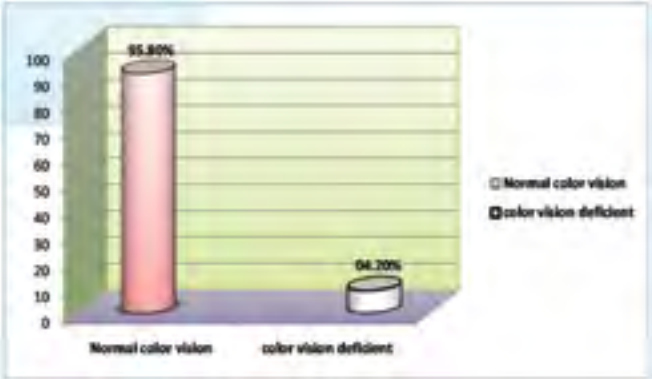

Figure 1.0 shows total number of normal and abnormal color vision deficient's screened

S. No	Frequency	Percentage
NVC	1014	95. 80%
CVD	46.00	04.20%
Total	1055	100%

Table 1.0 shows the total number of Normal and Abnormal color vision deficient's screened

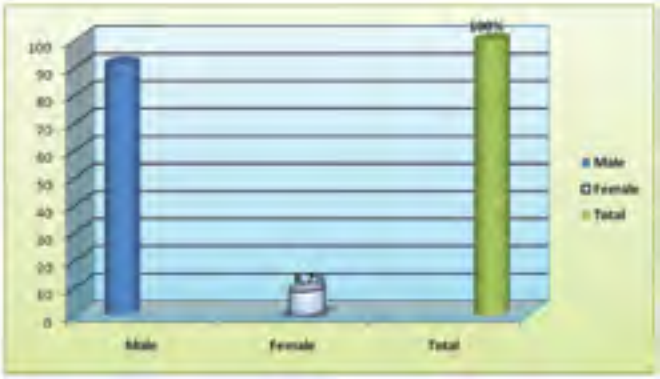

Figure 2.1 Show the total male and female color vision deficient

Gender	Frequency	Percentage
Male	42	91.30%
Female	04	08.70%
Total	46	100%

Table 3.1 Show the total male and female color vision deficient

Types of CVD among total students	Frequency	Percentage
Protan	09	19.50%
Deutan	32	69.50%
Tritan	00	00.00%
Unclassified	05	11.00%
Total	46	100%

Figure 2.2 Show the types of color vision deficiency among total students screened

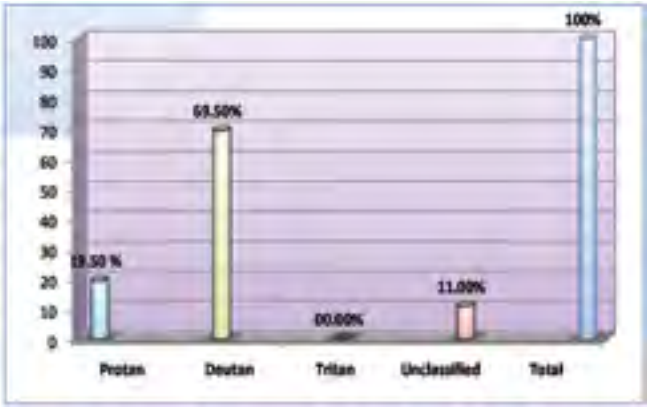

Table 3.2 types of color vision deficiency among total students screened

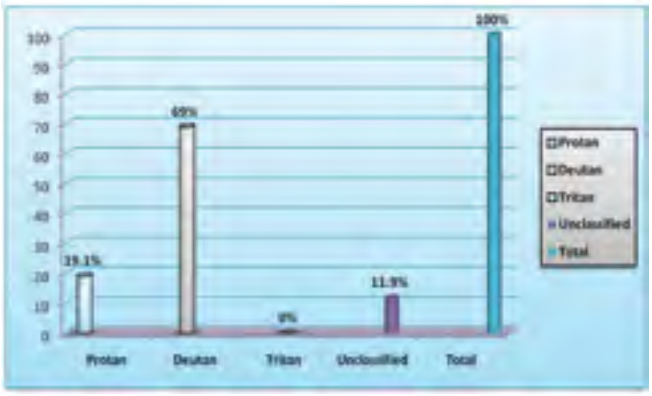

Figure 2.3 shows the types of color vision deficient's among male students screened

Types of CVD among male	Frequency	Percentage
Protan	08	19.10%
Deutan	29	69.00%
Tritan	00	00.00%
Unclassified	05	11.90%
Total	42	100%

Table 3.3 shows the types of color vision deficient among male students screened

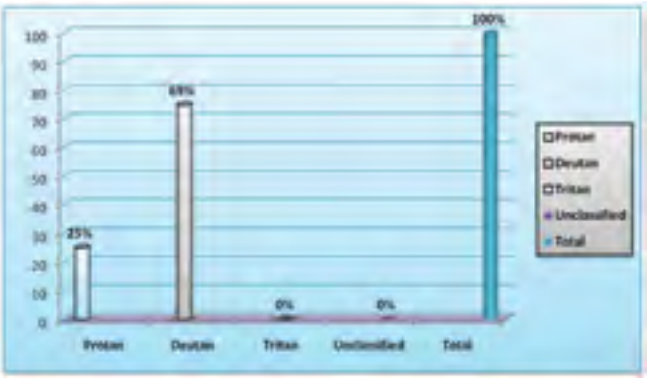

Figure 2.4 shows the types of color vision deficient among female students screened

Types of CVD among female	Frequency	Percentage
Protan	01	25.00%
Deutan	03	75.00%
Tritan	00	00.00%
Unclassified	00	00.00%
Total	04	100%

Table 3.4 Shows the types of color vision deficient among female students screened

DISCUSSION

In assessing color vision, the question is simply if there is a color deficiency resent or not. Since the prevalence of Protan and Deutan defects are by far the highest in congenital color deficiencies, most screening color vision tests only identify these red-green deficiencies. Screening of color vision deficiencies is usually done with so called pseudo-isochromatic plates of which the Ishihara test probably is the most well-known. In the three studies performed to evaluate the sensitivity of Ishihara pseudo-isochromatic test, there was no evidence that ishihara's test was less valid than any other screening tests.[19-21] Based on these studies, Ishihara test has the mean sensitivity of 96% and the mean specificity of 98.5%.[22] The Ishihara's test showed good retest reliability.[23] In this study we used Ishihara's test 38 plate edition which is generally considered to be the most efficient for screening red and green congenital defects.

The prevalence of congenital CVD among the high school students of union council MC4 District Charsadda, in my study for males students was much higher than the study conducted at Faisalabad in which among 750 boys, 18 were color deficient (2.4 %) while for the female the results were opposite in which among 1250 girls, 56 were color deficient (4.48%).[24]

Although the overall results of my study were almost similar to the estimated prevalence for Asian

population but males students have color vision defects of 7.94% 42 cases among 530 which was significantly higher than the estimated prevalence for Asians population compared to 0.64% in females, however the prevalence of female were little higher of (0.76%) as the estimated prevalence for Asians female were 0.64% [25]

The results of my study was also similar to the studies conducted in European countries in which the prevalence is reported; 7.8% of school boys in Germany[26], 7.95% among males in Greek[27] and 7.33% in young Turkish[28] men were reported to have congenital color vision defect. The high prevalence of color vision deficiency among male may be due to the hidden effect of cousin marriages.

The prevalence of congenital color vision deficiency in my study among male was 7.94% 42 cases out of 530 boys which are almost similar to the estimated prevalence for Caucasian which was 8%.[29]

Likewise in my study the prevalence of types of congenital color vision deficiency among total students including both male and female were 32 cases (69.50%) involved were Deutan, 09 cases (19.50%) Protan, 05 cases (11%) Unclassified so Deutan defect was the most common type of congenital color vision deficiency.

The prevalence of color vision deficiency was 42 cases (7.92%) and females 04 cases (0.76%). Among males the prevalence of color vision deficiency was 42 cases (7.92%) out of which 29 cases (69%) involved were Deutan, 08 cases (19.10%) Protan, 05 cases (11.90%) Unclassified so it was concluded that Deutan were the most common type of congenital color vision deficiency among male and protan were the 2nd common defect, while among females 04 cases (0.76%) out of which 01 case (25%) involved Protan and 03 cases were Deutan (75%) so Deutan were also most common type of congenital color vision deficiency and Protan were the 2nd common defect among female. Cases of total color blindness (achromotopsia) were not detected in my study which was very rare and in most the studies conducted on color vision deficiency, no case or very few cases very detected.

Detection of color vision defect early in life of an individual is very important to make informed decision on future career. Early detection of color vision malfunction in children allows parents and teachers to make necessary adjustments to the teaching methods for appropriate learning. However this is not always possible in developing countries like Pakistan with lack of awareness. Of the approximately 4.36% of congenitally impaired color vision were detected and none of them were aware of the defect prior to leaving secondary school. This study proved that all the subjects involved in this study were not aware of their status of color vision. It is unfortunate that a high proportion of school children are unaware of their color vision deficiency which will negatively affect their future career. Of course the Ishihara test with 38 plate edition has been reported to have high sensitivity and specificity in identifying red-green color vision defects.

CONCLUSION

The prevalence of congenital color vision deficiency among high school children, age group 12 to 16 years of union MC4 District Charsadda was 7.92% among males and 0.76% among female which was almost significantly higher than the estimated prevalence for Asian populations. The majority of school students were not aware of their problem. Early screening of school children for color vision defect is highly recommended, so that the affected individuals would be able to adjust their future career. I also recommend further studies to be done to determine the magnitude and severity of color vision defects using standard charts HRR (Hardy Rand Ritter) 4th edition and major Anomaloscope.

Recommendations

- The School eye health program should be strengthen with special attention should be paid to color vision testing along with visual acuity testing.
- The teachers should be trained to perform screening tests for color vision deficiency using different color pencils.
- At least Ishihara pseudo-isochromatic test plates should be available at DHQ and THQ hospitals for detection of CVDs.
- Optometrist posts should be created at THQ and DHQ hospitals and should be well equipped for identifying CVD so that counseling of the defective one for suitable profession can be made.

Limitations of the study

- Anomaloscope, the gold standard in color vision testing was not used to confirm the diagnosis due to unavailability.
- The standard Hardy Rand Ritter (HRR) 4th edition was not used due to unavailability.
- Extent of the color vision deficiency was not determined due to unavailability of standard test chart Hardy Rand Ritter (HRR) 4th edition for color vision deficiency.
- Although we have tried to screen participants under bright natural day light with all possible consideration of maintaining good illumination, using the artificial light source with fairly constant illumination was another limitation of this study.

REFERENCES

1. Diez MA, Luque MJ, Capilla P. *et al.* Detection and assessment of colour vision anomalies and deficiencies in children. *J Pediatr Ophthalmol Strabismus.* 2001; 38: 195–205.
2. Melanmud A, Hagstrom S, Traboulsi EL. Color vision testing. *Ophthal. Genetics*. 2004; 25(3): 159-187.
3. Cole BL. Assessment of inherited color vision defects in clinical practice. *Clin Exp Optom*. 2007; 90(3): 157 -175.
4. Pokorny J, Smith VC,Verriest G. *et al. Congenital and acquired color vision defects*. New York: Grune & Stratton, 1979
5. Went LN, Pronk N. The genetics of tritan disturbances. *Hum Gene.* 1985; 69:255.
6. Malhotra KC, Muttalik GS, Bhana BW. *et al.* The incidence of colour blindness among four endogamous nomadic groups. An example of natural selection. *Heredity.* 1974; 32:145–149.
7. Hurvich LM. *Color Vision*. Sunderland, MA: Sinauer Associates, 1981.
8. Feig K, Ropers HH. On the incidence of unilateral and bilateral colour blindness in heterozygous females. *Hum Genet.* 1978; 41:313-323.
9. Koliopoulos J, Iordanides P, Palimeris G, Chimonidou E. Data concerning colour vision deficiencies amongst 29,985 young Greeks. *Mod Probl Ophthalmol.* 1976; 17:161-164.
10. Citirik M, Acaroglu G, Batman C, Zilelioglu O. Congenital color blindness in young Turkish men. *Ophthalmic Epidemiol*. 2005; 12:133–137.
11. Mann I, Turner C. Color vision in native races in Australasia. *Am J Ophthalmol*.1956; 41: 797- 800.
12. Mueller RF, Young ID. *Emery's Elements of Medical Genetics*, 9th. edition. Edinburgh: Churchill Livingstone, 1995; 317.
13. Shah A, Hussain R, Fareed M, Afzal M. Prevalence of red-green color vision defects among muslim males and females of Manipur, India. *Iran J Public Health.* 2013; 42(1):16-24. Epub 2013 Jan 1.
14. Osuobeni EP. Prevalence of congenital red-green color vision defects in Arab boys from Riyadh, Saudi Arabia. *Ophthalmic Epidemiol*. 1996; 3(3):167- 170.
15. Jorgensen AL, Deeb SS, Motulsky AG. Molecular genetics of X chromosome- linked color vision among populations of African and Japanese ancestry. High frequency of a shortened red pigment gene among Afro-Americans. *Proc Natl Acad Sci USA*. 1990; 87: 6515.
16. Sunderland E, Rosa PJ. The incidence of red- green color blindness in the population of Tripolitania, cyreniaca, & Fezzan in Libia and of the Kikuyu, Kamba, Taita, Taveta & Luo tribes of Kenya. *Am J Phys Anthrop.* 1976; 44: 151- 156.
17. Adam A. A survey of some of the genetic characteristics in Ethiopian Tribes: Part VII : color vision. *Am J Phy Anthrop.* 1962; 20:194- 195.
18. Zein ZA. Gene frequency and type of color blindness in Ethiopians. *Ethiop Med J.* 1990; 28(2):73-75.
19. Dain SJ, Gray S, Tran L. Colorimetric analysis and performance assessment of the Hahn new pseudoisochromatic color vision test. *Color Res Application*. 1997; 23: 69-77.
20. Birch J. Efficiency of Ishihara test for identifying red- green color deficiency. *Ophthal physiol Opt* . 1997c; 17: 403-408.
21. Pease PL, Allen J. A new test for screening color vision: Concurrent validity and utility. Am J Optom Physiol Opt. 1988; 65: 729-738.
22. Weir R, Kirk R, Bidwell S, Hinder P. et al. Color vision screening. A critical appraisal of the literature. New Zealand Health Technology Assessment Clearing House. Report 7. October 1998.
23. Johnson DD. The Ishihara test: On the prevention of job screening programmes discrimination. J Am Optom Assoc. 1992; 63: 352-360.
24. Irfan Ahmed Mughal, Liaqat Ali, Nasir Aziz, Khalid Mehmood, Naila Afzal,"COLOUR VISION DEFICIENCY (CVD) IN MEDICAL STUDENTS" Pak J Physiol 2013;9(1), http://www.pps.org.pk/PJP/9-1/Irfan.pdf
25. Shah A, Hussain R, Fareed M, Afzal M. Prevalence of red-green color vision defects among muslim males and females of Manipur, India. Iran J Public Health. 2013; 42(1):16-24. Epub 2013 Jan 1.
26. Feig K, Ropers HH. On the incidence of unilateral and bilateral colour blindness in heterozygous females. Hum Genet. 1978; 41:313-323.
27. Koliopoulos J, Iordanides P, Palimeris G, Chimonidou E. Data concerning colour vision deficiencies amongst 29,985 young Greeks. Mod Probl Ophthalmol. 1976; 17:161-164.
28. Citirik M, Acaroglu G, Batman C, Zilelioglu O. Congenital color blindness in young Turkish men. Ophthalmic Epidemiol. 2005; 12:133–137.
29. Pokorny J, Smith VC,Verriest G. et al. Congenital and acquired color vision defects. New York: Grune & Stratton, 1979.

طبیبِ عشق نے دیکھا مجھے تو فرمایا
تیرا مرض ہے فقط آرزو کی بے نیشی
اقبالؔ

Sadia Bukhari

ORIGINAL ARTICLE

Conventional Muscle Recession V/S Hang-Loose technique in Patients with true type of Intermittent Distance Exotropia

Sadia Bukhari FCPS[1], Abdul Rashid Shaikh MS[2], Israr Ahmed Bhutto FCPS[3]
Maria Nazish Memon FCPS[4], Umair Qidwai FCPS, FRCS[5]

ABSTRACT

Objective: To compare the effectiveness, in terms of reduction in postoperative residual deviation, of conventional muscle resection v/s hang-loose technique in patients with divergence excess exotropia

Study design: Randomized parallel group study.

Place and duration of study: Al Ibrahim Eye Hospital, Karachi, from July 2011 to April 2013.

Methodology: Patients having intermittent exotropia (Deviation15-45 prism diopters [PD]) were included in this study, conducted from July 2011 to March 2012, at Al-Ibrahim Eye Hospital, Karachi. Patients with intermittent exotropia were randomly allocated into either bilateral lateral recession group which underwent bilateral lateral recession (maximum up to 10mm) or hang-loose technique group which underwent hang-loose technique. In conventional recession surgery, the lateral rectus muscle was attached directly at the desired scleral site, whereas in the hang-loose recession surgery, the lateral rectus muscle was suspended from the original insertion to the desired scleral attachment site with a double-armed 6-0 polyglactin suture. Final outcome was considered at the end of two months at which achievement of ≤10 PD of exotropia was considered as a success.

Results: In this randomized group study, 82 patients were ***included*** according to inclusion and exclusion criteria. Out of these 82 patients, 45 (54.9%) were male while 37 (45.1%) were female. Mean age of the patients was 17.48 years (± 9.39). Most of the patients, 48 (58.5%) underwent bilateral rectus recession, while the remaining 34 (41.5%) underwent hang-loose technique. Mean residual deviation in bilateral lateral rectus recession group after surgery was 7.79 prism diopters (± 8.43), compared to 9.32 prism diopters (± 9.77) mean residual deviation in hang-loose technique group after surgery. Similarly, success rate was also better in bilateral lateral rectus recession group, 89.5 %, compared to 73.53% in hang-loose technique group (p=0.058).

Conclusion: Conventional bilateral lateral rectus recession surgery has slightly higher success rate compared to Hang loose technique in cases of intermittent exotropia but the difference between the two techniques in not statistically significant.

Key words: Exotropia, hang-loose, polyglactin suture.

INTRODUCTION

Exotropia is a condition when eyes are deviated outwards,[1,3] in one study its incidence was found to be 64.1/100,000 patients younger than 19 years of age.[4] and a prevalence of approximately 1.0% in patients younger than 11 years.[4] If exotropia is not treated than it can result in not only cosmetic disfigurement but also can cause significant amblyiopia,[5,8] which becomes almost impossible to treat if exotropia appeared before the age of 10 years.[9,12]

[1]Associate Professor of Ophthalmology, Isra Postgraduate Institute of Ophthalmology, Al-Ibrahim Eye Hospital. Old Thana, Malir, Karachi. [2]Assistant Professor, Isra Postgraduate Institute of Ophthalmology, Al-Ibrahim Eye Hospital. Old Thana, Malir, Karachi. [3]Assistant Professor of Ophthalmology, Isra Postgraduate Institute of Ophthalmology, Al-Ibrahim Eye Hospital. Old Thana, Malir, Karachi. [4]Assistant Professor of Ophthalmology, Liaqat University of Health Sciences, Hyderabad. [5]Ophthalmologist, Clinical Fellow Ophthalmology / Oculoplastics, Department of Ophthalmology, James Paget University Hospital, UK

Correspondence: Dr. Sadia Bukhari FCPS, Associate Professor of Ophthalmology, Isra Postgraduate Institute of Ophthalmology, Al-Ibrahim Eye Hospital, Old Thana, Malir, Karachi. Email: drsadiabukhari@gmail.com, Cell: 0334-2113102

Received: May 2015 Accepted: June 2015

Surgical correction is one of the best management options for correction of exotropias.[13,14] But, surgical correction has always been a challenge. Which type of surgery is to be selected mainly depends on the surgeons preferences and personal experiences. Many surgeons have the opinion that bilateral lateral rectus muscle recession should be performed for true type of intermittent distance exotropia.[15] Conventional surgery that is bilateral lateral rectus recession and hang-loose techniques have been used for recession of the lateral rectus muscles for treating intermittent distance exotropias and other type of exotropias as well.[16]

Many researchers have compare the surgical results of hang-loose with that of conventional bilateral lateral rectus muscle recession for exotropia in general.[17,19] But as far as we know, not much work has been carried out in accessing the success results between the two surgeries in intermittent distance exotropias only, especially in our community. The main objective of this study is to compare the success of conventional bilateral lateral rectus recession with hang loose technique recession surgeries for intermittent distance exotropias.

METHODOLOGY

It was an randomized group study, conducted from July 2011 to April 2013, at Al-Ibrahim Eye Hospital, Karachi. Ethical approval was taken from the ethical committee of Isra Postgraduate Institute of Ophthalmology. Non-probability purposive sampling was used for patient selection. Patients having true type of distance exotropia (deviation 15-45 PD) were included in this study, while, patients with history of previous extra-ocular muscle surgery, paralytic exotropia and Any other ocular disease such as congenital cataract, retinal detachment and any other cause of sensory visual deprivation were excluded from the study. Patients who were dropped during follow ups were also excluded from the study. After informed written consent the patients were selected from the squint clinic of Al-Ibrahim Eye Hospital, Karachi, diagnosed and reconfirmed by the consultant ophthalmologist. All the patients underwent detailed ophthalmic examination including best corrected visual acuity, cycloplegic refraction, fundoscopy and squint assessment including measurement of squint using prism cover technique. Patients were randomly allocated to either Conventional bilateral lateral rectus recession surgery group or hang-loose technique group. Surgery was done under local anesthesia in adults but children were operated under general anesthesia.

In conventional recession surgery, the lateral rectus muscle was attached directly at the desired scleral site, whereas in the hang-loose recession surgery, the lateral rectus muscle was suspended from the original insertion to the desired scleral attachment site with a double-armed 6-0 polyglactin suture.

Patients were re-evaluated at one week, one month and two months post operatively. Final outcome was considered at the end of two months at which achievement of ≤10 PD of exotropia was considered as a success. Data was entered on a preformed proforma. Analysis was done using SPSS version 20.0. Qualitative data such as gender and success were presented by their frequencies along with percentages. The continuous variables such as age and degree of exotropia in Prism Diopters before and after surgery was presented as mean ±SD. Independent-T test was used to compare the means of residual deviation among the two techniques. P value of less than 0.05 was considered as significant.

RESULTS

In this randomized parallel group study, 82 patients were included according to inclusion and exclusion criteria. Out of these 82 patients, 45 (54.9%) were male while 37 (45.1%) were female. Mean age of the patients was 17.48 ± 9.39 years, with minimum age of 1 year and maximum age of 45 years. Most of the patients, 48 (58.5%) underwent bilateral lateral rectus recession, while the remaining 34 (41.5%) underwent hang-loose technique. Mean age was 17.23 ± 9.85 years in the bilateral lateral rectus recession group, while mean age was 17.85 ± 9.85 years in hang-loose technique group. Mean deviation in bilateral lateral rectus recession group before surgery was 49 ± 8.02 prism diopters , with minimum deviation of 32 prism diopters and maximum deviation was 65 prism diopters. Similarly, mean deviation in hang-loose technique group before surgery was 50.88 ± 9.57prism diopters , with minimum deviation of 35 prism diopters and maximum deviation was 65 prism diopters. Thus both the groups had almost similar deviations before surgery and the difference in deviation among the groups before surgery was not statistically significant (p=0.337, using paired-T test). Mean residual deviation in bilateral lateral rectus recession group after surgery was 7.79 prism diopters (± 8.43), with minimum deviation of 0 prism diopters and maximum residual deviation of 45 prism diopters. Similarly, mean residual deviation, in terms of deviation pre-operatively, in hang-loose technique group after surgery was 9.32 ± 9.77prism diopters, with minimum deviation of 0 prism diopters and maximum deviation of 40 prism diopters. Although residual deviations after surgery was lower in bilateral lateral rectus recession group but and the difference in residual deviation among the groups after surgery was not statistically significant (p=0.451), (Table-1). Similarly, success rate, was described as residual deviation postoperatively less than 10 prism diopters, was also better in bilateral lateral rectus recession group, 89.5 %, compared to 73.53% in hang-loose technique group (p=0.058), (TABLE-2).

TABLE-1 Deviation preoperatively and post operatively among the groups

Variable	Bilateral lateral rectus recession group	hang-loose group	P value (paird-T test)
Preoperatively	49 ±8.02 prism diopter	50.89 ± 9.57 prism diopter	0.337
Postoperatively	7.8 ±8.44 prism diopter	9.32 ± 9.78 prism diopter	0.451

TABLE-2 Comparison of success rate among the two techniques

Technique	Successful	Not successful	Total
Bilateral lateral rectus recession	43 (89.5 %)	5 (10.5%)	48
hang-loose technique P value=0.057	25 (73.53%)	9 (26.47%)	34

DISCUSSION

Patients in which the difference in distance deviation is greater than 10 prism dioptre than the near deviation is referred as distance exotropia.[20] To confirm whether this deviation is true distance deviation or simulative, we used +3.00 diopter lenses.[20] Our study showed that conventional bilateral lateral rectus recession is not only better in residual refraction but also has better success rate than hang-loose technique in true type of distance exotropia, but this difference is not statistically significant. Other studies done previously that have compared these two procedures have shown mixed results. Few studies on comparison of hang-back with conventional bilateral lateral rectus recession for exotropia have not found any significant difference in the surgical success rates (#10D of deviation) between the two techniques.[16,17]

However, few other studies have shown significantly greater success rate (#8D of deviation) in the conventional group than in the hang-back group (85% vs 64%) in their patients with distance intermittent exotropia. [19] They accredited this difference largely due to the late over corrections in the hang-back group. This is possibly due to the posterior bowing of the lateral rectus muscle. In our study, we followed the patients till two months, long term follow ups will be needed to confirm which procedure is more successful if any. The main limitation of our study was that, it was performed in a single Institute, thus racial variations were not included.

CONCLUSION:

No significant difference in success rate among the two procedures was seen in short follow ups.

Conflict of interest: There was no conflict of interest among the authors. No financial interests.

REFRENCES:

1. Govindan M, Mohney BG, Diehl NN, Burke JP. Incidence and types of childhood exotropia: a population-based study. Ophthalmology.2005;112(1):104-8.
2. Mohney B.G. Huffaker R.K.Common forms of childhood exotropia. Presented in part at: American Association for Pediatric Ophthalmology and Strabismus 28th Annual Meeting, March, 2002; Seattle.
3. Kushner B.J. Exotropic Deviations.Pediatric Ophthalmology. Springer Berlin Heidelberg publishers. 2009:97-111.
4. Simon JW, Aaby AA, Drack AV, Hutchison AK, Olitsky SE, Plager DA, et al. Pediatric Ophthalmology and Strabismus. Section 6. Sanfrancisco: American Academy of Ophthalmology; 2008. p.109.
5. Omoti AE.Hereditary wide angle exotropia in a nigerian family. Niger Postgrad Med J. 2007 Mar;14(1):76-8.
6. Lim Z, Seenyen L, Long Quah B. Characteristics of divergence excess type intermittent exotropia in Asian children. Presented at the 2008 Association for Research in Vision and Ophthalmology Meeting, Fort Lauderdale, Florida.
7. Donahue S.P. Pediatric Strabismus.N Engl J Med 2007; 356:1040-7.
8. Romanchuk K.G. Dotchin S.A.Jocelyn Zurevinsky J. The Natural History of Surgically Untreated Intermittent Exotropia—Looking Into the Distant Future. Journal of American Association for Pediatric Ophthalmology and Strabismus. June 2006;10(3):225–31.
9. Neela A Patwardhan N.A.Is age relevant for the success of treatment of anisometropic amblyopia? Indian J Ophthalmol. 2007 Nov-Dec; 55(6): 469–70.
10. Pineles S.L.Ela-Dalman N.Zvansky A.G.Yu F.Rosenbaum A.L.Long-term results of the surgical management of intermittent exotropia. Presented at the 36th Annual Meeting of the American Association for Pediatric Ophthalmology and Strabismus, Orlando, Florida, April 14-18, 2010.
11. Hatt S.R. Leske D.A. Mohney B.G. Brodsky M.C. Holmes J.M. Classification and Misclassification of Sensory Monofixation in Intermittent Exotropia, American Journal of Ophthalmology. 2010;*150(1) :16-22*
12. Ekdawi N.S. Nusz K.J. DiehL N.N. Mohney B.G. Postoperative outcomes in children with intermittent exotropia from a population-based cohort, Journal of American Association for Pediatric Ophthalmology and Strabismus.2009;13(1):4-7.
13. Donaldson MJ, Forrest MP, Gole GA. The surgical management of consecutive exotropia.2004; 8(3):230-6.
14. Chia A. Seenyen L. Long Q.B.A Retrospective Review of 287 Consecutive Children in Singapore Presenting With Intermittent Exotropia. Journal of American Association for Pediatric Ophthalmology and Strabismus.June 2005; 9(3): 257–63.
15. Thorburn D, Koklanis K, Georgievski Z. Management of intermittent exotropia strabismus of the divergence excess type. Binocul Vis Strabismus Q 2010;25:243-52.
16. Chia A, Seenyen L, Long QB. Surgical experience with two muscle surgery for the treatment of intermittent exotropia. J AAPOS 2006; 10:206-11.
17. Rajavi Z, Ghadim HM, Nikkhoo M, Dehsarvi B. Comparison of hang-back and conventional recession surgery for horizontal strabismus. J Pediatr Ophthalmol Strabismus 2001;38:273-7.
18. Orlin A, Mills M, Ying GS, Liu C. A comparison of hang-back with conventional recession surgery for exotropia. J AAPOS 2007;11: 597-600.
19. Capo H, Repka MX, Guyton DL. Hang-back lateral rectus recessions for exotropia. J Pediatr Ophthalmol Strabismus 1989;26:31-4.
20. Hardesty HH, Boynton JR, Keenan P. Treatment of intermittent exotropia. Arch Ophthalmol 1978;96:268-74.

Prof. Marianne

REVIEW ARTICLE

Ophthalmic Vigilance in Anti-angiogenic Pharmaco-therapy

Prof. Marianne Shahsuvaryan, MD, PhD, DSc

Yerevan State Medical University Republic of Armenia

ABSTRACT

Background: Vascular endothelial growth factor (VEGF) plays an important role in the patho-physiology of several sight-threatening retinal disorders such as age-related macular degeneration, retinal vein occlusion, diabetic macular edema and proliferative diabetic retinopathy. The discovery of anti-VEGF agents has revolutionized the treatment of these conditions. Ophthalmology has witnessed an explosion in the number of intravitreal injections delivered to patients over the past 10 years, driven in large part by the introduction and rapid incorporation of therapy with anti-VEGF agents. Currently several anti-angiogenic agents are being widely and successfully used for the treatment of eye diseases. However, there is some evidence that intravitreal anti-angiogenics injections may result in injection-related ocular side effects. This mandates an awareness on the matter.

Key words: antiangiogenic agents, pegaptanib sodium, ranibizumab, aflibercept, bevacizumab, intravitreal injections, ocular side effects.

INTRODUCTION

The term anti-angiogenic therapy was born more than 35 years ago by J. Folkman, who hypothesized that cancer may be treated by abolishing the nutrients and oxygen-providing blood vessels[1] by agents that could block the angiogenic cascade. Monoclonal antibodies against Vascular Endothelial Growth Factor (VEGF) were first developed as an intravenous treatment for metastatic colorectal cancer.[2,3]

Consequently, several antiangiogenics have been developed for the treatment of sight-threatening retinal diseases, including neovascular age-related macular degeneration, retinal vein occlusions and diabetic macular edema in diabetic retinopathy. There are 4 anti-VEGF agents that are either approved or in common use in ophthalmology, namely pegaptanib (Macugen, Pfizer), ranibizumab (Lucentis, Novartis), aflibercept or VEGF Trap-Eye (EYLEA, Bayer) and bevacizumab (Avastin, Roche).

a) ***Pegaptanib*** is a selective VEGF inhibitor, targeting only one isoform of the VEGF molecule, leaving other isoforms unaffected.[4] In 2004, pegaptanib (Macugen (Pfizer and OSI/Eyetech Pharmaceuticals, Inc.) was the first anti-VEGF agent to receive FDA approval for the treatment of neovascular age-related macular degeneration (AMD). The use of pegaptanib has declined with the release of newer anti-VEGF agents, such as ranibizumab (Lucentis™, Genentech, Inc., South San Francisco, CA, and Novartis Pharma AG, Basel, Switzerland), aflibercept (VEGF-trap eye, Eylea™, Regeneron Pharmaceuticals, Inc., and Bayer Pharma AG, Berlin, Germany) and bevacizumab (Avastin™, Genentech, Inc., South San Francisco, CA, and Roche, Basel, Switzerland).

(b) ***Ranibizumab*** (Lucentis™; Genentech, South San Francisco, CA, USA) is a humanised antigen binding fragment of a murine full length monoclonal antibody directed against human vascular endothelial growth factor - VEGF A. Ranibizumab binds all active isoforms of VEGF-A and is thus considered a non-selective VEGF-A inhibitor.[5]

(c) ***Aflibercept*** or VEGF Trap-Eye (EYLEA, Bayer) is a fully human fusion protein, consisting of soluble VEGF receptors 1 and 2, that binds all forms of VEGF-A along with the related Placental Growth Factor (PlGF). VEGF Trap-Eye is a specific and highly potent blocker of these growth factors. Aflibercept acts as a decoy receptor binding-free VEGF.[6]

(d) ***Bevacizumab*** (Avastin, Roche), is a full-length, humanized monoclonal antibody directed against all the biologically active isoforms of vascular endothelial growth factor (VEGF) –A. Bevacizumab binds to the receptor-binding domain of all VEGF-A isoforms.[7] Bevacizumab is FDA-approved for the treatment of colorectal cancer. However, because the agent costs substantially less per dose than ranibizumab, it has been widely used off-label since 2004 to treat several retinal diseases.

Ophthalmology has witnessed an explosion in the number of intravitreal injections delivered to patients

Correspondence: Prof. Marianne Shahsuvaryan, MD, PhD, DSc, Professor of Ophthalmology, Yerevan State Medical University, 7 Ap., 26 Sayat-Nova Avenue, Yerevan, 0001, Republic of Armenia

Received: January 2015 Accepted: March 2015

over the past 10 years, driven in large part by the introduction and rapid incorporation of therapy with anti-VEGF agents. Currently anti-angiogenic agents are being widely and successfully used for the treatment of eye diseases. However, there is some evidence that intravitreal antiangiogenics injections may result in injection-related ocular side effects. This mandates an awareness on the matter.

Injection-related ocular side effects:

(i) Infectious Endophthalmitis: Each intravitreal injection poses a risk of infection. The most devastating complication of intravitreal angiogenics injection is endophthalmitis.

(ii) Bacterial endophthalmitis: Retrospective reviews looking at bevacizumab, pegaptinib, and ranibizumab have found rates of endophthalmitis per injection of 0%, 0.02%, 0.077%, and 0.16%.[8-11] Rates of serious intraocular inflammation have ranged widely from 0.03% per injection in the 4 randomized trials of ranibizumab,[12] to 0.09% in a 12-month study of bevacizumab,[13] to 1.5% in a retrospective review of ranibizumab and bevacizumab injections.[8] The large-scale longitudinal case-control study of 6,154 individuals undergoing anti-VEGF treatment for neovascular AMD also revealed that at 2-year follow-up, the rates of endophthalmitis per injection (0.09%; $p<0.01$), uveitis (0.11%; $p<0.01$), were significantly higher in the anti-VEGF treatment group.[14]

There is a relatively high proportion of culture-positive cases that have the virulent Streptococcal species as the causative organism.[15,16] Simunovic et al.[16] revealed that in these cases endophthalmitis is associated with earlier presentation and poorer visual outcomes when compared with endophthalmitis following cataract surgery. General consensus is that many of these Streptococcal cases have dismal functional results, with visual acuity often dropping to hand motions or worse level and many cases leading to evisceration or enucleation.[15-17] While the exact source of the infectious nidus remains unknown, some evidence suggests it may be due to respiratory flora from the patient, the medical assistant or the injecting physician.[18,19] Therefore, most practitioners have a no-talking policy during the injection process. While some have advocated the use of face masks, this is not the prevailing standard of care.[20] Initially it was felt to be important to provide pre- or post-injection antibiotic prophylaxis to reduce the risk of endophthalmitis.[21] Lessons learned from Kim and Toma practice[22,23] are that this approach not only did nothing to reduce the risk of infection, it also created more antibiotic-resistant bacteria for those cases that did develop despite the use of antibiotics. As a result, the use of pre- or post-injection prophylactic antibiotics is not advocated.[24]

***(iii) Endophthalmitis after Bevacizumab injections*:** At present off-label intravitreal bevacizumab is only available through compounding pharmacies, there is a potential risk for contamination of bevacizumab during the aliquoting process, during transportation from the pharmacy to the physician's office or during storage of the drug.[25] It is important for physicians to become aware of their supplying pharmacy's procedures for the above and check in with them regularly to ensure appropriate compliance. Unfortunately, outbreaks of blinding cases of endophthalmitis have occurred when deviation from established protocols has led to widespread contamination of bevacizumab lots.[17,26]

(iv) Fungal Endophthalmitis: Not only bacterial, but also fungal endophthalmitis cases were presented by Sheyman et al.[27] after intravitreal injection of compounded combined bevacizumab and triamcinolone. Due to a number of infections, the Department of Veterans Affairs discontinued the use of Roche's Avastin for wet age-related macular degeneration.[28] In conclusion, although endophthalmitis cannot be prevented in all cases, certain risk reduction strategies have been proposed, including the use of an eyelid speculum, povidone iodine, avoidance of needle contact with the eyelid margin or eyelashes, and avoidance of routine post-injection antibiotics.[24]

Results of research conducted by Day et al.[14] evidenced that risk of endophthalmitis per injection (0.09%; $p<0.01$), uveitis (0.11%; $p<0.01$), and vitreous hemorrhage per injection (0.23%; $p<0.01$) were significantly higher in the anti-VEGF treatment group. With Cox proportional hazards modeling, the anti-VEGF treatment group had an 102% higher risk of severe ocular complications overall, and a 4% increased risk per injection, both of which were statistically significant ($p<0.01$).

(v) Sterile inflammation - Sterile endophthalmitis: Sterile endophthalmitis (also known as "pseudo-endophthalmitis") is described as any acute intraocular inflammation without infection that resolves without antibiotic treatment, unlike true endophthalmitis. The incidence of sterile endophthalmitis after intravitreal anti-VEGF therapy

ranges between 0.033% and 2.9%.[29-34] It is important to differentiate infectious endophthalmitis from sterile endophthalmitis, as the management and prognosis are different in each cases. Sterile endophthalmitis typically manifests 24 hours to 7 days after injection,[30,31,34-38] is painful or painless. Pain may be an indication of the severity of the inflammation in the anterior chamber and vitreous cavity. The most common presenting symptoms are blurred vision and floaters.[31] Visual acuity at presentation is substantially reduced compared with preinjection acuity and typically returns to preinjection acuity after resolution of the inflammation.[30,31] The average time to resolution of inflammation ranges from 2 to 12 weeks[31,35,37] and recovery of visual acuity occurs between 7 and 9 weeks.[31] Moreover, the time from injection to presentation with inflammation does not seem to affect the extent of visual recovery; it only affects the length of time to recovery.[30] In addition, history of prior intravitreal anti-VEGF injections does not increase the risk or severity of ocular inflammation in subsequent injections.[31,39] Topical steroid therapy is indicated for the treatment of sterile endophthalmitis. Agarwal et al.[40] highlighted the sterile inflammation is an adverse event of intravitreal anti-VEGF injection that should be included in the patient consent in all anti-VEGF agents. At present the etiology is unclear. The likely explanations include degradation of the agent with increased immunogenicity[41,42] due to not following the protocols - the medication should be refrigerated at 2 to 8 degrees C (36 to 46 degrees F), protected from the light, stored in the original carton until used, and used within 8 hours of being opened[43] or Bacterial endotoxin contamination has been reported in the pharmaceutical production phase of antibody preparation.[44] Acute intraocular inflammation is most frequently following bevacizumab,[45] possibly due to the less stringent purification process of the medication.[45]

(vi) ***Ocular Hypertension***: An ocular hypertension can occur transiently immediately following the bolus injection of 50 to 100 microliters of an anti-VEGF drug. What is more concerning is the potential for significant and sustained elevations in intraocular pressure elevation. This appears to occur in 3.5 percent to 11 percent of patients receiving chronic anti-VEGF agents.[46-48] It is unclear whether the etiology of this is mediated by the drugs' mechanisms of action on the trabecular meshwork, hydrostatic damage to the trabecular meshwork, outflow impairment, a combination of these, or due to some other unidentified mechanism. The key point here is to recognize the possibility of the risk (especially in patients with pre-existing risk factors for glaucoma), to monitor the IOP and optic nerve and to make the appropriate adjustments to the injection protocol when delivering subsequent anti-VEGF injections (e.g., lowering the volume of drug injection, using a larger-bore needle or increasing the injection interval).[49] Other injection-related quietly uncommon complications are retinal tears, retinal detachment, vitreous hemorrhage and traumatic iatrogenic cataract.[21] At the same time the latest findings from two-year results from the COPERNICUS study- Intravitreal aflibercept injection for macular edema due to central retinal vein occlusion[50] revealed that the most frequent ocular serious adverse event from baseline to week 100 was vitreous hemorrhage (6.8%).

CONCLUSION

A several anti-angiogenic agents are being widely used for the treatment of eye diseases like neovascular macular degeneration, retinal vein occlusion and diabetic macular edema. Taking into consideration that each intravitreal injection of anti-VEGF agents may potentially cause injection-related ocular side effects, currently available findings obviate the need to raise awareness of ophthalmologists about facing complicationes in patients with eye diseases treated by anti-VEGF. Early detection is crucial for appropriate management.

REFERENCES

1. Stewart M W.The expanding role of vascular endothelial growth factor inhibitors in ophthalmology Mayo Clinic Proceedings , January 1, 2012
2. Homsi J, Daud AI. Spectrum of activity and mechanism of action of VEGF/PDGF inhibitors. Cancer Control. 2007;14(3), 285–294.
3. Los M, Roodhart JM, Voest EE. Target practice: lessons from Phase III trials with bevacizumab and vatalanib in the treatment of advanced colorectal cancer. Oncologist 2007;12(4), 443–450.
4. Singerman LJ, Masonson H, Patel M, Adamis AP, Buggage R, Cunningham E, et al. Pegaptanib sodium for neovascular age-related macular degeneration: third-year safety results of the VEGF Inhibition Study in Ocular Neovascularisation (VISION) trial. Br J Ophthalmol. 2008 Dec;92(12):1606-11. doi: 10.1136/bjo.2007.132597. Epub 2008 Jul 9.
5. Rosenfeld PJ, Schwartz SD, Blumenkranz MS, Miller JW, Haller JA, Reimann JD. Maximum tolerated dose of a humanized anti-vascular endothelial growth factor antibody fragment for treating neovascular age-related macular degeneration. Ophthalmology 2005; 112: 1048–62.
6. Pieramici DJ, Rabena MD. Anti-VEGF therapy: comparison of current and future agents. Eye 2008;22;1330–1336
7. Ferrara N, Hillan KJ, Nowotny W. Bevacizumab (Avastin), a humanized anti-VEGF monoclonal antibody for cancer therapy. Biochem Biophys Res Commun. 2005;333:328–35.
8. Ladas ID, Karagiannis DA, Rouvas AA, Kotsolis AI, Liotsou A, Vergados I. Safety of repeat intravitreal injections of beva-

cizumab versus ranibizumab: our experience after 2,000 injections. Retina. 2009;29(3):313–318.
9. Fintak DR, Shah GK, Blinder KJ, , Regillo CD, Pollack J, Heier JS. et al. Incidence of endophthalmitis related to intravitreal injection of bevacizumab and ranibizumab. Retina. 2008;28(10):1395–1399.
10. Diago T, McCannel CA, Bakri SJ, Pulido JS, Edwards AO, Pach JM. Infectious endophthalmitis after intravitreal injection of antiangiogenic agents. Retina. 2009;29(5):601–605.
11. Gragoudas ES, Adamis AP, Cunningham ET, Jr, Feinsod M, Guyer DR. Pegaptanib for neovascular age-related macular degeneration. N Engl J Med. 2004;351(27):2805–2816.
12. Boyer DS, Chung CY, Tuomi L. A Safety Overview of Ranibizumab in Patients With Wet AMD: ANCHOR, MARINA, PIER, and SAILOR Studies. Abstract PO247 presented at the AAO/SOE Joint Annual Meeting; 8–11 November 2008; Atlanta.
13. Wu L, Martinez-Castellanos MA, Quiroz-Mercado H, et al. Twelve-month safety of intravitreal injections of bevacizumab (Avastin): results of the Pan-American Collaborative Retina Study Group (PACORES) Graefes Arch Clin Exp Ophthalmol. 2008;246(1):81–87.
14. Day S, Acquah K, Mruthyunjaya P, Grossman DS, Lee PP, Sloan FA. Ocular complications after anti-vascular endothelial growth factor therapy in Medicare patients with age-related macular degeneration. Am J Ophthalmol. 2011 Aug;152(2):266-72. doi: 10.1016/j.ajo.2011.01.053. Epub 2011 Jun 12.
15. Moshfeghi AA, Rosenfeld PJ, Flynn HW Jr, Schwartz SG, Davis JL, Murray TG, et al. Endophthalmitis after intravitreal vascular [corrected] endothelial growth factor antagonists: A six-year experience at a university referral center. Retina 2011;31:662-668.
16. Simunovic MP, Rush RB, Hunyor AP, et al. Endophthalmitis following intravitreal injection versus endophthalmitis following cataract surgery: clinical features, causative organisms and post-treatment outcomes. Br J Ophthalmol published 24 March 2012, 10.1136/bjophthalmol-2011-301439.
17. Matthews JL, Dubovy SR, Goldberg RA, Flynn HW Jr.Histopathology of streptococcus mitis/oralis endophthalmitis after intravitreal injection with bevacizumab: a report of 7 patients. Ophthalmology. 2014 Mar;121(3):702-8. doi: 10.1016/j.ophtha.2013.10.015. Epub 2014 Jan 16.
18. Wen JC, McCannel CA, Mochon AB, Garner OB. Bacterial dispersal associated with speech in the setting of intravitreous injections. Arch Ophthalmol 2011;129:1551-4.
19. Doshi RR, Leng T, Fung AE. Reducing oral flora contamination of intravitreal injections with face mask or silence. Retina 2012;32:473-6.
20. Schimel AM, Scott IU, Flynn HW Jr. Endophthalmitis after intravitreal injections: should the use of face masks be the standard of care? Arch Ophthalmol 2011;129:1607-9.
21. Jager RD, Aiello LP, Patel SC, Cunningham ET Jr. Risks of intravitreous injection: A comprehensive review. Retina 2004;24:676-98.
22. Kim SJ, Toma HS. Antimicrobial resistance and ophthalmic antibiotics: 1-year results of a longitudinal controlled study of patients undergoing intravitreal injections. Arch Ophthalmol 2011;129:1180-8.
23. Kim SJ, Toma HS. Ophthalmic antibiotics and antimicrobial resistance: A randomized, controlled study of patients undergoing intravitreal injections. Ophthalmology 2011;118:1358-63.
24. Schwartz SG, Flynn HW Jr.Endophthalmitis Associated with Intravitreal Anti-Vascular Endothelial Growth Factor Injections. Current Ophthalmology Reports; March 2014, Volume 2, Issue 1, pp 1-5
25. Gonzalez S, Rosenfeld PJ, Stewart MW, Brown J, Murphy SP. Avastin doesn't blind people, people blind people. Am J Ophthalmol 2012;153:196-203.
26. Goldberg RA, Flynn HW Jr, Miller D, Gonzalez S, Isom RF. Streptococcus endophthalmitis outbreak after intravitreal injection of bevacizumab: One-year outcomes and investigative results. Ophthalmology 2013;120:1448-53.
27. Sheyman AT, Cohen BZ, Friedman AH, Ackert JM. An outbreak of fungal endophthalmitis after intravitreal injection of compounded combined bevacizumab and triamcinolone. JAMA Ophthalmol. 2013 Jul;131(7):864-9. doi: 10.1001/jamaophthalmol.2013.88.
28. Berkrot B. , Pierson R. VA halts Avastin use for eye disease. Reuters, Sep 21, 2011
29. Lima LH, Zweifel SA, Engelbert M. et al. Evaluation of safety for bilateral same-day intravitreal injections of antivascular endothelial growth factor therapy.Retina 2009; 29(9):1213–7.
30. Wickremasinghe SS, Michalova K, Gilhotra J et al. Acute Intraocular Inflammation after Intravitreous Injections of Bevacizumab for Treatment of Neovascular Age-related Macular Degeneration. Ophthalmology 2008; 115(11): 1911.e1–1915.e1.
31. Chong DY, Anand R, Williams PD, Qureshi JA, Callanan DG. Characterization of sterile intraocular inflammatory responses after intravitreal bevacizumab injection. Retina 2010; 9: 1432–40.
32. Rosenfeld PJ, Brown DM, Heier JS et al. Ranibizumab for neovascular age-related macular degeneration. New England Journal of Medicine 2006; 355(14): 1419–31.
33. Brown DM, Kaiser PK, Michels M.et al. Ranibizumab versus verteporfin for neovascular age-related macular degeneration. New England Journal of Medicine 2006; 355(14): 1432–44.
34. Tolentino M. Systemic and Ocular Safety of Intravitreal Anti-VEGF Therapies for Ocular Neovascular Disease. Survey of Ophthalmology 2011; 56(2): 95–113.
35. Shah CP, Garg SJ, Vander JF, Brown GC, Kaiser RS, Haller JA. Outcomes and risk factors associated with endophthalmitis after intravitreal injection of anti-vascular endothelial growth factor agents. Ophthalmology 2011; 118(10): 2028–34.
36. Shima C., Sakaguchi H., Gomi F.et al. Complications in patients after intravitreal injection of bevacizumab.Acta Ophthalmologica 2008; 86(4): 372–6.
37. Bakri SJ, Larson TA, Edwards AO. Intraocular inflammation following intravitreal injection of bevacizumab. Graefe's Archive for Clinical and Experimental Ophthalmology 2008; 246 (5): 779–781.
38. Rosenfeld PJ, Heier JS, Hantsbarger H, Shams N. Tolerability and Efficacy of Multiple Escalating Doses of Ranibizumab (Lucentis) for Neovascular Age-Related Macular Degeneration. Ophthalmology 2006; 113, (4): 623.e1–632.e1.
39. Yamashiro K, Tsujikawa A, Miyamoto K et al. Sterile endophthalmitis after intravitreal injection of bevacizumab obtained from a single batch. Retina 2010; 30 (3): 485–490.
40. Agrawal S, Joshi M, Christoforidis JB. Vitreous Inflammation Associated ith Intravitreal Anti-VEGF Pharmacotherapy. Mediators of Inflammation Volume 2013 (2013), Article ID 943409, 6 pages http://dx.doi.org/10.1155/2013/943409
41. Hochuli E. Interferon immunogenicity: technical evaluation of interferon-α2a. Journal of Interferon and Cytokine Research 1997; 17(1). S15–S21.
42. Koren E, Zuckerman LA, Mire-Sluis AR.Immune responses to therapeutic proteins in humans—Clinical significance, assessment and prediction. Current Pharmaceutical Biotechnology 2002; 3 (4) 349–360.
43. Wickremasinghe SS, Michalova K, Gilhotra J et al. Acute Intraocular Inflammation after Intravitreous Injections of Bevacizumab for Treatment of Neovascular Age-related Macular Degeneration. Ophthalmology 2008; 115(11) 1911.e1–1915.e1.
44. Wang F., Yu S, Liu K, et al. Acute intraocular inflammation caused by endotoxin after intravitreal injection of counterfeit bevacizumab in Shanghai, China. Ophthalmology 2013; 120: 355–61.

45. Sharma S, Johnson D, Abouammoh M, Hollands S, Brissette A. Rate of serious adverse effects in a series of bevacizumab and ranibizumab injections. Canadian Journal of Ophthalmology 2012; 47, (3),. 275–9.
46. Freund KB. Can anti-VEGF therapy cause glaucoma? Available at: http://www.retinacme.com/new-developments-in-retinal-pharmacotherapy/2013/06_june/can-anti-vegf-therapy-cause-glaucoma/cme-information, accessed September 8, 2014.
47. Bakri SJ, Moshfeghi DM, Francom S, Rundle AC, Reshef DS, Lee PP, Schaeffer C, Rubio RG, Lai P. Intraocular pressure in eyes receiving monthly ranibizumab in 2 pivotal age-related macular degeneration clinical trials. Ophthalmology 2014;121:1102-8.
48. Pershing S, Bakri SJ, Moshfeghi DM. Ocular hypertension and intraocular pressure asymmetry after intravitreal injection of anti-vascular endothelial growth factor agents. Ophthalmic Surg Lasers Imaging Retina 2013 Sep-Oct;44(5):460-4.
49. Moshfeghi AA. Safety of Intravitreal Anti-VEGF Agents. Review of ophthalmology.11/11/2014
50. Heier JS, Clark WL, Boyer DS, Brown DM, Vitti R, Berliner AJ et al.Intravitreal aflibercept injection for macular edema due to central retinal vein occlusion: two-year results from the COPERNICUS study. Ophthalmology 2014;121(7):1414 PMID 24679444

Oral Mucocele

Examination of the tongue revealed a nontender, smooth-walled, translucent, bluish mass that was resting on an opalescent base. This is most consistent with a mucocele of the salivary glands. Oral mucoceles are often associated with repetitive cheek or lip biting.

DD Dermoid cyst, Hemangioma, Mucocele, Mucosal neuroma, Pyogenic granuloma

Sameera Irfan

POSTGRADUATE DIARY
SHORT COMMUNICATION

A STEPWISE APPROACH TO DRY EYE

Dr. Sameera Irfan FRCS
Mughal Eye Trust Hospital, Lahore

Some Basic Facts: Dry Eye is a multi-factorial disease; since there are three layers of the tear film, so three main etiologic causes should be looked for in every patient.

- Whether its reduced tear production with increased tear osmolarity and an inflamed ocular surface.
- Or increased tear evaporation due to deficiency of lipid layer.
- Or poor wetting of ocular surface due to mucin deficiency causing a dry, damaged hydrophobic corneal epithelium even in presence of adequate tear production.

Three Layers of a Tear Film

1. ***Superficial lipid layer:*** meibomian gland secretion, reduces tear film evaporation, lubricates the ocular surface and the eyelids, allowing a smooth movement of the upper lid downwards over the cornea, spreading the tear film uniformly over the ocular surface and polishing the corneal surface. It also prevents bacterial adherence on the corneal surface.
2. ***Central aqueous layer:*** isotonic tears secreted by the lacrimal gland (reflex secretion) and accessory lacrimal glands (basic tear production). Supplies oxygen, nutrients and epithelial growth factors to the cornea, polishes the cornea and is antibacterial because of immunoglobulins and isozymes.
3. ***Inner mucin layer:*** This is the most important layer being produced by the goblet cells present in the conjunctival and corneal surface epithelium. Normally corneal epithelium is hydrophobic. Mucins cover the corneal epithelium and make it hydrophilic so that the aqueous layer can stabilize over it and wet the corneal epithelium. They freely float in the tear film, act as clean-up proteins, removing debris and bacteria.

Concept of LFU: (Lacrimal Functional Unit)

The aqueous component of tear film by the lacrimal gland is produced in response to impulses travelling from the ocular surface (dried cornea/conjunctiva) to the brain. If the ocular surface is inflamed, less impulses will go the brain and tear production is reduced. It is a vicious circle.

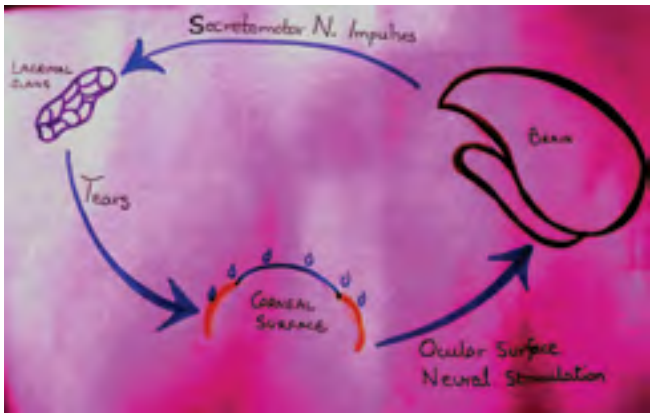

Pre-disposing Factors for a Dry eye:

In addition to searching for a cause of the Dry eye, identify the pre-disposing factors which have aggravated the condition.

1: **Old age:** Ageing causes androgen deficiency. Estrogen and androgen receptors are in lacrimal and meibomian glands. Androgens are trophic for lacrimal and meibomian glands. They are potent anti-inflammatory agents Tissue Growth Factor (TGF) and suppress lymphocytic infiltration of lacrimal glands. Androgen deficiency causes inflamed lacrimal and meibomian glands, with tear deficiency and hyper-osmolar tears. These cause a pro-inflammatory environment on the ocular surface. Also cytokine production and T-cell activation further inflame ocular surface, disrupt the neural arc, Cytokines inhibit neuronal function and further convert androgens to estrogens by increasing the level of tissue degrading enzymes.

2: **Connective tissue disorders:** Rheumatoid arthritis, SLE.

3: **LASIK:** the cut flap destroys corneal nerves and disrupts the LFU permanently.

4: **Drugs:** beta blockers. antihistamines, AGT: they damage goblet cells.

5: **Diabetes:** microangiopathy reduces blood supply to all glands, advanced glycation products in the tear film promote ocular surface inflammation.

6: **Vitamin A deficiency**

Symptoms: patients usually complain of burning, blurring of vision, glare while driving at night,

Photophobia, too much tearing, paradoxically. All symptoms are worsened by smoking, reading, computer work.

Examination:

1: **Identify the cause predisposing/aggravating factors** need to be treated. Look for chronic blepharitis, trachoma, trichiasis, lower lid ectropion, facial palsy, conjunctival scarring, corneal sensations (exposure keratitis).

2: **Grade the severity** of dry eye prior to starting any therapy so that the efficacy of treatment given can be monitored. Inferior limbal punctate corneal staining is due to toxic meibomian secretions irritating the inferior conjunctival and corneal epithelium. A central corneal staining is due to evaporative tear loss and dryness of central corneal epithelium.

Grading of Dry Eye

MGD = Meibomian gland dysfunction: foaming over lid margins, capping of meibomian orifices, notching of lid margin where meibomian glands are absent due to scarred orifices.

Levels	1	2	3	4
Visual symptoms	mild	moderate	severe	severe
Discomfort	mild	annoying	constant	constant
Conj. injection	none	none	+	++
Conj. Staining	none	moderate	++	+++
Corneal Staining	none	none	central	central
MGD	none	mild	Frequent	scarring
Tear Film BUT	> 10 mm	< 10 mm	< 5 mm	< 2 mm
Schirmers Test	> 10 mm	<10 mm	< 5 mm	< 2 mm

Treatment Strategy:

LEVEL 1:

1: **Find the cause and eliminate it. Look for pre-disposing factors.**

2: **Eyelid therapy:** scrubbing lid margin with a mild baby shampoo, tetracycline eye ointment massage onto the lid margin, hot fomentation of lid margins to melt fatty plugs on meiboman gland orifices, squeezing the fatty plugs out with upwards lid massage. Treat trachoma by tab. Azithromycin 1 gm stat and continue at least for 8 days or as advised by the treating ophthalmologist.

3: **Environmental and dietary modification:** Omega 3 fatty acids, Avoid air blowing in the eyes: hair dryers, car heaters, air conditioners, fans, add moisture to the air: a humidifier. Consider wearing wrap around glasses or eyeglass shields to avoid dry air, wind. Take eye breaks during long tasks: to evenly spread tear-film. Position the computer screen below eye level or cut short the computer work in order to reduce tear evaporation. Stop smoking and avoid smoke.

4: **Artificial tears:** eye drops during the day and ointment at night.

LEVEL 2:

If severity of Dry eye is at this level at presentation, or patient's condition worsens: Tear film BUT and Schirmer =/< 10, Then Add:

1: **Anti-inflammatory therapy:** Unless ocular surface inflammation is controlled, artificial tears would not wet the ocular surface. Options available are topical cyclosporin A, tacrolimus skin/eye ointment, omega 3 fatty acids, tetracyclines, topical steroids. The anti-inflammatory therapy has to be continued till Schirmers test shows adequate tear production and Tear Film BUT normalizes.

Tetracyclines: available as eye ointment is antibacterial, anti-inflammatory, antiangiogenic, reduce lipase production (which emulsifies the fatty acids in meibomian secretion) and stabilizes the tear film.

Cyclosporin A 0.05% eye drops: increases aqueous and meibomian secretion, increases goblet cell count, decreases cytokines and inflammatory cells in conjunctiva and lacrimal glands. Hence this is the only drug that improves secretion of all three components of tear film. It has to be preservative free as preservatives spoils the active ingredient.

Tacrolimus: this has the same mechanism of action as cyclosporin A eye drops but is 10 - 100x more potent. It is available as a skin cream 0.03% but is safe to use in lower conjunctival fornix, causes less stinging than Cyclosporin eye drops hence patients are more compliant to therapy. The 0.1% cream can be applied to lower lid skin twice a day.

Topical Steroids: Mild steroids can be used but long-term use causes a lot of side-effects hence it should be avoided as better/safer options are available as mentioned above

2: **Punctal plugs:** they should be avoided till ocular surface inflammation has been controlled by the above mentioned therapy. If they are used at the start of therapy then the retained inflammatory toxins will further enhance ocular surface inflammation and will worsen the condition.

LEVEL 3:

If symptoms are severe, conj. & central corneal staining; TBUT and Schirmer's < 5mm:

1: **Permanent punctal occlusion**

2: **Autologous serum:** Contains trophic factors which promotes growth and migration of corneal epithelial cells, immunoglobulins, vitamins and are non-antigenic. They are contraindicated if the patient has HIV, Hepatitis B/C, anemia. Complications that can occur are bacterial keratitis, conjunctivitis, scleral vasculitis and melting but they are rarely seen if proper precautions are taken in preparation.

Preparation: Draw 60 cc blood. Allow it to clot prior for 5-6 hrs. The serum is taken which now only contains platelets but no cells; it is centrifuged at 1500 – 5000 rpm (300 – 4000g) for 5 – 20 minutes so that platelets settle down. The serum is prepared in a clean room with a Laminar air flow hood and positive pressure (Operation theatre). To prepare 50% serum, 2.5 cc serum is added to 2.5cc normal saline in clean, sterile bottles (ETO). 30 bottles are prepared, they are frozen at -20* and then dispensed. They should be kept in freezer, one bottle should be used for 1-2 days and discarded.

3: **Soft bandage contact lens**

LEVEL 4:

Severe symptoms, SPK+++, conj. Scarring/symblepharon, TBUT immediate, schirmer< 2mm:

- Systemic immunosuppressant drugs.
- Surgery : amniotic membrane graft, lid surgery, tarsorrhaphy, cauterize punctae.

Summary: Remember: Dry Eye Management:

- 3 layers of tear film
- 3 Basic causes of dry eye syndrome
- 3 Basic tests:
- Tear Film BUT: detects mucin production.
- Schirmer's Test: detects aqueous production:
- Checking the lid margin for foaming, oily droplets, capping of meibomian orifices or lid nothcing shows MGD (Meibomian Gland Dysfunction)
- Schirmer's test: after instilling a local anesthetic 3-4 x, then place the strips to measure the basic secretion.
- Schirmer's strips can be made by Whatman's Filter paper available at chemists (for chemistry experiments). Strips 5 mm wide and 30 mm long should be cut and kept in the drawer of your slit lamp.

اے دوست کسی ہمدمِ دیرینہ کا ملنا
بہتر ہے ملاقاتِ مسیحا و خضر سے

کب ڈوبے گا سرمایہ پرستی کا زمانہ
دنیا ہے تیری منتظر روزِ مکافات

اقبالؒ

Shamshad Ali

ORIGINAL ARTICLE

Incidence of Refractive Errors in Secondary School Children in a Town of Lahore, Pakistan

(A Survey of Three Public Sector Schools)

Shamshad Ali MBBS[1], Naseer Ahmad MBBS[2], Khalid JamalMBBS[3]
Shahid Mahmood Diyal FCPS[4], Intzar Hussain FCPS, FRCS[5]

ABSTRACT

Objective: To determine the frequency of refractive errors in the eyes of Secondary School children of three public sector schools of a town of Lahore.

Materials and Methods: This Cross sectional study was conducted in Secondary schools from Lahore & Department of Ophthalmology Services Hospital Lahore from 20th Nov 2013 to 20th May 2014. Total 1050 eyes of different school children were selected. Informed consents were obtained from their respective school authority. They were documented on proper proforma for management and follow up results.

Results: A total of 525 students i.e. 1050 eyes were examined with age range from 11 to 16 years. Mean age of children was 13.1 ± 1.54 years. 54.1 % children were boys and 45.9% were girls. Refractive errors were present in 21.7% (n=228) eyes. Out of 228 ametropic eyes, myopia was present in 42.5%, hyperopia in 32.9% and astigmatism in 24.6% (n=56) eyes.

Conclusion: This study has shown that frequency of refractive errors is 21.7% and that of myopia, hyperopia and astigmatism among ametropic eyes is 42.5%, 32.9% and 24.6% respectively.

Abbreviation/Key words: Refractive Error, Myopia, Hypermetropia, Astigmatism.

INTRODUCTION

Emmetropia is the condition of eye in which parallel rays of light coming from infinity focus on the retina with the eye at rest. A refractive error may be defined as a state in which the optical system of the non-accommodating eye fails to bring parallel rays of light to focus on the retina.[1] Refractive errors are of three types, when the light rays come to focus in front of retina, is known as Myopia, when the light rays focus behind the retina is Hypermetropia, and Astigmatism is the visual defect in which the unequal curvature of one or more refractive surfaces of the eye, usually the cornea, prevents light rays from focusing clearly at a single point on the retina, resulting in blurred vision.

According to a study, the number of visually impaired persons in the world is about 259 millions. This estimate includes 98 million persons with visual impairment due to uncorrected refractive errors.[2] Despite the fact that refractive error is one of the most frequent reasons that people go for consultation to an eye care practitioner (ophthalmologist or optometrist) and though refractive error is the most common cause of reduced vision, there have been few population – based studies of refractive error.[3] WHO introduced the global initiative for the elimination of avoidable blindness by the year 2020 known as "vision 2020 initiative". Refractive errors are one of the priority areas for vision 2020 initiative.[4] Pakistan, the sixth most populous country in the world, is currently ranked 136 out of 177 countries listed in the United Nation's Human Development Index[5]. In Pakistan 11.4% of the blindness is due to uncorrected refractive errors.[6] The crude prevalence of myopia was 36.5% and the prevalence of hypermetropia was 27.1%.[5]

Refractive errors are usually present in the childhood and continue in the adult life. Unfortunately, they are not given much importance in our society which is evident from the fact that there is no effective system of pre-school visual examination either in the government or in the private sector. School children are considered to be high risk group because uncorrected refractive error can seriously affect their learning abilities, their physical and mental development and anisometropia can lead to amblyopia and strabismus, if the refractive errors are not corrected in early childhood. Moreover, planning of a youth's career is very much dependent on the vision, especially in jobs for navy, railways and aviations. This warrants early detection and treatment of refractive errors to prevent the permanent disability.

Recently, a significant increase in the prevalence of myopia has been detected.[6] This trend is most probably

[1]Trainee Medical Officer, Ophthalmology Unit A, Services Hospital Lahore, [2]Trainee Medical Officer Ophthalmology Unit B, PGMI Hayatabad Medical Complex Peshawar, [3]Post Graduate Trainee, Eye Unit A, Services Hospital Lahore, [4]Assistant Professor, Department of Ophthalmology, Kh. M. Safdar Medical College Sialkot, [5]Associate Professor, Department of Ophthalmology, Kh. M. Safdar Medical College, Sialkot.

Correspondence: Dr Shamshad Ali, Trainee Medical Officer, Ophthalmology Unit A, Services Hospital Lahore. Email: shamshadalidr@gmail.com, Cell: 0321-4488124

Received: May 2015 Accepted: June 2015

due to the increase in intensive near work – reading, writing and working on a computer. The occurrence of hyperopia among children, however, decreases with age. Children are born with physiological hyperopia. Undetected and uncorrected refractive errors are a particularly significant problem in school children. The prevalence of refractive errors was 19.8% in the study carried out in the hospital outdoor setting on 540 children out of which 107 children had refractive errors.[7] The results of a previous study conducted in Pakistan shows a prevalence of 4.27% of uncorrected refractive errors among the school children and in another study, the prevalence of refractive errors was 16.3% among children belonging to the government schools and 23.33% in children belonging to the private schools.[7] There is a large difference among the prevalence of refractive errors in both the above studies available and the recent study that was carried out six years back. The aim of this study was to correctly estimate the prevalence of various refractive errors in secondary school children of public sector, identify their types and provide them with spectacles so that permanent disability can be prevented and to provide suggestions to the authorities to make the eye examination necessary for all the school going children.

The survey in 3 public sector schools in Lahore shows the prevalence of refractive errors is 21.7%. Out of these Myopia, Hypermetropia and Astigmatism are 42.5%, 32.9% and 24.6% respectively.

MATERIALS AND METHODS

Study Design: Cross Sectional survey

Setting: Secondary schools from Lahore & Department of Ophthalmology
Services Hospital Lahore.

Duration of Study: 6 months (20th Nov 2013 to 20th May 2014)

Sample Size: Calculated sample size of 1050 eyes was calculated with 95% confidence level, 2.5% margin of error and taking expected percentage of refractive errors i.e. 19.8% in Secondary school children.[7]

Sampling Technique: Three schools will be selected randomly from one town of Lahore that will be convenient for study and will be included from the public sector. For a total sample size of 1000 eyes, 350 eyes will be selected from each school and then 70 from each class from 6th to 10th by using simple random sampling.

SAMPLE SELECTION:

Inclusion criteria:

- Students from class 6th to 10th in the selected school
- Both genders

Exclusion criteria:

- Children with other ocular disease i.e. trauma, Corneal opacity etc assessed with torch examination, direct ophthalmoscopy and hand held slit lamp examination.
- Children having cataract assessed with distant direct ophthalmoscopy and hand held slit lamp examination.

Data collection procedure: The selected schools were screened for one week (six working days) in which students were examined by assessing Visual Acuity from a Standard Snellen Chart. Informed consent for further proceedings was taken from the principal of the respective school. Those having Visual Acuity less than 6/12 in the better eye or both eyes were tested for the presence or otherwise of a refractive error by a pinhole were then subjected to retinoscopy and subjective refraction. Automated and cycloplegic refraction, where needed, were carried out at the Ophthalmology Department of Services Hospital Lahore.

The particulars of each student were filled on a structured questionnaire especially designed for the purpose. The data received from this questionnaire was entered to computer. Further information and results about variables like refractive errors i.e. myopia, hypermetropia and astigmatism were compiled with the help of this data.

Data analysis: The data was analyzed by using computer with SPSS version 17.0. Descriptive statistics were calculated. Quantitative variables like age were presented as mean ± Standard Deviation. Qualitative variables like gender and refractive errors were presented as frequency and percentage. The data was stratified for one or both eyes of children.

RESULTS

A total of 525 children from Government Muslim High School GT Road Baghbanpura, Government Girls Higher Secondary School Singh Pura and Government Boys Comprehensive higher Secondary School Ghorey Shah Road Lahore were included in this study. Mean age of children was 13.1 ± 1.54 years. [Table 1] 54.1% (n=284) children were boys and 45.9% (n=241) were girls. [Graph 1] Refractive error was found to be in 21.7% (n=228) eyes whereas 78.3% (n=822) eyes were found to be normal. [Graph 2] Out of these ametropic eyes, myopia was present in 43.0% (n=98), hyperopia in 32.4% (n=74) and astigmatism in 24.6% (n=56) eyes. [Table 2] Data stratification by either one or both eyes showed that myopia was one sided in 6.1% (n=6) and both sided in 93.9% (n=92) of eyes. Whereas hyperopia

was one sided in 10.8% (n=8) and both sided in 89.2% (n=66) of eyes. [Table 3]

TABLE 1 showing age distribution of children

Age	Children	
	Number of students	%
11-12	211	40.2
13-14	192	36.6
15-16	122	23.2
Total	525	100.0
Mean ± SD (Years)	13.1 ± 1.54	

TABLE 2 showing frequency of refractive errors

Refractive Error	Eyes (n=228)	
	N	%
Myopia	98	43.0
Hyperopia	74	32.4
Astigmatism	56	24.6
Total	**228**	**100.0**

TABLE 3 Distribution of refractive errors in eyes

Eye	Myopia		Hyperopia		Astigma-tism		Total	
	no	%	no	%	no	%	no	%
One eye	6	6.1	8	10.8	16	28.6	30	13.2
Both eyes	92	93.9	66	89.2	40	71.4	198	86.8
Total	98	100.0	74	100.0	56	100.0	228	100.0

DISCUSSION

Ametropia is defined as a state of refraction, when parallel rays of light coming from infinity are focused either in front or behind the retina after passing through the diopteric power of the eye when the accommodation is at rest.[8] It is estimated that 2.3 billion people worldwide have refractive errors; out of which 1.8 billion have access to adequate eye examination and affordable corrections leaving behind 500 million people, mostly in developing countries with uncorrected error causing either blindness or impaired vision.[9]

The World Health Organization has launched the Global Initiative Vision 2020 in 1999 with the slogan "The Right to sight,'' that has five priority areas. They have been chosen on the basis of the burden of blindness they represent and the feasibility and affordability of interventions to prevent and treat them. It includes refractive errors although other major causes of blindness like glaucoma and diabetic retinopathy are not included.[10] Refractive errors are usually present in the childhood and continue in the adult life.[11]

Unfortunately, they are not given much importance in our society which is evident from the fact that there is no effective system of pre-school visual examination of children either in the government sector or in the private sector. Most of the children with uncorrected refractive error are asymptomatic and hence screening helps in early detection of refractive errors and timely interventions. Uncorrected refractive error may have impact to a larger extent on the learning capability and potential of the student. Timely detection and intervention can improve child's potential tremendously during the formative years.

In Pakistan 11.4% of the blindness is due to uncorrected refractive errors including that is caused by aphakia (natural lens extraction during cataract surgery).[12] Efficient pre-school and regular school health services are available in developed countries and the job of detecting (and managing) refractive errors lies mainly on the school health personnel as well as the optometrist. Even in the presence of such efficient school health services these developed countries are now taking help from community health workers and teachers for the early detection of visual disorders in school children.[13]

We do not have such regular and efficient school health services in our country. So we can-not at present, utilize school health personnel or the optometrists. However, it is heartening to note that some of the developing countries, including Pakistan are now training teachers to screen the children regarding the presence or other-wise of defective vision.[14]

In this study 525 children from three different government schools were examined. A total 1050 eyes were examined and out of these, 21.7% (n=228) had refractive errors. Out of these, myopia was found to most frequent refractive error and was present in 42.5% (n=97), hyperopia was present in 32.9% (n=75) whereas astigmatism was seen in 24.6% (n=56). Our results are similar to Ali et al who has reported 19.8% prevalence of refractive errors in school children.[7] Shah et al had found myopia the most frequent refractive error, present in 36.5% of children, followed by hypermetropia 27.1%.[5] Sethi et al has reported 10% frequency of refractive error in children of Landi Kotal. They found that. 58% children were hypermetropic, 36% myopic, and 6% had astigmatism.[15]

Some studies have shown very low prevalence of refractive error. Alam et al showed 8.9% prevalence of

refractive error,[16] Khalil et al found refractive error in 2.90% of children.[17]

Our study has shown myopia is most common refractive error in school children. Similar trends were shown by Pi et al in Chinese population, reporting frequency of myopia, hyperopia, and astigmatism in 13.75%, 3.26% and 3.75% respectively.[18] Similarly, Myopia was the most prevalent refractive error; accounting for 6.0 %, followed by mixed astigmatism 0.26 % and hyperopia 0.33% in a study by Mehari et al in Ethiopia.[19] Our study has shown that myopia was present in 52.6% male and 47.4% females. On the other hand, 54.7 % male and 45.3% female were hyperopic.(P 0.126). These results are similar to Alam et al study.[16] Limitations of our study were that only school going children in government schools in urban area were included in the study. Significant proportion of children live and study in rural areas of Pakistan and were not included in this study; hence a more complete assessment of visual impairment in children would be possible with population based studies not restricted only to school going children. Population based studies covering all school going children is recommended.

These data support the assumption that vision screening of school children in Pakistan will be very useful in early detection of correctable causes of poor vision, especially refractive errors and in preventing long term visual complications.

CONCLUSION

The study, prevalence of refractive errors in secondary school children, has shown that frequency of refractive errors is 21.7%. Out of these, myopia, hyperopia and astigmatism are 42.5%, 32.9% and 24.6% respectively.

REFERENCES

1. Khalaj M, Gasemi M, Zeidi MI. Prevalence of Refractive Errors in Primary School Children [7-15 Years] of Qazvin City. Eur J Sci Res 2009;28:174-185.
2. Dandona L, Dandona R. What is the global burden of visual impairment? BMC Med 2006;4:6-9
3. Pateras ES. Prevalence of Refractive errors amongst adults, located at the north suburbs of Athens- Greece. Health Sci J 2012;6:102-114.
4. Malik R, Rahil N, Khan O. Prevalence of Refractive Errors in School going Children in age Group of 11-15 years. Ophthalmology Update 2011;9:26-29.
5. Shah PS, Jadoon ZM, Dineen B, Bourne ARR, Johnson JG, Gilbert EC et al. Refractive Errors in the Adult Pakistani Population: The National Blindness and Visual Impairment Survey. Ophthal Epidemiol 2008;15:183-190.
6. Kathrotia GR, Dave GA, Dave GA, Dabhoiwala TS, Patel DN, Rao PV et al. Prevalence and Progression of Refractive Errors Among Medical Students. Indian J Physiol Pharmacol 2012; 56(3): 284-287.
7. Ali A, Ahmed I, Ayub S. Prevalence of Undetected Refractive Errors among School Children. Biomedica 2007;23:21.
8. Khurana AK. Text book of ophthalmology. 3rd ed. New Delhi: New Age International Publisher; 2006:52-59.
9. Holden BA, Sulaiman S, Knox K. The Challenge of Providing Spectacles in the Developing World. Journal of Community Eye Health 2000; 13 (33): 9-10
10. Parajasegram R. Vision 2020. The Right to Sight: from strategies to action. Am J Ophthalmol 1999; 128: 359-60.
11. Fan DS, Lam DS, Lam RF et al. Prevalence, incidence, and progression of myopia of school childrenin Hong Kong. Invest Ophthalmol Vis Sci. 2004: 45 (4): 1071-5
12. National Committee for Prevention of Blindness, Ministry of Health, Special Education and Social Welfare, Islamabad, Pakistan, National Programme for Prevention of Blindness: First five year Plan 1994-98; P. 24
13. Kasmann-Kellner BW, Ruprecht KW. Vision screening survey of all children starting primary school in 1998 in the Federal State of Saarland, Germany. Strabismus. 2000; 8 (3): 201-7
14. Afghani T, Vine HA, Bhatti A, Qadir MS, Akhtar J, Tehzib M et al. Noor (ASAN) refractive error study of one million school children. Pakistan J Ophthalmol 2003 Oct; 19 (4): 101-7.
15. Sethi MJ, Sethi S, Iqbal R. Frequency of refractive errors in children Visiting eye out patient department agency Head quarter hospital landi kotal. Gomal Journal of Medical Sciences 2009;7: 2 114-117
16. Alam H, Siddiqui MI, Jafri SI, Khan AS, Ahmed SI, Jafar M. Prevalence of refractive error in school children of Karachi. J Pak Med Assoc. 2008;58(6):322-5.
17. Khalil A. Lakho, M. Zahid Jadoon, P.S. Mahar. Pattern of Ocular Problems in School going Children of District Lasbela, Balochistan. Pak J Ophthalmol 2012;28:114-8
18. Pi LH, Chen L, Liu Q, Ke N, Fang J, Zhang Set al. Refractive Status and Prevalence of Refractive Errors in Suburban School-age Children. Int J Med Sci 2010; 7(6):342-53
19. Mehari, Z. A. and Yimer, A. W. Prevalence of refractive errors among school children in rural central Ethiopia. Clin Exper Optomet 2013; 96: 65–69.

Salman Hamza

ORIGINAL ARTICLE

Grafting of Autologous Fascia Lata in the Treatment of Perforated Mooren's Ulcer

Muhammad Salman Hamza FCPS[1], Ch. Javaid Iqbal FCPS Fellow Vitreo-Retina[2]
Amtul Naseer Sami FCPS, Fellow Paediatric Ophthalmology[3], Qunbar Abbas FCPS[4]
Prof. Imran Akram Sahaf FRCS[5]

King Edward Medical University, Institute of Ophthalmology, Mayo Hospital, Lahore

ABSTRACT

Introduction: Mooren's ulcer is a rapidly progressive, painful, ulcerative keratitis which initially affects the peripheral cornea and may spread circumferentially and then centrally. It has two types: Benign and Malignant. Malignant type is more painful and generally gives a poor response to the therapy and tends to perforate for which currently no satisfactory treatment is available. Use of autologus fascia lata to plug perforation has been initiated by Prof. Imran Akram Sahaf.

Material and Method: This study was conducted in Institute of Ophthalmology, King Edward Medical University, Mayo Hospital, Lahore. Six patients with perforated Mooren's ulcer were included in this study. The size of perforations varies from button hole to ¾ of peripheral cornea. In all the cases autologus Fascia lata was grafted. Follow up was done for 6 months

Results: All the globes were saved from being lost due to perforation. It provided relief from the symptoms like pain, photophobia and lacrimation. This procedure also reduced Inflammation and congestion.

Conclusion: Use of autologus fascia-lata in perforated Mooren's ulcer provides promising results in globe preservation.

INTRODUCTION

Mooren's ulcer is a rapidly progressive, painful, ulcerative keratitis which initially affects the peripheral cornea and may spread circumferentially and then centrally.[1] Wood and Kaufman classified Mooren's ulcer in two main forms.[2] Benign or Limited type is typical, usually unilateral, less aggressive and respond to the medical or surgical treatment. Malignant type is more painful, usually bilateral, very aggressive, generally does not respond to the medical or surgical treatment like amniotic membrane transplantation[3] and tends to perforate.[4] Though use of corneo-scleral grafts to treat serious corneal disorders was first proposed in the early 1970s but it was associated with early rejection.[5]

There is no satisfactory treatment available to treat perforated Mooren's ulcer. So, there is need to use a material which can be used effectively and also easily available everywhere. Use of autologous fascia to plug the perforation was initiated by Prof. Imran Akram Sahaf. Fascia lata is a strong collagen tissue, easily available and can be used to preserve the globe and to save the vision.

[1]Ophthalmologist, Eye Unit, [2]Assistant Prof, [3]Associate Prof, [4]Senior Registrar, [5]Head of the Department, Eye Unit:1

Correspondence: Dr.Muhammad Salman Hamza, Eye unit II, Mayo Hospital, Lahore. E-mail: salman_hamza@hotmail.com, Cell: 0322-4865105

Received: April 2015 Accepted: June 2015

Using autologous fascia lata graft with conjunctiva in the management of perorated Mooren's ulcer, it modifies the disease and provides good results in saving the eye.

MATERIAL AND METHOD

This study conducted in Institute of Ophthalmology Mayo hospital Lahore for a period of one and half year starting from January 2013 to June 2014. It was descriptive study. Six patients with perforated Mooren's ulcer were ***included*** in this study. Any patient having infected cornea was ***excluded*** from the study. After obtaining demographic data, complete history, slit lamp examination, B scan were carried out. Laboratory investigation was done to rule out any associated systemic autoimmune disease. Procedure was completely described to the patients and informed consent was obtained. In all the cases autologous fascia lata was grafted and it was covered with conjunctival flap. Follow up was done at first week, 3 month and at 6 month.

Technique of Fascia lata grafting: Procedure was done under local or general anesthesia. Perforated area exposed (Fig 1 A). Conjunctival peritomy was carried out to expose full extent of Mooren's ulcer. Ulcer bed along with perforated area depitheaillized and conjunctival flap was raised (Fig1 B). Ulcer size measured. Autologus Fascia lata harvested. It was

soaked in gentacin for 2 min. Then it was placed on the ulcer along the limbus circumferentially. Its length adjusted so as to cover the perforation 2 mm on either side at limbus. Breadth was adjusted to cover both perforation and ulcer gutter. Trimming can be carried out if required according to the size of ulcer bed. One edge of Fascia lata sutured with 10/0 nylon to cornea and other to the limbus (Fig.1 C). Conjunctival flap was raised and whole of the fascia lata was covered with it (Fig.1 D).

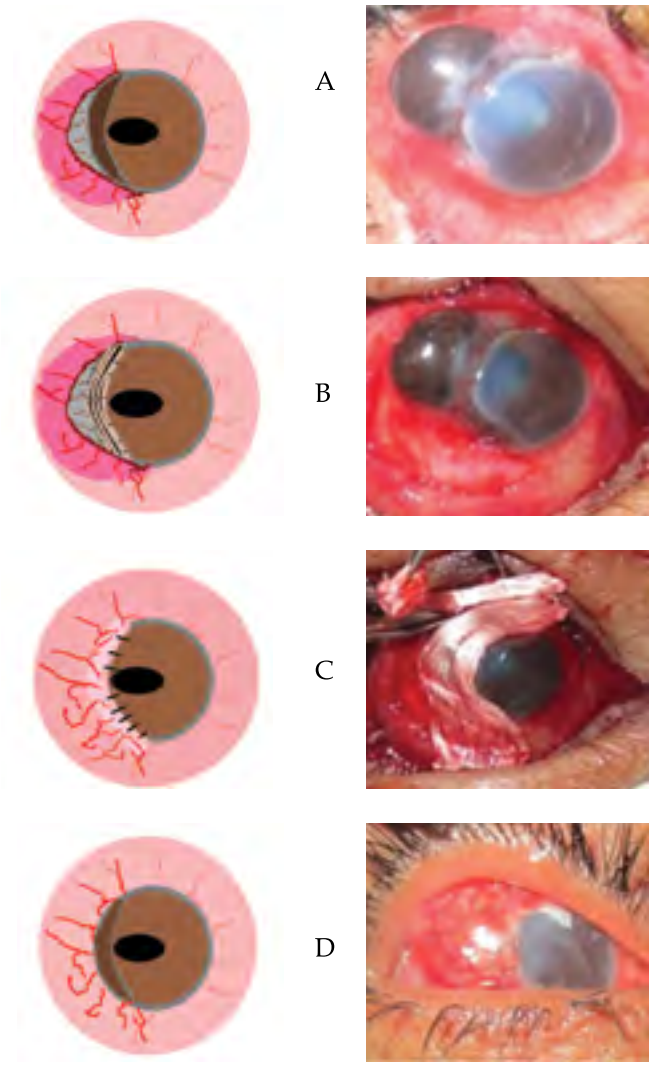

Fig 1. Right side. Diagrammatic illustration, Left side. Original photographs during surgery

A. Perforated Mooren's ulcer
B. De-epithelization of Ulcer bed
C. Fascia Lata grafted
D. Conjuctival flap covering the Fascia lata

RESULTS

Out of six patients 5 (83.3%) were male and one (16.6%) was female (Chart No. 1). Age ranges from 40-65 years. The Size of perforations varies from button hole to ¾ of peripheral cornea. Follow up period was 6 months at least. Patients were evaluated for preservation of globe, reduced inflammation, improved symptoms like pain, photophobia, and visual acuity. In all 6 eyes globe was preserved from being lost. Fascia lata sealed perorated area. Inflammation and congestion was completely reduced in 5 cases. In one topical immunosuppressant medication was given to reduced inflammation (Fig. 2). Symptoms were improved. Pain and photophobia reduced, patients were able to open the eyes comfortably. Visual acuity improvement was greatly dependent on size of perforation. It varies from Perception of light in one case (16.6%), counting finger in 4 cases (66.6%) and 6/60 in one case (16.6%). The patients with reduced vision and no inflammation without any topical or systemic medication were referred for keratoplaty.

Chart No.1: Gender Distribution

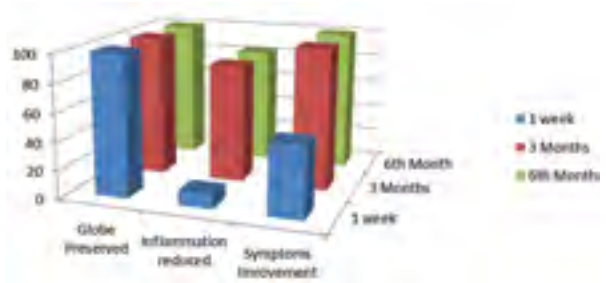

Chart No. 2: Different variable showing improvement after fascia lata grafting

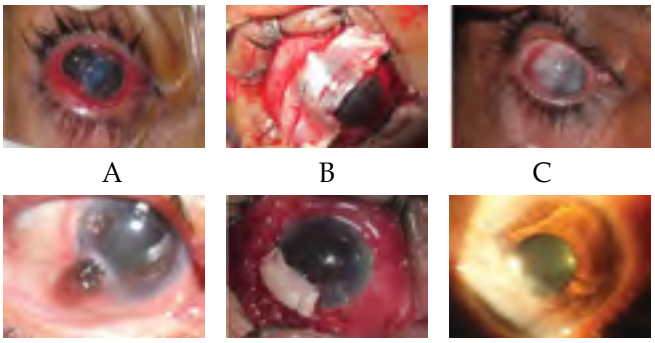

Fig. 2: Cases with Perorated Mooren's Ulcer (A), Treated with Fascia Lata and conjunctival flap (B). 6th month Post Operative(C)

DISCUSSION

Malignant form of Mooren's ulcer is most difficult to treat. It leads to corneal perforation and eventually phthisis bulbi. There is no satisfactory treatment for perorated Mooren' sulcer. The exact pathogenesis of Mooren's ulcer is still unknown. It is an autoimmune disease. Anti-corneal and anti-conjunctival tissue antibodies have been isolated from patients suffering from this disorder.[6] The conjunctival tissue surrounding the lesion is generally rich in proteo-glycolytic enzymes secreted by mononuclear cells and neutrophils that progressively infiltrate the area surrounding the ulcer.

Corneoscleral grafts to treat this serious form of Mooren's ulcer were first reported in the early 1970s.[7] The percentage of surviving graft tissue has always been very low mainly because of the early onset of epithelial damage to the transplanted tissue and recurrence of the underlying disorder. Amniotic membrane transplantation is not able to cure perforated forms of Mooren's ulcer, because it has got very poor tensile strength and does not modify the disease process.[3]

Fascia lata was reported to be used in different eye condition like in necrotizing scleritis[8] for scleral repair, to cover the glaucoma tube. Fascia lata collagen is structurally different from the cornea. So, by covering the perorated Mooren's ulcer, we actually replace the corneal collagen with fascia lata collagen. In this way immune system stop reacting against corneal collagen and inflammation reduces. As inflammation reduces patient's symptoms like pain, photophobia decreases. Fascia lata also provides good tensile strength to perorated area. Fascia lata is readily available tissue and can be harvested easily. There is no chance of rejection as it is harvested from patients own body. The main stay of treatment is to save the globe from being lost; fascia lata grafting appears to be a very successful treatment for perforated Mooren's ulcer.

CONCLUSION

Using autologous fascia lata graft and covering it with conjunctiva in the management of perorated Mooren's ulcer provide good results in saving the eyeball from being lost. It also modifies the disease modality by replacing the type of collagen i.e. corneal collagen with that of fascia lata. Multi-centric study is still required for making that new technique to a standard procedure for the management of perforated Mooren's ulcer.

REFERENCES

1. Sangwan VS, Zafirakis P, Foster CS. Mooren's Ulcer: Current concepts in management. Indian J Ophthalmol, 45: 7-17, 1997
2. Wood T and Kaufman H. Mooren's Ulcer. Am J Ophthalmol 71:417-422, 1971
3. Maurice Schallenberg, Henrike Westekemper, Klaus-Peter Steuhl and Daniel Meller : Amniotic membrane transplantation ineffective as additional therapy in patients with aggressive Mooren's ulcer. *BMC Ophthalmology* 2013, 13:81
4. Jiaqi Chen, Hanping Xie, Zhen Wang, Bing Yang, Zuguo Liu, Longshan Chen, Xiangming Gong, Yuesheng Lin: Mooren's ulcer in China: a study of clinical characteristics and treatment. Br J Ophthalmol 2000, 84: 1244-49.
5. Nian ZD, et al.: Mooren's ulcer treated by lamellar keratoplasty. Jpn J Ophthalmol 1979, 15:290-4.
6. Schaap OL, Feltkamp TEW, Breehart AC: Circulating antibodies to corneal tissue in a patient suffering from Mooren's ulcer (ulcus rodens corneae). *Clin Exp Immunol* 1969, **5:**365-72.
7. Mauro Cellini*, Michela Fresina, Ernesto Strobbe, Corrado Gizzi and Emilio C Campos: Corneoscleral graft in Mooren's ulcer: a case report. *Cases Journal* 2009, **2**:180
8. Lin CP, Su CY. Infectious scleritis and surgical induced necrotizing scleritis. *Eye (Lond)*. 2010;24(4):740

مُبتلائے درد کوئی عضو، ہو روتی ہے آنکھ
کِس قدر ہمدرد ،سارے جسم کی ہوتی ہے آنکھ
اقبالؔ

Javed Iqbal

ORIGINAL ARTICLE

Comparison of IOP alterations following 2mg & 4mg Intravitreal Trimcinolone Acetonide (IVTA) in Clinically Significant Macular Edema (CSME)

Ch. Javed Iqbal FCPS, Fellow Vitreo-Retina[1] ,Najam Iqbal Chaudhary FCPS[2]
Nabeel Shahab MBBS[3]

King Edward Medical University, Institute of Ophthalmology, Mayo Hospital, Lahore

ABSTRACT

Introduction: Triamcinolone acetonide is a synthetic glucocorticoid which is used for the treatment of clinically significant Macular edema. The rise in the intraocular pressure is a main side effect of its use. Ophthalmologists have to out weight the risk of side effects for its use. Our aim in this study is to compare the intraocular pressure (IOP) alterations after giving 2mg and 4mg intravitreal triamcinolone acetonide in patients with clinically significant macular edema (CSME).

Material & Methods: This randomized controlled trial was conducted at Institute of Ophthalmology, Mayo Hospital Lahore. Sample size of 80 cases was included through non-probability purposive sampling technique. All the patients in the study gave informed consent and their demographics were recorded. Pre-injection IOP and general evaluation of patients were done. The cases were randomly divided in two groups. In one group, 2mg intravitreal triamcinolone acetonide was given while in group two, 4mg intravitreal triamcinolone acetonide was given. Patients were followed for 3 months to measure the mean increase in IOP level in both groups.

Results: Patient mean age was 48.68±5.60 years. In this study, there were 45% males while 55% patients were females. In right eye, at baseline the mean value of IOP was 13.48±3.48mmHg. After 3 months the mean value of IOP was 11.69±2.59mmHg with 2mg whereas 14.82±3.88mmHg with 4mg.

Conclusion: It was concluded that 2mg dose of intravitreal triamcinolone acetonide is more beneficial in terms of less increase in IOP as compared to 4mg intravitreal triamcinolone acetonide (IVTA) injection to decrease CSME.

Key words: Intraocular Pressure, IOP, Intravitreal, Triamcinolone Acetonide, Clinically Macular Edema, Diabetic Retinopathy.

INTRODUCTION

Triamcinolone acetonide is used for the treatment of many diseases like central retinal vein occlusion, branch retinal vein occlusion, uveitis, cystoid macular edema after cataract surgery, and age related macular oedema. Reduced vision is most importantly due to macular oedema. The most important side effect of IVTA injection is rise in IOP. Other complication may also include Cataract and endophthalmitis. This study was hypothesized to find out the IOP response to the injection of IVTA with difference concentrations as there are no previous studies done in Pakistan comparing the different concentrations of triamcinolone given intravitreally for diabetic patients with clinically significant macular edema.

[1]Assistant Prof. [2]Senior registrar. [3]Postgraduate Resident

Correspondence: Dr. Ch. Javed Iqbal FCPS, Fellow Vitreo–Retina, 11-A Nursery Lane, Lawrence Road, Lahore. E-mail: drj4eye@yahoo.com, Cell: 0333-4311146

Received: April 2015 Accepted: June 2015

Intravitreal triamcinolone acetonide in 2 mg dosage in clinically significant in macular oedema patients, showed effective results in comparison with 4 mg dosage, is effective and safe for the patient than 4mg dose of IVTA.

***Objective*:** To compare intraocular pressure alterations after giving 2mg and 4mg intravitreal triamcinolone acetonide (IVTA) in patients with CSME.

MATERIAL AND METHODS

This study was conducted at Institute of Ophthalmology; Mayo Hospital Lahore. It was estimated on 80 cases using 95% confidence level, 80% power of test taking an expected mean increase in IOP in 2mg of triamcinolone as 0.8±0.3 and in 4mg triamcinolone as 5.32±5.81 in diabetic patients with CSME. Cases were included through Non-probability purposive sampling technique. Patients of 40 to 60 years of ages with following findings, which indicate the presence of clinically significant macular edema (CSME), as defined by the Early Treatment Diabetic Retinopathy Study (ETDRS).

These findings were checked on slit lamp biomicroscope. History of present illness was obtained with regard to symptoms and duration specially drug and surgical history. The subjects were examined for positive signs. They were investigated by routine tests (blood sugar, hepatitis B & C screening). Baseline IOP was recorded before any intervention. Patients with known glaucomatous (known patient of glaucoma and optic nerve cupping on exam with super 66D Len), new vessels on retina, any glaucoma surgery, on steroids (oral or topical) and already had intravitreal triamcinolone injections were ***excluded***. An informed consent was obtained. Intravitreal injections were given to the patients in routine at our operation theater therefore giving intravitreal triamcinolone acetonide, had no ethical issues. The demographic information like name, age, sex, and address were recorded. IOP was measured with Goldmanns applanation tonometer. Topical anaesthetic and Fluorescein strips are used to view the mires of the tonometer under cobalt blue filter. The mean IOP was recorded in OPD department at 1 week, 1 month and 3 months after IVTA injection. The cases were randomly selected in each group by computer program. The cases were randomly divided in two group. In one group, 2mg IVTA was given while in group two, 4mg IVTA was given. All the data collected, entered and analyzed using SPSS 17. Quantitative data like age, pre and post op IOP levels were presented by mean and standard deviation. Qualitative data like gender were presented by frequency and percentage. Mean increase in IOP a level in both groups were compared by independent sample t test and was used to determine significant difference.

RESULTS

Patients mean ages were 48.68±5.60 years. There were 45% males while 55% patients were females. The male:female ratio was 1:1.2. In this study, right eye of patients, the baseline IOP was 14.55±3.68 mmHg whereas at 1st week, the mean IOP was noted as 13.20±3.18 mmHg. At 1st month, the mean IOP was 13.04±3.68 mmHg whereas at 3rd month, mean IOP was 13.28±3.70 mmHg. Similarly, in left eye of patients, the mean IOP at baseline was 13.26±3.67 mmHg whereas at 1st week, the mean IOP was noted as 13.66±3.27 mmHg. At 1st month, the mean IOP was 13.78±3.64 mmHg whereas at 3rd month, mean IOP was 13.46±3.66 mmHg.

In right eye, at baseline the mean value of IOP was 13.48±3.48mmHg with 2mg whereas 15.48±3.66mmHg with 4mg. The difference was significant (P<0.05). At 3rd month the mean value of IOP was 11.69±2.59mmHg with dose of 2mg whereas 14.82±3.88mmHg with 4mg. No difference was observed (P>0.05). In left eye, at baseline the mean value of IOP was 13.00±3.62mmHg with dose of 2mg whereas 13.52±3.74mmHg with 4mg. The difference was significant (P<0.05). At 3rd month the mean value of IOP was 11.18±2.88mmHg with dose of 2mg whereas 15.75±2.84mmHg with 4mg. The difference was significant (P<0.05).

Table#1: Baseline information

n	80
Age	48.68±5.60
Gender (M/F)	36/44
IOP (R)	14.55±3.68
IOP (L)	13.26±3.67

Table#2: Comparison of IOP from baseline to final visit in both groups with respect to anatomical site of eye

Site	IOP at	Group		p-value
		2mg (n=40)	4mg (n=40)	
Right	Baseline	13.48±3.47	15.62±3.60	0.008*
	3month	11.62±2.60	14.92±3.93	0.526 Ns
Left	Baseline	13.00±3.62	13.52±3.74	0.000*
	3month	11.18±2.88	15.75±2.84	0.000*

Ns = insignificant (P<0.05) * = significant (P<0.05)



Fig#1: Comparison of both groups regarding IOP in right eye at each visit
ANOVA = 1.962E3 (p-value = 0.000 (Significant))



Fig#2: Comparison of both groups regarding IOP in left eye at each visit

ANOVA = 1.793E3 (p-value = 0.000 (Significant)

DISCUSSION

Graham and associates in 1974 used the first intravitreal steroid injection. Corticosteroids have the advantage of repeatability, as long as the IOP and cataract side effects are not significant. IOP elevation after IVTA injection is also a commonly known complication,(6-11) Our study results showed highly significant difference between the giving 2mg and 4mg IVTA in patients with CSME in both right and left eye. According to the principal study[1], Pir Salim Mahar and Abdul Sami Memon increase in IOP more than 21 mmHg was seen in 28 eyes (14.1%) after one week of IVTA. At one month follow-up, a rise in IOP was observed in 48 eyes (24.2%). At three months follow-up, a rise in IOP was observed in 76 eyes (38.4%).[1]

Spandua conducted alike trial and noted that at baseline IOP was 13.76± 2.79 and after three months of treatment 19.8±8.6 and the mean difference was 5.32±5.81.While in 2mg group base line IOP was 14.1±1.4 and after three to twelve months of treatment IOP level was 14.9±1.7 and mean difference of 0.8±0.3.[2]

In our study, in right eye of patients, the baseline IOP was 14.55±3.68 mmHg whereas at 1st week, the mean IOP was noted as 13.20±3.18 mmHg. At 1st month, the mean IOP was 13.04±3.68 mmHg whereas at 3rd month, mean IOP was 13.28±3.70 mmHg. In this study, in left eye of patients, the mean IOP at baseline was 13.26±3.67 mmHg whereas at 1st week, the mean IOP was noted as 13.66±3.27 mmHg. At 1st month, the mean IOP was 13.78±3.64 mmHg whereas at 3rd month, mean IOP was 13.46±3.66 mmHg. The dose 2 mg the less IOP mean values in comparison with 4 mg from baseline to 3rd month of the patients. Different studies were conducted and showed the following outcomes. In right eye, at baseline the mean value of IOP was 13.48±3.48mmHg with dose of 2mg whereas 15.48±3.66mmHg with 4mg. The difference was significant (P<0.05). At 3rd month the mean value of IOP was 11.69±2.59mmHg with dose of 2mg whereas 14.82±3.88mmHg with 4mg. No difference observed. In left eye, at baseline the mean value of IOP was 13.00±3.62mmHg with dose of 2mg whereas 13.52±3.74mmHg with 4mg. The difference was significant (P<0.05). At 3rd month the mean value of IOP was 11.18±2.88mmHg with dose of 2mg whereas 15.75±2.84mmHg with 4mg. The difference was significant (P<0.05).

In right eye, at baseline the mean value of IOP was 13.48±3.48 mmHg with dose of 2 mg whereas 15.48±3.66 mmHg with 4 mg, at 1st week the mean value of IOP was 12.02±2.74 mmHg with dose of 2 mg whereas 14.51±3.11 mmHg with 4 mg, at 1st month the mean value of IOP was 10.53±2.23 mmHg with dose of 2 mg whereas 15.21±3.36 mmHg with 4 mg, and at 3rd month the mean value of IOP was 11.69±2.59 mmHg with dose of 2 mg whereas 14.82±3.88 mmHg with 4 mg. Huge difference was observed in both groups for mean IOP in right eye of patients i.e. p-value=0.000.

In left eye, at baseline the mean value of IOP was 12.69±3.71 mmHg with dose of 2 mg whereas 13.43±3.65 mmHg with 4 mg, at 1st week the mean value of IOP was 12.15±3.45 mmHg with dose of 2 mg whereas 14.80±2.60 mmHg with 4 mg, at 1st month the mean value of IOP was 11.10±2.57 mmHg with dose of 2 mg whereas 15.92±2.57 mmHg with 4 mg, and at 3rd month the mean value of IOP was 10.76±2.56 mmHg with dose of 2 mg whereas 15.85±2.92 mmHg with 4 mg. Remarkable difference was observed in mean IOP in left eye of patients i.e. p-value=0.000. Gul Arikan et al concluded that due to increase in volume of 4mg there was increase in the rise in IOP with 4mg than 2mg of IVTA injection. Increase in IOP was observed more in smaller eyes.

CONCLUSION

According to our study results the dosage 2 mg in treatment of intravitreal triamcinolone acetonide in clinically significant macular oedema patients showed effective results in comparison with 4 mg dosage. We conclude that 2mg is effective and safe for the patient than 4mg dose of IVTA.

REFERENCES

1. Mahar PS, Memon AS. Frequency and management of raised intraocular pressure following intravitreal triamcinolone acetonide. J Coll Physicians Surg Pak. 2012;22:699-702.
2. Spandau U, Derse M, Schmitz-Valckenberg P, Papoulis C, Jonas J. Dosage dependency of intravitreal triamcinolone acetonide

as treatment for diabetic macular oedema. British journal of ophthalmology. 2005;89(8):999-1003.
3. Chuang LH, Yeung L, Wang NK, Chen HS, Ku WC, Lai CC. Secondary ocular hypertension after intravitreal injection with 2 mg or 4 mg of triamcinolone in retinal vein occlusion. J Ocul Pharmacol Ther. 2010;23(5):675-81.
4. Graham RO, Peyman GA. Intravitreal injection of dexamethasone: treatment of experimentally induced endophthalmitis. Archives of ophthalmology. 1974;92(2):149-54.
5. Rudoler SB, Corn BW, Shields CL, Potter PD, Hyslop T, Shields JA, et al. External beam irradiation for choroid metastases: identification of factors predisposing to long-term sequelae. International Journal of Radiation Oncology* Biology* Physics. 1997;38(2):251-6.
6. Oh J, Wee W, Lee J, Kim M. Short-term effect of intracameral triamcinolone acetonide on corneal endothelium using the rabbit model. Eye. 2006;21(6):812-8.
7. Jonas J, Kreissig I, Kamppeter B, Degenring R. [Intravitreal triamcinolone acetonide for the treatment of intraocular edematous and neovascular diseases]. Der Ophthalmologe: Zeitschrift der Deutschen Ophthalmologischen Gesellschaft. 2004;101(2):113-20.
8. Jonas J, Kreissig I, Degenring R. Intraocular pressure after intravitreal injection of triamcinolone acetonide. British journal of ophthalmology. 2003;87(1):24-7.
9. Bakri SJ, Beer PM. The effect of intravitreal triamcinolone acetonide on intraocular pressure. Ophthalmic surgery, lasers & imaging: the official journal of the International Society for Imaging in the Eye. 2002;34(5):386-90.
10. Kaushik S, Gupta V, Gupta A, Dogra MR, Singh R. Intractable glaucoma following intravitreal triamcinolone in central retinal vein occlusion. American journal of ophthalmology. 2004;137(4):758-60.
11. In YS, Kim JH, Uhm KB. The effect of intravitreal triamcinolone acetonide on intraocular pressure. Journal of the Korean Ophthalmological Society. 2004;45(7):1075-80.

کہتے ہیں فرشتے کہ دل آویز ہے مومن
حُوروں کو شکایت ہے کہ کم آمیز ہے مومن
اقبالؒ

Javed Iqbal

ORIGINAL ARTICLE

Comparison of Success of Phaco-trabeculectomy versus Trabeculectomy in the Treatment of Primary Angle Closure Glaucoma (PACG)

Ch. Javaid Iqbal FCPS Fellow Vitreo–Retina[1], Muhammad Salman Hamza FCPS[2]
Rafih Razzaq Wattoo MBBS[3], Qunbar Abbas Chaudhry FCPS[4]

King Edward Medical University, Institute of Ophthalmology, Mayo Hospital, Lahore

ABSTRACT

Objective: To compare the success of phacotrabeculectomy versus trabeculectomy for the treatment of primary angle closure glaucoma.

Material and Method: A total of 40 patients, above 40 years of age without gender discrimination having primary angle closure glaucoma were included in the study. Patients with secondary glaucoma and intraocular surgery were excluded. Then selected patients were randomly divided into two groups, Group A (Phacotrabeculectomy) and Group B (Trabeculectomy), by using lottery method. Outcome variables like decrease in IOP were noted at the end of three months.

Results: Mean age of patients in Group-A and Group-B was 61.30±11.81 and 62.70±11.29 years. Gender distribution of patients showed that there were 23(57%) female and 17(43%) were male patients. There were 18(90%) patients in Group-A and 12(60%) patients in Group-B who had successful (intraocular pressure (IOP) <15 mmHg at the end of three months) outcome. In terms of p-values success rate of Group-A was high as compared to Group-B treatment (p-value=0.028).

Conclusion: Results of this study showed that phacotrabeculectomy is more effective as compared to that trabeculectomy for treating primary angle closure glaucoma patients.

Key Words: Primary angle closure glaucoma, Phacotrabeculectomy, Trabeculectomy, Intra ocular pressure.

INTRODUCTION

Glaucoma encompasses a diverse group of ocular disorders and all forms have in common intraocular pressure-associated optic neuropathy.[1] The treatment of Primary angle closure glaucoma (PACG) consists of lowering of intra ocular Pressure (IOP), reduction of inflammation, and angle closure reversal. After diagnoses, the initial treatment includes topical or systemic carbonic anhydrase inhibitors, beta-blocker and steroid.[2] When medical therapy proves to be ineffective, corneal indentation (CI) can be used as a temporizing measure to reduce IOP until definitive treatment is available.[3] Therefore, lowering of IOP is basic in protection of visual function in patients of PACG.[4] By making an artificial outflow pathway to the ocular surface, trabeculectomy has become basic surgical procedure for IOP reduction in primary angle closure glaucoma.[5] In 1968 Cairns, introduced trabeculectomy, which remains the standard procedure for the IOP control in medically uncontrolled glaucoma patients worldwide.[6] Before the development of the trabeculectomy, the available surgical methods of intraocular pressure (IOP) reduction had a high rate of serious complications like hypotony, shallow anterior chamber and endophthalmitis. Thus, in an effort to improve the safety of IOP-lowering surgery, the guarded filtering procedure was developed.[7] It was reported that in patients with co-existent cataract and primary angle closure glaucoma IOP reduction can occur after the cataract surgery. In some cases with primary angle closure glaucoma, intraocular pressure reduction was not sufficient for neuronal protection, and many patients are in need of IOP lowering drugs and glaucoma filtration surgery to control IOP. In such cases, cataract and glaucoma surgery were combined in one procedure called phacotrabeculectomy is reasonable option.[8] By keeping this concept, already existing studies have shown that phacotrabeculectomy could significantly lower intraocular pressure and improve visual acuity in patients of PACG and significant cataract. But phacotrabeculectomy may increase inflammatory response, high frequency of postoperative complications such as hyphema and

[1]Assistant Prof. [2]Ophthalmologist, Eye Unit. [3]Postgraduate Resident [4]Senior Registrar Unit:2

Correspondence: Dr. Ch. Javed Iqbal FCPS, Fellow Vitreo–Retina, 11-A, Nursery Lane, Lawrence Road, Lahore. E-mail: drj4eye@yahoo.com, Cell: 0333-4311146

Received: April 2015 Accepted: June 2015

inflammatory response in the anterior chamber, endophthalmitis, and more scarring of the filtering bleb. Thus, it is not clear which process phacotrabeculectomy or trabeculectomy is effective and safe in intraocular pressure control for PACG patients.[9] Study by Mei W et al[10] highlights the success of phacotrabeculectomy as 88% and trabeculectomy as 71% in the treatment of PAGC.

Objective: To compare the success of phacotrabeculectomy versus trabeculectomy in treatment of primary angle closure glaucoma.

Phaco-trabeculectomy is more effective as compared to trabeculectomy for treating primary angle closure glaucoma (PACG) patients and it should be used routinely as a primary surgical procedure in PACG.

MATERIAL AND METHOD

This was a randomized controlled trial conducted at Institute of Ophthalmology, King Edward Medical University, Mayo Hospital Lahore, for a period of one year starting from July 2013. In this study 40 patients were included. After obtaining demographic data, complete history, slit lamp examination, applanation tonometry and gonioscopy was carried out. Laboratory investigation was done to rule out any associated systemic disease like diabetes, hypertension. Procedure was completely described to the patients and informed consent was obtained. All patients had angle closure, peripheral anterior synechiae (PAS) and an intraocular pressure more than 21 mmHg on Goldman applanation tonometer. Patients who had previous ocular surgery even laser iridectomy and secondary glaucoma were excluded. Treatment allocations to the patients were done by using lottery method. Group A patients were undergone phacotrabeculectomy while group B patients underwent trabeculectomy. In trabeculectomy procedure, fornix-based conjunctival flap fashioned superiorly combined with 0.25 mg/ml mitomycin-C (MMC) for 3 to 5 minutes. The scleral flap rectangular in shape was sutured at its posterior corner with 10-0 nylon sutures. In phacotrabeculectomy all the steps of trabeculectomy was performed with fornix based conjuctival flap and for phacoemulsification 3.2-mm sclera tunnel incision given. This was also combined with 0.25 mg/ml mitomycin-C (MMC) for 3 to 5 minutes. All patients were followed for 3 months and final success was noted at the end of 3 months as follows;

- "YES" if IOP was <15 mmHg &
- "NO" if IOP was ≥ 15mmHg

Data Analysis: Data analyzed by SPSS version 20.0. Mean±SD was calculated for age and duration of disease. Frequencies and percentages were calculated for qualitative variables like gender and success (yes/no). Comparison between the groups with respect to success was analyzed by chi square. P-value ≤0.05 was considered as significant.

RESULTS

In Group-A and in Group-B mean age of patients was 61.30±11.81 and 62.70±11.29 years. Gender distribution of patients showed that there were 23(57%) female and 17(43%) were male patients. There were 18(90%) patients in Group-A and 12(60%) patients in Group-B who had successful (Intraocular pressure (IOP) <15 mmHg at the end of three months) outcome. In terms of p-value Success rate of Group-A was high as compared to Group-B treatment (p- value=0.028).

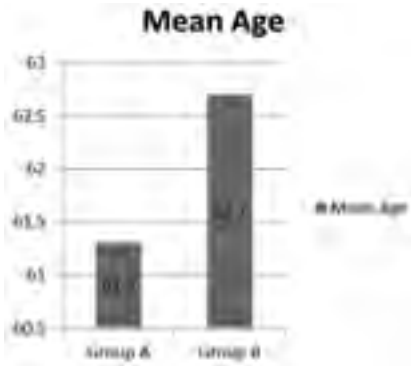



DISCUSSION

Appositional or synechial closure of the angle causes impaired outflow facility leading to raised intraocular pressure in angle closure glaucoma. Pupillary block is the underlying mechanism in primary angle closure glaucoma while secondary angle closure glaucoma is caused by push of the iris forward from behind or pull of the iris forward to contact trabecular meshwork.[11,12] In early stages Glaucomatous damage is present and the disease is asymptomatic. Acute angle-closure occurs with progressive PAS formation affected by pupillary block that closes the remaining portion of the angle. However, many patients in the absence of symptoms develop gradual angle-closure, PAS, elevated IOP, and glaucomatous damage. An acute angle-closure attack may result in CACG.[13,14]

For the diagnosis of primary and secondary forms, a thorough history and eye examination are mandatory. For the treatment this difference is crucial. Intraocular pressure lowering drugs and laser peripheral iridotomy for pupillary block are the mainstays of therapy. For vision threatening angle closure glaucoma early diagnosis and appropriate management can stabilize disease and slow down vision loss.[15,18] The main therapy of primary angle closure glaucoma is surgery. For treating primary angle closure glaucoma trabeculectomy, phacotrabeculectomy plus intraocular lens implantation (phacotrab+IOL group) and phacoemulsification with IOL (phaco+IOL) are commonly performed. But some controversies exists in efficacy, safety and complications.[19,23] In a retrospective study done in Taiwan, the success rate (intraocular pressure <15 mmHg) was found to be 45% and 54% in the phacotrabeculectomy group and trabeculectomy group respectively which is not a significant difference. Similarly, no significant difference was found between post- operative complications in both groups (p=0.232).

Additional IOP-lowering surgeries was not required in phacotrabeculectomy but trabeculectomy group with 54% eyes required additional IOP-lowering surgeries like cataract extraction with P value of 0.001.[5] In another retrospective study done on 60 eyes (43 patients) treated with phacotrabeculectomy in which 60% of eyes had found intraocular pressure less than 21 mm Hg with or without medication, 50% of eyes had achieved intraocular pressure equal or less than 15 mm Hg, and 57% of eyes had lowering of IOP at least 30%.[24] Francis BA et al in his study observed the significant reduction of IOP after phacotrabeculectomy in PACG patients.[25] Zhang X et al[26] in retrospective study claimed success rate of (78.57%) and (81.08%) of phacotrabeculectomy and trabeculectomy groups respectively in primary angle closure glaucoma.. In study by Mei W et al[10] reported the success rate 88% and 71% of phacotrabeculectomy and trabeculectomy respectively in the treatment of PACG. Murthy SK et al[27] in his retrospective cohort study in which 85 PACG patients treated by trabeculectomy and 105 glaucomatous eyes underwent phacotrabeculectomy with MMC has shown trabeculectomy better compared to phacotrabeculectomy and concluded that mean reduction in IOP was greater in the trabeculectomy group (-10.87 ±8.33 mm Hg) compared to phacotrabeculectomy group (-6.15 ±7.01 mm Hg) at 2 years (P = 0.003). Kaplan-Messas A et al[28] compared the one year outcome of trabeculectomies with or without peripheral iridectomy compared to phacotrabeculectomies with or without peripheral iridectomy. Complete success rates was found to be 90% in phacotrabeculectomy group and 70% in trabeculectomy group which is statistically significant difference.

Deng BL et al[29] in a meta analysis concluded phacotrabeculectomy plus intraocular lens group was successful than trabeculectomy group which was also successful than phacoemulsification intraocular lens group in reducing intraocular pressure. In the anterior chamber depth phacotrabeculectomy and phacoemulsification groups are deeper than trabeculectomy group. With respect to glaucoma medication phacotrabeculectomy group was successful than phacoemulsification group. On the whole it is concluded that success (intraocular pressure <15 mmHg at the end of three months) of phacotrabeculectomy is higher compared to trabeculectomy for the treatment of primary angle closure glaucoma.

CONCLUSION

Results of this study showed that phacotrabeculectomy is more effective as compared to that trabeculectomy for treating primary angle closure glaucoma patients. So based on this study it is recommend that phacotrabeculectomy should be used routinely as a primary surgical procedure in primary angle closure glaucoma in order to protect the visual functions

REFERENCES

1. Casson RJ, Chidlow G, Wood JPM, Crowston JG, Goldberg I. Definition of glaucoma: Clinical and experimental concepts. Clinic Experimental Ophthalmol. 2012;40(4):341–9.
2. Kramer P, Ritch R. The treatment of acute angle-closure glaucoma revisited. *Ann Ophthalmol*. 1984;16(12):1101-3.
3. Lam D, Tham C, Lai J. Current approaches to management of acute primary angle closure. *Curr Opinion Ophthalmol*. 2001;18:146-151.
4. Quigley HA. Angle-closure glaucoma – simpler answers to complex mechanisms: LXVI Edward Jackson Memorial

Lecture. Am J Ophthalmol. 2009;148(5):657-69.
5. Tsai HY, Liu CJ, Cheng CY. Combined trabeculectomy and cataract extraction versus trabeculectomy alone in primary angle-closure glaucoma. Br J Ophthalmol. 2009;93:943-8.
6. Senthil S, Rao HL, Babu JG, Mandal AK, Garudadri CS. Comparison of outcomes of trabeculectomy with mitomycin C vs. ologen implant in primary glaucoma. Indian J Ophthalmol. 2013;61:338-42.
7. Sihota R, Gupta V, Agarwal HC. Long-term evaluation of trabeculectomy in primary open angle glaucoma and chronic primary angle closure glaucoma in an Asian population. Clin Experiment Ophthalmol. 2004 Feb;32(1):23-8.
8. Hayashi K, Hayashi H, Nakao F, Hayashi F. Effect of cataract surgery on intraocular pressure control in glaucoma patients. J Cataract Refract Surg. 2001 Nov;27(11):1779-86.
9. Kim JW, Jung CI, Hwang HS. Comparative study of three phacotrabeculectomy procedures through a single incision. Korean J Ophthalmol. 1998 Jun;12(1):30-6.
10. Mei W, Min F, Yu-jing B, Wei-zhong Z, Ming-kai L, Bing-qian L, et al. Comparison of combined phacotrabeculectomy with trabeculectomy only in the treatment of primary angle-closure glaucoma. Chin Med J. 2012;125(8):1429-33.
11. Edwards RS. Behaviour of the fellow eye in acute angle-closure glaucoma. Br J Ophthalmol. 1982;66:576–579.
12. Lowe RF. Primary angle-closure glaucoma. Prevention and early treatment. Isr J Med Sci. 1972;8:1362–1365.
13. Alsagoff Z, Aung T, Ang LP, Chew PT. Long-term clinical course of primary angle-closure glaucoma in an Asian population. Ophthalmology. 2000;107:2300–2304.
14. Yoon JY, Hong YJ, Kim CY. Cataract surgery in patients with acute primary angle-closure glaucoma. Korean J Ophthalmol. 2003;17:122–126.
15. Rahim SA, Sahlas DJ, Shadowitz S. Blinded by pressure and pain. *Lancet*. Jun 25-Jul 1 2005;365(9478):2244.
16. Cholongitas E, Pipili C, Dasenaki M. Acute angle closure glaucoma presented with nausea and epigastric pain. *Dig Dis Sci*. May 2008;53(5):1430-1.
17. Palmberg P. Shedding light on gonioscopy. Arch Ophthalmol. 2007;125:1417–1418.
18. Barkana Y, Dorairaj SK, Gerber Y. Agreement between gonioscopy and ultrasound biomicroscopy in detecting iridotrabecular apposition. Arch Ophthalmol. 2007;125:1331–1335.
19. Jain I, Gupta A, Dogra M. Surgery in angle closure glaucoma: Late complications. Glaucoma. 1984;6:54–57.
20. Tham CC, Leung DY. Effects of phacoemulsification versus combined phaco-trabeculectomy on drainage angle status in primary angle closure glaucoma (PACG). J Glaucoma. 2010;19(2):119-23.
21. Tsai HY, Liu CJ, Cheng CY. Combined trabeculectomy and cataract extraction versus trabeculectomy alone in pimary angle-closure glaucoma. Br J Ophthalmol. 2009;93(7):943-8.
22. Tham CC, Kwong YY. Phacoemulsification versus combined phacotrabeculectomy in medically uncontrolled chronic angle closure glaucoma with cataracts. Ophthalmology. 2009;116(4):725-31, 731.e1-3.
23. Tham CC, Kwong YY. Phacoemulsification vs phacotrabeculectomy in chronic angle-closure glaucoma with cataract complications. Arch Ophthalmol. 2010;128(3):303-11.
24. Jin GJ, Crandall AS, Jones JJ. Phacotrabeculectomy:assessment of outcomes and surgical improvements. J Cataract Refract Surg. 2007;33(7):1201-8.
25. Francis BA, Minckler D, Dustin L. Combined cataract extraction and trabeculotomy by the internal approach for coexisting cataract and open-angle glaucoma: initial results. J Cataract Refract Surg. 2008;34(7):1096-3.
26. Zhang X, Teng L, Li A, Du S, Zhu Y, Ge J. The clinical outcomes of three surgical managements on primary angle-closure glaucoma. Eye Sci. 2007;23:65-74.
27. Murthy SK, Damji KF, Pan Y, Hodge W. Trabeculectomy and phacotrabeculectomy, with mitomycin-C, show similar two-year target IOP outcomes. Can J Ophthalmol. 2006;41(1):51-9.
28. Kaplan-Messas A, Cohen Y, Blumenthal E, Avni I. Trabeculectomy and phaco-trabeculectomy with and without peripheral iridectomy. Eur J Ophthalmol. 2009;19(2):231-4.
29. Deng BL, Jiang C, Ma B, Zhang WF, Lu P, Du YY, et al. Surgical treatment for primary angle-closure glaucoma: a meta analysis. Int J Ophthalmol. 2011;4(3):223-7.

سکُوں نہ ڈھونڈ، سکُوں تو ہے موت کا پیغام
تُو زندگی کے لئے اضطراب پیدا کر
اقبالؔ

Sarfraz Latif

ORIGINAL ARTICLE

Frequency of Ocular Findings in Patients of Xeroderma Pigmentosum presenting in Eye Department

Sarfraz Latif FCPS[1], Ch. Javed Iqbal FCPS, Fellow Vitreo-Retina[2], Abdus Samad MBBS[3]
Prof. Imran Akram Sahaf FRCS[4]

**King Edward Medical University, Institute of Ophthalmology,
Mayo Hospital, Lahore**

ABSTRACT

Purpose: To find out the frequency of ophthalmological pathologies and their sign/symptoms purely associated with Xeroderma Pigmentosum in patients presenting to ophthalmology department.

Methodology: We studied 32 eyes of 16 patients of Xeroderma Pigmentosum from March 2014 to April 2015 in Institute of Ophthalmology, Mayo Hospital, Lahore. In this cross sectional study, all patients were recruited by non-probability purposive sampling technique after taking informed consent. Diagnosis was purely clinical by the help of dermatologist. Complete ophthalmological examination of all patients was done by the help of torch, slit lamp, direct ophthalmoscope, indirect ophthalmoscope, retinoscope and sometimes by microscope. Any patient requiring any ophthalmological manipulation was admitted and managed accordingly. All patients and their attendants were counseled properly for prophylaxis and prevention of complications.

Results: Data was collected in 32 eyes of 16 patients. Age ranges from 3-60 years with median age of 20 year with equal gender distribution. Clinical abnormalities such as photophobia, irritation, watering, bloodshot, darkening of skin and skin freckles were present in all eyes (100%) of patients.Corneal haziness in 20 eyes (62.5%). Conjunctival and lid masses presented in 16 eyes (50%). Orbital involvement and requirement of exenteration in 10 eyes (31.5%) and 5 eyes(15.6%). All pathologies presented more in right eye.

Conclusion: We concluded that all patients of Xeroderma Pigmentosum are at high risk of developing ocular complications which can be fatal and decrease life span of patients, so they need frequent visits, dedicated follow-up, multiple surgeries, psychosocial care and proper referral.

INTRODUCTION

Xeroderma Pigmentosa (XP) is an autosomal recessive disease due to deficiency of endonuclease, polymerase and sometime ligases which are enzyme needed for DNA repair.[1] Ultraviolet (UV) radiations continuously damage DNA,while deficient DNA repair during cell multiplication results in mutation leading to carcinogenesis. Detailed description of XP was given by Hebra and Maritz Kaposi in 1874 and in 1982, Kaposi named it referring to its characteristic dry and pigmented skin.[2] It is usually detected at 1 or 2 years of age while median age to develop skin cancer is 8 years.[3] Less than 40% of individuals with XP survive beyond age 20 years but those with milder disease may survive beyond middle age. Its prevalence is round 1 in 40,000 and six times more common in Japanese people than in other groups.[3]

[1,3]Medical Officers.[2]Assistant Professor. [4]Professor of Ophthalmology

Correspondence: Dr. Sarfraz Latif FCPS, Eye Unit-I, Institute of Ophthalmology,Mayo Hospital, Lahore. E-mail: rednucleus205@hotmail.com, Cell: 0322-6613860

Received: April 2015 Accepted: June 2015

There is a wide spectrum of disease severity depending upon gene involved but for convenience it is classified into mild, moderate and severe variety. Disease process is worst in areas of rapid cell division and exposed to UV light. Exposed areas such as face, hand, foot, eyelids and conjunctiva are especially prone to disease so, premature aging of skin, lips, eyes, and mouth occur. UV radiation also produces immunosuppressive effect; deplete Langerhans cells and defective cell-mediated immunity in skin that may play role in pathogenesis of XP.[2] Basic cells which have been reported as showing abnormality are fibroblasts, lymphocytes and all conjunctival cells.[4]

The disease progresses through 3 stages without clear cut borderlines. Usually, before 6 month of age the skin is healthy but afterward first stage is characterized by diffuse erythema, scaling, and freckle like areas of hyperpigmentation over light-exposed areas. In second stage there is poikiloderma, which consists of skin atrophy, telangiectasis, and mottled skin just like radio dermatitis. Third stage characterized by numerous malignancies such as squamous cell carcinomas, malignant melanoma, basal cell carcinoma, and

fibrosarcoma which can occur at the age of 4 years especially in exposed areas.[5]Clinically XP present with freckling and burns of skin, photophobia, bloodshot, cutaneous and ocular changes. Ocular problems occur in almost 80% of patients with xeroderma pigmentosum[6]. Conjunctiva and cornea are more prone to develop complications due to continuous exposure to UV light, absence of protective melanin, absence of keratin and speedy mitosis. The eye problems start with irritation, photophobia and conjunctival hyperemia (bloodshot) then solar lentigines appear on lids which later on might transform into malignant melanomas.[5]

Skin burns and atrophy lead to non-healing skin ulcers, ectropion and symblephron. Frequent conjunctival inflammation, infections, ulcers and scarring may lead to entropion, shortening of fornices, pterygia, pannus of the cornea, corneal ulcers, corneal opacification, epitheliomas and tumors of lids, conjunctiva and cornea may occur.[7,8] Carcinomas such as squamous cell carcinoma, basal cell carcinoma, malignant melanoma, sebaceous cell carcinoma and fibro-sarcoma are most frequently occurring tumors in xeroderma pigmentosum.[5]

All patients of Xeroderma Pigmentosum are at high risk of developing ocular complications which can be fatal or may decrease the life span of patients. They need frequent visit, dedicated follow-up, multiple surgeries and psychosocial care.

METHODOLOGY

We studied 32 eyes of 16 patients of XP from March 2014 to April 2015 in Institute of Ophthalmology, Mayo Hospital, Lahore. In this cross sectional study, all patients were recruited by non-probability purposive sampling technique after taking informed consent. Diagnosis was purely clinical by the help of dermatologist. Most of patients were already under care of dermatologist but now seeking ophthalmological advice. Complete ophthalmological examination of all patients was done by the help of torch, slit lamp, direct ophthalmoscope, indirect ophthalmoscope, retinoscope and sometimes by microscope. All data was put into preformed proforma and then analyzed. Any patient requiring ophthalmological manipulation was admitted and managed such as mass excision, lid release, lids formation, corneal conjunctival flaps and exenteration. Depending upon the condition of patients, clinical examination calls were sent to dermatologist, neurologist, paediatric physician and oncologist for management. All patients and their attendants were counseled properly to avoid patients from sun exposure, use of shading goggles, long sleeves, long pants, gloves, socks and caps. According to severity of problem, we classified all patients into mild, moderate and severe category.

Severity	Clinical findings
Mild	Light brown freckles on face
Moderate	Dark brown freckles on face, burning on exposed parts of the body Photophobia
Severe	Serious dark brown freckles, burning on exposed/ unexposed parts of the body, cutaneous changes, ocular changes

RESULTS

Data was collected in 32 eyes of 16 patients in outpatient department in point time at presentation. Age ranges from 3–60 years with median age of 20 year with equal gender distribution. Youngest patient was 3 years old with sever ocular findings such as squamous cell carcinoma of left conjunctiva and basal cell carcinoma of left lid which were excise and biopsy proved the diagnosis. The eldest patient was 60 years old presented to us with basal cell carcinoma of both lateral canthi. All patients presented to us were under care of any dermatologist. Some patients were referred by dermatologist, while other came directly to seek ophthalmological advice.

All patients (100%) had photophobia, irritation, watering, bloodshot, blepharitis, darkening of skin and skin freckles whilecorneal haziness due to scarring, pannus, telangiectasia, pterygia, edema and limbal masses encroaching cornea was found in 20 eyes (62.5%). Blister like papules which were excoriating, raised, brown to black in colour, mostly dry and non-tender with different number were present on face and lids of all patients. Fibrous scarring and skin atrophy produced lid ectropion in 5(16%) lids. Some ulcerated and wet lesions were excised and biopsied with high suspicion of malignancy. Biopsy oflid masses proved malignancy in 16 eyes (50%), which were basal cell carcinomas in 10 eyes (62.5% of all masses), mixed basal and squamous cell carcinoma in 3 eyes (18.75%), purely squamous cell carcinoma in 2 eyes (12.5%) while one lesion was malignant melanoma. Excisional biopsy of conjunctival masses proved non-malignant lesions in some cases such as naevus, fibro vascular pterygia, pinguecula, symblepharon, and granulomas but 16 eyes (50%) showed malignancy. We also considered the results of any previous biopsy which was taken and proved malignancy at the time of presentation or occurred during the period of study in follow-ups.

Malignant conjunctival lesions were present either in bulbar (69%) or palpebral conjunctiva (31%), out of which 15(94%) were squamous cell carcinomas and one was malignant melanoma. Orbital involvement by malignant lesions and requirement of exenteration was found in 10 eyes (31.5%) and 5 eyes (15.6%) respectively. All pathologies were present more frequently in right eyes as given below in table.

Signs and symptoms	Severity			Total	Right	Left
	MILD	MOD	SEVERE			
Photophobia, irritation, watering, bloodshots, blepharitis, dark skin	4(12.5%)	20(62.5%)	8(25%)	32(100%)	16(50%)	16(50%)
Skin freckles	4(12.5%)	20(62.5%)	8(25%)	32(100%)	16(50%)	16(50%)
Conjunctival freckles	4(12.5%)	6(18.8%)	16(50%)	26(81.3%)	16(50%)	8(25%)
Corneal haziness	4(12.5%)	6(18.8%)	10(31.3%)	20(62.5%)	14(43.8%)	6(18.8%)
Ectropion lower lid				5(15.6%)	3(60%)	2(40%)
Conjunctival mass (Malignant)				20(62.5%)	12(37.5%)	8(25%)
Lid mass (Malignant)				16(50%)	10(31.3%)	6(18.8%)
Orbit involvement				10(31.3%)	8(25%)	2(6.25%)
Requirement of exenteration				5(15.6%)	3(60%)	2(40%)

Data Summery

DISCUSSION

Incidence of XP is approximately 1 in 250,000 population.[9] Exact pathogenesis is not fully known in all types but awell-established process of Nucleotide Excision Repair(NER) play an important role in removal and replacement of damaged DNA by ultraviolet radiation.[10] After detection of DNA damage an open complex is formed with the help of different genes especially XPG, XPB and XPD. Subsequently, damaged DNA is removed with the help of XPG and XPF which encodes different endonucleases or components of endonucleases which are mediators of NER system.[2] NER is helped by almost eight genes XPA-XPG and XP dominant; defect of anyone can lead to XP with different frequency and severity.[11]

Literature review shows that ocular abnormalities in XP occur in nearly 80% of patients.[6] In a large study, Brooks BP et al showed that 91% patients with XP have at least one ocular abnormality but lesser percentage have multiple abnormalities.[12] This data was collected from dermatology departments where almost all patients even with mild variety of XP without ocular abnormalities may present, but in ophthalmological department only those patients who are facing ocular problem present. So, our all patients (100%) were having ocular problems such asphotophobia, irritation, watering, bloodshot, darkening of skin and skin freckles.

Brooks BP et al showed that corneal haziness due to neo-vascularization (pannus) and scarring occur in almost 60-70% of patients while lid ectropion occur in (25%) of all patients.[12] These results are almost similar to our study which showed results of 64.5% and 31% respectively. Similarly Panday AN et al[13] described that lid tumors and conjunctival tumors can occur in 30% and 20% eyes, which is less frequent than our finding not only due to above given reason but also we considered the old biopsy reports or tumors occurring during the period of study in any follow-up visit. Delayed presentation with frequent complications is also affected by literacy rate,socioeconomic, psychosocial, availability of resources and counseling which are lacking in our society.

In our study orbital involvement, mainly through medial canthus and lower fornix was found in 31.3% cases which is alarming figure and require proper and in time management. Frequent involvement of right eye with any complication is an unusual finding in our study. There is no previous data available except case reports regarding this finding so, require further evaluation in a large study.

XP is unavoidable and untreatable but prophylaxis against the disease or complications can be done by genetic counseling and U-V protection respectively. U-V radiation protection can be done by physical and chemical methods.[11] Sunscreen chemicals such as para-amino benzoic acid, benzophenones, avobenzone, PABA esters, salicylates, and cinnamates can protect from U-V Radiations but this protection is always partial, so physical methods should also be used in conjunction. Physical protection can be done by proper clothing (long sleeves, long pants, cap, goggles, gloves and socks) or special suits containing large particles, such as titanium dioxide, zinc oxide, red ferric oxide, talc, and kaolin. Studies have also shown some promising results of 5-Fluorouracil, oral retinoids, Vitamin D and topical DNA repair enzyme in decreasing the incidence of skin cancer in patients with XP.[11]

Frequent visits to dermatologist, neurologist, psychiatrist, pediatrician and ophthalmologist, extensive target based counseling, proper and in-time referral and immediate medical or surgical management of complications may play key role in reduction of complications and increase in average life span of patients with less morbidity.

CONCLUSION

We concluded that all patients of Xeroderma Pigmentosum are at high risk of developing ocular complications which can be fatal and decrease life span of patients, so they need frequent visit, dedicated follow-up, multiple surgeries, psychosocial care and proper referral.

REFRENCES

1. Lehmann AR. The xerodermapigmentosum group D (XPD) gene: one gene, two functions, three diseases. Genes & Dev. 2001. 15: 15-23. doi:10.1101/gad.859501
2. Pradhan E, Padhye SB, Malla OK, Karki KJD. Case of xerodermapigmentosum with well differentiated squamous cell carcinoma in the eye. Kathmandu University Medical Journal 2003. 1: 4: 278-283
3. Halpern J, Hopping B, Brostoff JB. Photosensitivity, corneal scarring and developmental delay: XerodermaPigmentosum in a tropical country. Cases Journal 2008. 1:254 doi:10.1186/1757-1626-1-254
4. Pathy S, Naik KK, Bhasker S, Sharma MC, Julka PK, Rath JK. Squamous cell carcinoma of face with xerodermapigmentosa – A Case Report. Indian journal of medical &paediatric oncology 2005. 26: 1.
5. Sethi M, Lehmann AR, Fassihi H. Xerodermapigmentosum: a multidisciplinary approach. EMJ Dermatol. 2013;1:54-63.
6. Koley S, Choudhary SV, Choudhury S, Sharma S, Mukherjee T, Khan K. Xerodermapigmentosum: report of two cases and review of the literature. Journal of Pakistan Association of Dermatologists 2012;22:279-282
7. Ahmad E. Comprehensive Manual of Ophthalmology. Jaypee-Highlightes, 1st Edit 2011: 309
8. Ramkumar HL, Brooks BP, Cao X, Tamura D, Digiovanna JJ, Kraemer KH, Chan CC. Ophthalmic manifestations and histopathology of xerodermapigmentosum: two clinicopathological cases and a review of the literature. SurvOphthalmol. 2011;56:348-61. doi: 10.1016/j.survophthal.2011.03.001.
9. Knaemer KH, Lee MM, Scotto J.Xerodermapigmentosum – cutaneous, ocular and neurologic abnormalities in 830 published cases. Arch Dermatol 1987;123:241-50
10. Idrees N, Chaudhry TA, Arsalan. Four Cases of XerodermaPigmentosum in a Pakistani Family. Pak J Ophthalmol 2014: 30: 4
11. Mareddy S, Reddy J, Babu S, Balan P. Review Article: XerodermaPigmentosum: Man Deprived of His Right to Light. The Scientific World Journal 2013 (2013), Article ID 534752, 8 pages. http://dx.doi.org/10.1155/2013/534752.
12. Brooks BP, Thompson AH, Bishop RJ, Clayton JA, Chan CC, Tsilou ET et al. Ocular manifestations of xerodermapigmentosum: Long-term follow-up highlights the role of DNA repair in protection from sun damage. Ophthalmology. 2013; 120: 1324–1336.doi: 10.1016/j.ophtha.2012.12.044.
13. Pandey AN, Kuldeep K, Koul A, Tyagi M, Singh P, Sharma PD,Dimri D. Xerodermapigmentosa with ocular association: Case report. Case Reports in Clinical Medicine 2 (2013) 466-469. Vol.2, http://dx.doi.org/10.4236/crcm.2013.28123.

پرواز ہے دونوں کی اِسی ایک فضا میں
کرگس کا جہاں اور ہے ، شاہین کا جہاں اور
اقبالؔ

Mohammad Alam

ORIGINAL ARTICLE

Recovery of Visual Acuity after Cataract Extraction with Intraocular Lens Implantation in Phacomorphic Glaucoma

(A Study of 48 Cases)

Mohammad Alam FCPS[1], Mohammad Idrees FCPS[2], Dr. Jahanzeb Durrani M.S.[3]

ABSTRACT

Objective: To find out visual acuity recovery after cataract extraction with Intraocular lens implantation in phacomorphic glaucoma.

Materials and Method: This retrospective study was conducted in KDA teaching Hospital Kohat from January 2009 to December, 2013 with the objective to find out visual acuity recovery after cataract extraction with Intraocular lens implantation in phacomorphic glaucoma. In this study total 48 patients suffering from phacomorphic glaucoma with VA of PL positive or better were included. Informed consent was taken from all the patients. Preoperative IOP was checked with Perkins' Tonometer. Patients were examined with slit lamp. IOP was controlled with mannitol, carbonic anhydrase inhibitor and topical beta blocker when there was no contra-indication. Steroids were given topically to control inflammation. Visual acuity was checked. Antiglaucoma drugs and steroids were given for one week. All the patients were booked for the surgery. Biometry was done. After control of IOP and inflammation, extracapsular cataract extraction was done and intraocular lenses were implanted. Visual acuity was checked after 1st post operative day one week one month and best corrected visual acuity after two months when stitches were removed. Total 48 patients comprising of 22(45.83%) male and 26(54.16%) female were included in the study.

Result: At presentation preoperative Visual Acuity of counting finger was present in 9(18.75%) patients, hand movement in 29(60.41%) and perception of light in 10(20.83%) patients. After two months of surgery best corrected Visual Acuity of 6/18 – 6/24 was present in 11(22.91%) patients, 6/36 – 6/60 in 26(54.16%) patients, counting finger in 7(14.58%) patients and hand movement in 4(8.33%) patients.

Conclusion: Cataract extraction after IOP control is the definitive treatment of phacomorphic glaucoma and visual acuity is improved.

Key words: Phacomorphic glaucoma, Visual acuity.

Abbreviation: Intraocular pressure (IOP), Intraocular lens (IOL), Visual Acuity (VA).

INTRODUCTION

Phacomorphic glaucoma is an important ocular disease in developing Asian world with reported incidence of 3.91% of all cataract surgery. Phacomorphic Glaucoma is often associated with population of lower social economical class being affected due to lack of access to medical care.[1] Phacomorphic Glaucoma is caused by a mature and swollen cataract compressing on and compromising aqueous outflow resulting in secondary angle closure glaucoma.[2] The resulting prolonged elevated IOP in turn leads to irreversible optic nerve damage and visual impairment.[3,4]

Recognition of red flags in cataract is important in identifying patients who are at risk of developing complications like glaucoma. Lack of knowledge, regarding the nature and progression of cataract, concomitant chronic disease, old age and financial constraints are the primary reasons for patients delaying in seeking medical help.[5] Phacomoprhic glaucoma is potential cause of visual impairment. Different studies have shown that the prevalence of phacomorphic glaucoma is variable. A 1998 study at Nepal has shown that 72% of cataract patients had phacomorphic glaucoma.[6] The national cataract surgery registry of Malaysia reported that in 2004 out of 18392 cataract surgeries performed,118 patients had phacomorphic glaucoma.[7] The visual acuity recovery in phacomorphic glaucoma depends upon duration and IOP level.

Malik I Q study has shown that patients with early presentation and surgery had better visual acuity recovery as compared to late presentation.[8] In the present scenario many ophthalmologists have worked with latest surgical techniques.[9] But the modality of treatment in such type of glaucoma is lens extraction. Mode of treatment is extracapsular cataract extraction with IOL implantation.[10,11] Whatever technique is used,

[1]Assistant Professor Ophthalmology KMU Institute of Medical Sciences KDA Teaching Hospital Kohat. [2]Medical Officer Eye Ward, PGMI LRH, Peshawar. [3]Ophthlmologist, Maroof International Hospital, Islamabad.

Correspondence: Dr Mohammad Alam Assistant Professor Department Of Ophthalmology, KMU Institute of Medical Sciences K.D.A Kohat. Email: malamktk@gmail.com, Cell: 0301-5956974

Received: May 2015 Accepted: June 2015

the postoperative visual recovery in these conditions remains guarded. In order to evaluate the visual outcome this study has been carried out.

Timely management of patients suffering from phacomorphic glaucoma can give good visual result, if the treatment is not delayed. Such patients should be made aware of the significance of early surgical interference.

MATERIALS AND METHOD

This retrospective study was conducted in DHQ Teaching Hospital KDA Kohat from January 2009 to December 2013 with the objective to find out visual acuity recovery after cataract extraction with IOL implantation in Phacomorphic glaucoma. Informed consent was taken from all the patients. Proper proforma was made for documentation of patients. Patients suffering from phacomorphic glaucoma were ***included*** in the study. Visual acuity was checked. IOP was recorded with Perkin's tonometer. Slit lamp examination was done of all the patients. Mannitol, carbonic anhydrase inhibitor and topical anti-glaucoma drugs were used to control IOP and topical steroids were given to control inflammation. Total 48 patients comprising of 22(45.83%) were male and 26(54.16%) female were included in the study with age range of 60 – 78 years (Table I).

Regarding presentation time 27(56.25%) had presentation time of 0 -3 days, 15(31.25%) patients were in 4 -7 days time and 6(12.5%) presented in 8 – 14 days (Table-II). Preoperative visual acuity was analyzed. 9(18.75%) patients had VA of CF, 29(60.41%) had VA of HM+ and 10(20.83%) patients VA of PL+ (Table-III). PL negative patients were ***excluded*** from the study. After control of IOP and inflammation with in one week, all the patients were operated with conventional extracapsular cataract extraction. IOL were implanted in posterior chamber. All the surgeries were uneventful. The patients were put on topical steroid + antibiotic drop for 4 weeks. No antiglaucoma drugs were advised after surgery. Visual acuity was checked on 1st post operative day, 1st week, 1st month and best corrected VA after two months when stitches were removed.

On 1st postoperative day, 27(56.25%) patients had VA of 6/36 – 6/60, 14(29.16%) patients had VA of CF and 7 (14.58%) patients had VA of HM (Table-IV). On 1st postoperative week 2(4.16%)patients had VA of 6/18-6/24,32(66.66%) had VA of6/36-6/60,9(18.75%)had VA of CF and 5(10.41%)patients had VA of HM.(Table V).

After 1st month, 5(10.41%) patients had VA of 6/18 – 6/24 , 30(62.50%) patients had VA of 6/36 – 6/60, 9(18.75%) had VA of CF and 4(8.33%) patients had VA of HM+. (Table VI) After 2 months, best corrected VA of 6/18 – 6/24 was present in 11(22.91%) patients, 6/36 – 6/60 in 26(54.16%), CF in 7(14.58%) and HM in 4(8.33%) patients (Table-VII).

Table-I Gender distribution:

Gender	No of patients	Percentage
Male	22	45.83
Female	26	54.16

Table-II Duration of presentation of patients

Duration	No of patients	Percentage
0-3 days	27	56.25
4-7days	15	31.25
8-14 days	6	12.5

Table-III VA at presentation

VA	No of patients	Percentage
6/6 – 6/12	0	0
6/18 – 6/24	0	0
6/36 – 6/60	0	0
CF	09	18.75
HM	29	60.41
PL	10	20.83

Table-IV Showing VA after 1st postoperative day

VA	No of patients	Percentage
6/6-6/12	0	0
6/18 – 6/24	0	0
6/36 – 6/60	27	56.25
CF	14	29.16
HM	7	14.58

Table-V Showing VA after one week

VA	No of patients	Percentage
6/6-6/12	0	0
6/18 – 6/24	2	4.16
6/36 – 6/60	32	66.66
CF	9	18.75
HM	5	10.41

Table-VI Showing VA after one month

VA	No of patients	Percentage
6/6-6/12	0	0

6/18 – 6/24	5	10.41
6/36 – 6/60	30	62.50
CF	9	18.75
HM	4	8.33

Table-VII Best corrected VA after 2 months

VA	No of patients	Percentage
6/6-6/12	0	0
6/18 – 6/24	11	22.91
6/36 – 6/60	26	54.16
CF	7	14.58
HM	4	8.33

DISCUSSION

The present carried out study results demonstrate that phacomorphic glaucoma is more common and if the patients seek medical treatment soon after the onset of symptoms, the post operative visual outcome will be better. Late medical intervention will worsen the results. These findings are comparable with results of other national and international studies. The number of female patients are more in our study. Female preponderance was more probably due to shallow anterior chamber. This is identical to studies of Prajan et al and Sunha A.[12,13] In our study best corrected visual acuity after two months was 6/18 – 6/24 in 22.9% patients, 6/36 – 6/60 in 54.16% CF in 14.58% while HM in 8.33%. which is comparable to study of Gupta P et al.[14].Visual outcome in phacomorphic glaucoma is dependent on timely management.[15]

A study has shown that in 54% of eyes with duration less than one week of attack, recovery of VA was 6/12 or better where as 32% of eyes recover this VA if duration of attack lasted up to two weeks and after 3 weeks recovery of vision was light perception or hand movement only.[16] Singh M et al have shown visual acuity recovery in phacomorphic glaucoma of 6/12 or better in 61% patients which is better than our study.[17] Kothari R, Tathe S, et al have shown visual acuity outcome in phacomorphic glaucoma in 42% patients to be 6/60 or worse.[18] Rejal AP, Karki DB have revealed visual acuity of 6/12 – 6/60 in 45% of patients which is nearly comparable to our study.[19] R Ramakishanan, et al have demonstrated visual acuity of 6/12 in most of the patients suffering from phacomorphic glaucoma which is better than our study.[20] AMR Khafagy have reported visual acuity in phacomorphic glaucoma of 6/12 or better in all patients.[21] Variations in results in different studies are mainly due to time and duration of presentation and time of medical and surgical intervention.

CONCLUSION

Based on the results of our study and other national and international studies and references and discussion, it is being concluded that timely management of patients suffering from phacomorphic glaucoma can still give good visual outcome if the treatment is not delayed. People awareness programs should be carried out on print and electronic media regarding this serious disorder.

REFERENCES

1. Angra SK, Pradhan R, Gary Sp. Cataract induced glaucoma – an insight into management. Indian J Ophthalmology 1991;39:97-101. (ChemPort)
2. Leibmann JM, Ritch R. glaucoma associated with lens intumescence and dislocation. In: Ritch R, Shields MB, Krupin T (eds). The Glaucomas, Vol 2, 2nd ed. St Louis: Mosby, 1996; 1033.
3. Hart WM, Becher B. The onset and evolution of glaucomatous visual field defect. Ophthalmology 1982; 89:991-998. PubMed ISI ChemPort
4. David R, Tessler Z, Yassur Y. Long term outcome of primary acute angle closure glaucoma. Br J Ophthalmol 1993; 17: 33-36.
5. Tomy KF, al-Rajhi AA. Neodymium: YAG laser iridotomy in the initial management of phacomorphic glaucoma. Ophthalmology. 1992;99:660-5.
6. Pradhan D, Hennig A, Kumar J, Foster A. A prospective study of 413 cases of lens-induced glaucoma in Nepal. Indian J Ophthalmol. 2001;49:103-7.
7. Goh PP, Shamala R, Rajalakshmi G, Ronald Ad. The 3rd Report of the National Cataract Surgery Registry 2004. National Cataract Surgery Registry,Malaysia 2004.
8. Malik IQ.Rehman MA et al.Visual Outcome after Phacomorphic glaucoma.http://pjmhs online.com/Jan Mar 2013.
9. Dada T, Kumar S, Gadia R, Aggarwal A, Gupta V, Sihota R. sutureless single-port trans conjunctival pars plana limited vitrec-tomy combined with phacoemulsification for management of phacomorphic glaucoma. J Cataract refract Surg 2007;33:951-54.
10. Epstein DL. Lens Induced Open Angle Glaucoma.In;The Secondary glaucoma.Ritch R, Shields MB, St Louis; CV Mosby 1982.pp121-30.
11. Epstein DL diagnosis and management of lens induced glaucoma. Ophthalmol 1982:89:227-30.
12. Sinha A. Combined Trabeculectomy and cataract extraction. Ind J Ophthamol 1983; 31(7):836-38.
13. Rohatgi Jn. Lens induced glaucoma. A Clinical study. Ind J Ophthalmol 1972:20:88-93.
14. Payal Gupta, Sudhir Bhagotra, Suraj Prakash. Pattern and visual outcome in lens induced glaucoma. JK Science Vol.14 No.4,Oct-Dec 2012.
15. Prajna NV, Ramakrishnan R, Krishnadas R, Manoharan N. Lens induced glaucoma.visual results and risk factors for final visual acuity. Indian J Ophthalmol 1996;44:149-55.
16. IS Jain, Amod Gupta, MR Dogra, DN Gangwar, SP Dhir. Phacomorphic glaucoma-management and visual prognosis. 1983;31:648-653.
17. Singh M, ,Arrayyed HA, Krishnan R. Intraocular Lens implantation in Phacomorphic Glaucoma.Bahrain Medical Bulletin,Vol.24,No.3,Sep2002.
18. Kothari R, Tathe S, Gogri P, et al. Lens-Induced Glaucoma: the need to spread awareness about early management of cataract among rural population.ISRN Ophthalmology Volume

2013(2013) Article ID 581727.
19. Rijal AP, Karki DB. Visual outcome and IOP control after cataract surgery in lens induced glaucoma.Kathmandu University Medical Journal(2006),Vol.4No.1,Issue 13,30-33.
20. Ramakrishanan R, Maheshwari D, et al. Visual prognosis, intraocular pressure control and complications in phacomorphic glaucoma following manual small incision cataract surgery. Indian J Ophthalmol 2010 July-Aug;58(4):303-306.
21. Khafagy A. Visual outcomes following manual small incision cataract surgery for phacomorphic glaucoma. Med.J.Cairo Univ.Vol.79, No.2,June: 67-70,2011.

Waheedullah

ORIGINAL ARTICLE

Frequency of Esophageal Varices in Cirrhotic Patients with Ascites having no Upper Gastrointestinal Bleeding

Muhammad Iltaf FCPS[1], Waheedullah FCPS (Gastro)[2], Muhammad Abdullah Jan MBBS[3]
Muhammad Daud MBBS[4]

Gastro Unit, Hayatabad Medical Complex, Peshawar.

ABSTRACT

Objective: To determine the frequency of esophageal varices in cirrhotic patients with ascites with no upper gastrointestinal bleeding. Esophageal varices are a direct consequence of portal hypertension that in cirrhosis results from both increased resistance to portal flow and increased portal venous blood inflow. Screening esophago-gastroduodenoscopy (EGD) for the diagnosis of esophageal and gastric varices is recommended when the diagnosis of cirrhosis is made particularly in those with decompensated status.

Study design: Descriptive case series.

Duration: The duration of study was six months after approval of synopsis.

Settings: Department of Gastroenterology and Hepatology Hayatabad Medical Complex Peshawar.

Material & Methods: This study was conducted at Gastroenterology and Hepatology Department, Hayatabad Medical Complex, Peshawar. Duration of study was 6 months in which a total of 196 patients were observed while keeping 85%1 proportion of esophageal varices among patients with liver cirrhosis with ascites (child pugh class C), 95% confidence interval and 5% margin of error using WHO sample size calculations. More over this was a cross-sectional study in which a consecutive (non-probability) sampling technique was used.

Results: In this study mean age was 52 years with standard deviation ± 1.26. Forty eight percent patients were male 52% patients were female. Esophageal varices were found in 85% patients while 15% patients didn't had esophageal varices.

Conclusion: Gastroesophageal varices and portal hypertensive gastropathy are the most common and well known endoscopic findings in cirrhotic patients with Ascites. Substantial number of cirrhotic patients do bleed from variceal lesions seen in emergency department. For proper medical and/or Endoscopic treatment of varices in these patients these lesions needs to be identified. Upper GI endoscopy (EGD) remains the diagnostic procedure of choice for identification of the varices and helps in variceal management as well. The emphasis should be put on early and thorough endoscopic examinations aimed at proper diagnosis and therapy.

Key Words: Cirrhosis liver. Portal hypertension. Varices. Ascites.

INTRODUCTION

Cirrhosis is the end stage of every chronic liver disease, resulting in formation of fibrous tissue, disorganization of liver architecture, and nodule formation, which interferes with liver function and results in portal hypertension. Portal hypertension is associated with development of a hyperdynamic circulation and complications such as ascites, hepatic encephalopathy, and oesophago-gastric varices. Patients with cirrhosis and gastro-oesophageal varices have a hepatic venous pressure gradient during haemodynamic catheterization of at least 10–12mmHg.[1]

Ascites is the pathologic accumulation of fluid in the peritoneal cavity. Approximately 85% of patients with ascites have cirrhosis, and the remaining 15% have a nonhepatic causes of fluid retention. Portal hypertension plays central role in the development of the ascites because of the increase in the pressure in the portal circulation. Hypoalbuminemia and low oncotic pressure also contribute to the development of ascites. Ascites only occurs when portal hypertension has developed.[2] The development of ascites is associated with a poor prognosis and impaired quality of life in patients with cirrhosis.[3]

Esophageal varices are a direct consequence of portal hypertension that in cirrhosis results from both increased resistance to portal flow and increased portal venous blood inflow. Increased resistance is both structural (distortion of liver vascular architecture by fibrosis and regenerative nodules) and dynamic (increased hepatic vascular tone due to endothelial dysfunction and decreased nitric oxide bioavailability).[4] variceal hemorrhage is a lethal complication of cirrhosis. Variceal hemorrhage is a leading cause of morbidity and mortality in cirrhosis, in patients in whom clinical decompensation (i.e., ascites, encephalopathy, a previous episode of hemorrhage, or

[1]Senior Registrar. [2]Medical Officer. [3]Resident. [4]TMO

Correspondence: Dr. Waheedullah FCPS (Gastro), Medical Officer Gastro Unit, Hayatabad Medical Complex, Peshawar. E-mail: drwaheed2014@gmail. Village and Post Office Samarbagh District Dir Lower. Cell: 0333-9406346 / 0307-5040633

Received: April 2015 Accepted: June 2015

jaundice) has alreadydeveloped.[5] Screening esophago-gastroduodeno-scopy (EGD) for the diagnosis of esophageal and gastric varices is recommended when the diagnosis of cirrhosis is made particularly in those with decompensated status.[1,6] Esophageal varices are present at diagnosis in approximately 50% of cirrhotic patients, being more common in Child-Pugh class C patients compared to Child-Pugh class A patients (85% versus 40% respectively).[1]

In patients with medium or large varices, either nonselective beta-blockers or endoscopic variceal ligation can be used, since a meta-analysis of high-quality, randomized, controlled trials has shown equivalent efficacy and no differences in survival.[7,8] The rate of variceal bleeding is approximately 10 to 30% per year.[9] Acute upper gastrointestinal bleeding is the most common emergency dealt with by Gastroenterologist [10,11] Rates of morbidity and mortality are 10% to 12 % and 8% to 10%, respectively, and they have remained fairly constant during the past 40 years.[11,12]

Operational definitions:

Cirrhosis Liver: Cirrhosis liver is a disease in which there is diffuse destruction of hepatic parenchyma and its replacement with collagenous scar tissue and regenerating nodules with disruption of the normal hepatic lobular and vascular architecture on ultrasound.

Esophageal varices: Expanded blood vessels of any size and number in esophagus detected on upper GI endoscopy.

Ascites: It refers to the accumulation of excessive volumes of fluid within the peritoneal cavity and is detected clinically and confirmed on ultrasound examination.

Gastroesophageal varices and portal hypertensive gastropathy are the most common endoscopic findings in cirrhotic patients with ascites. Substantial number of patients do bleed from variceal lesions which needs to be identified. Upper GI endoscopy(EGD) remains the diagnostic procedure of choice for identification of the varices and helps in management as well. The emphasis should be put on early and thorough endoscopic examinations aimed for proper diagnosis and therapy.

MATERIAL AND METHOD

Settings: Department of Gastroenterology and Hepatology PGMI Hayatabad Medical Complex, Peshawar.

Duration: 6 months (September 2012 to March 2013).

Sample Technique: Consecutive (non-probability)

Sample size: Sample size was 196 keeping 85%[1] proportion of esophageal varices among patients with liver cirrhosis with ascites (child pugh class C), 95% confidence interval and 5% margin of error using WHO sample size calculations.

Study Design: Cross-sectional study.

SAMPLE SELECTION

Inclusion criteria:

- All Cirrhotic patients with ascites above 35 years of age with no upper GI bleeding.
- Either gender

Exclusion criteria:

1. Patients with history of variceal bleeding.
2. Patients in hepatic encephalopathy.
   These may act as confounders and if included will introduce bias in the study results.

Data Collection Procedure After approval from hospital ethical committee, patients with cirrhosis of liver having ascites were seen in OPD or emergency fulfilling the inclusion criteria was enrolled for the study. Appropriate investigations like, Serum albumin, PT/INR, LFTs, Imaging study like ultrasound and upper GI endoscopy were undertaken. Each patient was kept empty stomach for at least 6 hours before endoscopy and written informed consent was taken for Upper GI Endoscopy to detect esophageal varices. Strictly the exclusion criteria was followed to control counfounders and bias in study result. All the endoscopies were done by experienced gastroenterologist and information was recorded in proforma.

Data analysis: All the analysis was done in SPSS version 10. Mean $\pm$ SD was calculated for numerical variables like age. Frequency and percentages were calculated for categorical variables like gender and esophageal varices. Esophageal varices was stratified among age and gender to see the effect modifications. All results were presented as tables and graphs.

RESULTS:

This study was conducted at Gastroenterology Department, Hayatabad Medical Complex, Peshawar. Duration of the study was 6 months in which a total of 196 patients were observed to find the frequency of esophageal varices in cirrhotic patients with ascites and no upper gastrointestinal bleeding; the results were analyzed as:

Age distribution among 196 patients as n= 41(21%) patients were in age range 35-40 years, n= 65(33%) patients were in age group of 41-50 years, n= 90(46%) patients were in age range 51-60 years. Mean age was 52 years with standard deviation ± 1.26. (as shown in Table No 1)

Gender distribution among 196 patients was

analyzed as n= 94(48%) patients were male while n= 102(52%) patients were female. (as shown in Table No 2). Frequency of esophageal varices among 196 patients was analyzed as n= 167(85%) patients had esophageal varices while n=29(15%) patients devoid of esophageal varices. (as shown in Table No 3). Association of esophageal varices in age group was analyzed as among 167 patients with esophageal varices, 23 patients were in age range 35-40 years, 56 patients were in age ranged 41-50 years and 88 patients were in age range 51-60 years. (as shown in Table No 4). Association of esophageal varices in gender distribution was analyzed as among 167 patients with esophageal varices, 78 patients were male while 89 patients were female. (as shown in Table No 5).

TABLE NO 1. Age distribution (N=196)

AGE DISTRIBUTION	FREQUENCY	PERCENTAGE
35-40 years	41	21%
41-50 years	65	33%
51-60 years	90	46%
Total	**196**	**100%**

Mean age was 52 years with standard deviation ± 1.26

TABLE NO 2. Gender Distribution (N=196)

GENDER DISTRIBUTION	FREQUENCY	PERCENTAGE
Male	94	48%
Female	102	52%
Total	**196**	**100%**

TABLE NO 3. Frequency Of Esophageal Varices (N=196)

FREQUENCY OF ESOPHAGEAL VARICES	FREQUENCY	PERCENTAGE
Yes	167	85%
No	29	15%
Total	**196**	**100%**

TABLE NO 4. Association of Esophageal Varices with Age Distribution (N=196)

ESOPHAGEAL VARICES / AGE GROUP	35-40 years	41-50 years	51-60 years	Total
Yes	23	56	88	167
No	18	9	2	29
Total	**41**	**65**	**90**	**196**

Chi Square test was applied in which P value was 0.001

TABLE NO 5. Association of esophageal varices with gender distribution (N=196)

ESOPHAGEAL VARICES / GENDER	Male	Female	Total
Yes	78	89	167
No	16	13	29
Total	**94**	**102**	**196**

Chi Square test was applied in which P value was 0.001

DISCUSSION

Upper gastrointestinal bleeding is one of the life threatening complications in patients with liver cirrhosis. In USA alone it is responsible for over 250000–300000 hospital admissions each year.[13] Upper gastrointestinal bleeding is from a source between the pharynx and the ligament of Treitz, characterised by hemetemesis (vomiting up blood) and melena (tarry stool containing altered blood). Gastrointestinal endoscopy remains the diagnostic and therapeutic procedure of choice for UGI bleeding. The epidemiology of various causes of upper G.I. bleeding has been changing in recent years[14]. Variations in disease pattern from time to time require the need for periodic studies to define the changing etiological distribution for continuous medical education and learning.

Portal hypertension is a progressive complication of cirrhosis. The importance of portal hypertensive syndrome is defined by the frequency and severity of its complications, including upper gastrointestinal bleeding from ruptured gastroesophageal varices. Variceal bleeding is the last step of a chain of events initiated by an increase in portal pressure, followed by the development and progressive dilation of varices until these finally rupture and bleed. Most of the upper GI bleeding episodes in cirrhotic patients are attributed to gastroesophageal varices and portal hypertensive gastropathy which arise by virtue of portal hypertension.[15]

Gastroesophageal varices are the most relevant portosystemic collaterals because their rupture results in variceal hemorrhage, the most common lethal complication of cirrhosis. Varices and variceal hemorrhage are the complications of cirrhosis that result most directly from portal hypertension. Patients without varices develop them at a rate of 8% per year and esophageal varices are seen in 30-80% of cirrhotic patients.[16] In our study esophageal varices were the most common endoscopic finding seen in 77.1% of patients with almost equal distribution among male and female patients.

Gastric varices are less prevalent than esophageal varices and are present in 5%-33% of patients with

portal hypertension and reported incidence of bleeding about 25% in 2 years[17] of our patients were found to have gastric varices (12.3%).

Portal hypertensive gastropathy can be a common source of bleeding in cirrhotic patients. Its prevalence among portal hypertensive patients ranges from 7% to 41%[18]. In the largest study on the natural history of PHG, the overall prevalence of this condition in patients with cirrhosis was 80 %[17,18.] PHG, and was the second most common endoscopic finding after esophageal varices in our study as seen in 50.6% of patients.

Patients with liver cirrhosis do not only bleed from varices, but also bleed from other non-variceal lesions seen in the general population like peptic ulcer disease, gastro-dudenal erosions, AV malformations etc. Identification of these lesions is important for proper management of bleeding in these patients as the therapy of gastroesophageal varices differs from those of non- variceal lesions. Early endoscopy has remarkably improved the rate of accurate diagnosis in gastrointestinal haemorrhage and has replaced other diagnostic measures, including radiography.

Our study shows that the incidence of esophageal varices was 85% in cirrhotic patients with ascites and no upper gastrointestinal bleeding. More over esophageal varices were common in all age groups, both male and female patients but more common in old age patients. Similar results were found in another study done by done by Tsao GG et al[1] in which frequency of esophageal varices was 85% in cirrhotic patients with ascites and no upper gastrointestinal bleeding and the incidence of esophageal varices was common in all age groups, both male and female patients. Nasir N,[19] had quoted similar results as the frequency of esophageal varices was 80% in cirrhotic patients with ascites yet no upper gastrointestinal bleeding and the incidence of esophageal varices was common in all age groups, both male and female patients.

Similar observation were found in another study done by Franchis R[20] in which esophageal varices was found in 87% in cirrhotic patients with ascites with no upper gastrointestinal bleeding and the incidence of esophageal varices was common in all age groups, both male and female patients.

Gastroduodenal ulcers and erosions are particularly frequent in cirrhotic patients, but their precise cause is unclear. However, the postulation that portal hypertensive mucosa is relatively ischemic and is liable to noxious injury may explain the association of such lesions[5]. It may also be explained by the effect of portal hypertension that causes spleenic congestion and alters normal reparative processes of gastroduodenal mucosa.

CONCLUSION

Gastroesophageal varices and portal hypertensive gastropathy are the most common and well known endoscopic findings in cirrhotic patients with ascites. Substantial number of cirrhotic patients do bleed from variceal lesions seen in emergency department. For proper medical and/or endoscopic treatment as varices in these patients, these lesions needs to be identified. Upper GI endoscopy (EGD) remains the diagnostic procedure of choice for identification of the varices and helps in variceal management as well. The emphasis should be put on early and thorough endoscopic examinations aimed at proper diagnosis and therapy.

REFERENCES

1. Garcia-Tsao G, Sanyal AJ, Grace ND. Prevention and management of gastroesophageal varices and variceal hemorrhage in cirrhosis . Am J Gastroenterol 2007;102:2086 – 102 .
2. Ripoll C, Groszmann R, Garcia-Tsao G. Hepatic venous gradient predicts clinical decompensation in patients with compensated cirrhosis. Gastroenterology 2007;133:481–488.
3. Tandon P, Garcia-Tsao G. Bacterial infections, sepsis, and multiorgan failure in cirrhosis. Semin Liver Dis 2008;28:26–42.
4. Iwakiri Y, Groszmann RJ. Vascular endothelial dysfunction in cirrhosis. J Hepatol 2007;46:927-34.
5. Qamar AA, Grace ND, Groszmann RJ, Garcia-Tsao G, Bosch J, Burroughs AK, et al. Platelet count is not a predictor of the presence or development of gastroesophageal varices in cirrhosis. Hepatology. 2008;47:153-9.
6. M. Kovalak, J. Lake, N. Mattek, G. Eisen, D. Lieberman, and A. Zaman, "Endoscopic screening for varices in cirrhotic patients: data from a national endoscopic database," *Gastrointestinal Endoscopy* 2007;65(1):82-88.
7. Gluud LL, Klingenberg S, Nikolova D,Gluud C. Banding ligation versus betablockers as primary prophylaxis in esophageal varices: systematic review of randomized trials. Am J Gastroenterol 2007; 102:2842-8.
8. Gluud LL, Klingenberg S, Nikolova D, Gluud C. Banding ligation versus beta-blockers as primary prophylaxis in esophageal varices: systematic review of randomized trials," *American Journal of Gastroenterology* 2007;102(12):2842-48.
9. Van leerdam ME. Epidemiology of acute upper gastrointestinal bleeding. Best Pract ResClin Gastrointerol 2008:22:209-24.
10. Cappell MS, Friedel D. Initial management of acute upper gastrointestinal bleeding: from initial evaluation to gastrointestinal endoscopy. Med Clin N Am 2008:491-509.
11. Manguso F, Riccio E, Bennato R, Picascia S, Fiorito R, Martino R et al. In-hospital mortality in non-variceal upper gastrointestinal bleeding Forrest I patients. Scandinavian J Gastroentol 2008;43:1432-41.
12. Thomas F, Imperiale, Jason A, Dominitz, Dawn T, Provenzale et al. Predicting poor outcome from acute upper gastrointestinal hemorrhage. Arch Inter Med 2007;167:1291-6.
13. Kamalaporn P, Sobhonslidsuk A, Jatchawla J, Atisook K, Rattanasiri S, Pramoolsinsap C. Factors predisposing to peptic ulcer disease in asymptomatic cirrhotic patients. Aliment Pharmacol Ther 2005;21: 1459–65.
14. Vergara M, Calvet X, Roque M. Helicobacter pylori is a risk factor for peptic ulcer disease in cirrhotic patients. A meta-analysis. Eur J Gastroenterol Hepatol 2002;14:717–22.
15. Kohler B, Maier M, Benz C, Riemann JF. Acute ulcer bleeding. A prospective randomized trial to compare Doppler and

Forrest classifications in endoscopic diagnosis and therapy. Dig Dis Sci 1997;42:1370-4
16. Rockall TA, Logan RFA, Devlin HB, Northfield TC. Variation in out-come after acute upper gastrointestinal haemorrhage. Lancet 1995;346:346-50
17. Toyonaga A, Iwao T. Portal hypertensive gastropathy. J Gastroenterol Hepatol 1998;13:865–77.
18. Primignani M, Carpinelli L, Preatoni P. Natural history of portal hypertensive gastropathy in patients with liver cirrhosis. The new Italian endoscopic club for the study and treatment of esophageal varices (NIEC). J Gastroenterol 2000;119:181-7.
19. Nasir N, Nadeem MA, Imran M, Hussain I, Chaudhry NU. Oesophageal varices Vs peptic ulcer: A Study of 100 Patients Presenting in Mayo Hospital without Upper Gastrointestinal Bleeding. Pak J Gastroenterol 1998; 2:0-.
20. Franchis R. Evaluation and follow-up of patients with cirrhosis and oesophageal varices. J Hepatol 2003;38:361–3

Zaffar Iqbal

ORIGINAL ARTICLE

Pattern of Presentation of Abdominal Tuberculosis in Surgical Department

(Our Experience in Hayatabad Medical Copmplex)

Zaffar Iqbal FCPS[1], Gul Shareef FCPS[2], Mian Tauseef ud Din FCPS[3], Nasir Hassan FCPS[4]

ABSTRACT

Objective: To describe the pattern of abdominal tuberculosis with which patients present in surgical department.

Materiel and Methods: This study was conducted in Surgical Unit of Hayatabad Medical Complex Peshawar from March 2012 to March 2014 . In this descriptive study a total of 40 patients of abdominal tuberculosis were admitted in Surgical Department through emergency and outpatient department on the basis of ***inclusion*** and ***exclusion*** criteria. After detail history and clinical examination , all patients were investigated and were prepared for surgery. A detail proforma has been made which contain all information about the patient. All data analyses were performed using the SPSS program (version 11.5).

Results: Thirty (75%) patients were admitted through casualty as acute emergency, 7(17.5%) through Out-patient Department and 3(7.5%) referred cases. Mean age was 32.3 years. Male to female ratio was 1.1:1. Common presenting features were pain (100%), vomiting (77.5%), Abdominal distension (60%), Abdominal mass (15%) and 15% had ascites. Other common presenting symptoms included anorexia (87.5%), weight loss (67.5%), pyrexia (45%) and pallor (57.5%).

Conclusion: Abdominal tuberculosis is widely prevalent in our society due to poverty and lack of education. It is a disease of young adults affecting male and female almost equally. Its vague and non specific symptoms, lack of diagnostic equipment and delay in early diagnosis and treatment make this curable medical problem, a surgical emergency.

Keywords: Abdominal tuberculosis, peritoneum, abdominal distension.

INTRODUCTION

Tuberculosis is a very old disease caused by Mycobacterium Tuberculous a gram positive bacillus. Tuberculosis has caused heavy losses to mankind for centuries. In this modern space age, despite great advances in the field of medical sciences, this disease is still-hunting human civilization.[1,2]

Mostly third world countries suffered due to T.B where lack of education, poverty and inadequate health facilities have made an already grim situation worse.[3]

The incidence had only slightly diminished in the developing countries while at the same time their population had considerably increased. The tragic factor of Acquired Immunodeficiency Syndrome being pandemic has resulted in an explosion of tuberculosis in a number of countries, adding fuel to fire.[4]

T.B is prevalent in many different forms and abdominal T.B is not rare in Pakistan. The incidence of abdominal T.B have increased many folds due to the influx of Afghan refugees for the last 25 years.[5] While dealing with a patient having chronic abdominal symptoms, abdominal tuberculosis should definitely come at the top of the list of differential diagnosis. Unfortunately many patients of abdominal T.B get complications because of the negligence and difficulty in diagnosing this disease which is still largely diagnosed on the operating table.[3] Patients commonly present with symptoms ranges from anorexia , weight loss ,low grade pyrexia mostly evening time , pallor and pain, vomiting and distension with or without intestinal obstruction, peritonitis and chronic ill health.[6]

While the incidence of Abdominal T.B still seems high in our part of the world. The developed western nations, which until a few years ago, were largely considered to be free of this disease, are again experiencing a revival of this disease due to increasing migrations of people from areas of high prevalence and Acquired Immunodeficiency Syndrome epidemic which is decreasing resistance to the disease.[7,8]

Because of the more efficient steps being taken to control the disease, the incidence of abdominal T.B in western countries is still much less as compared to the third world countries. These include use of pasteurized milk, eradication of infected cattle and better health education measures which are still not widely practiced in our country.[8,9]

Abdominal tuberculosis is widely prevalent in our society due to poverty and lack of awareness. It is a disease of young people affecting

[1]Assistant Professor Surgery, Bacha Khan Medical Complex, Swabi (KPK[2.] Senior registrar, A&E Department, Lady Reading Hospital, Peshawar[3],Senior Registrar Surgery, Bacha Khan Medical Complex, Swabi (KPK). [4]Registrar Surgery, Hayatabad Medical Complex, Peshawar.

Correspondence: Dr Zaffar Iqbal Assistant Professor Surgery, Bacha Khan Medical Complex, Swabi (KPK). Cell: 0300-5974858, Email: drkhan192@hotmail.com

Received: March 2015 Accepted April 2015

male and female almost equally and usually in 3rd decade. Its vague, non- specific symptoms and delay in early diagnosis make this curable medical problem, a surgical emergency.

METHODOLOGY

This study was conducted in Surgical Unit of Hayatabad Medical Complex Peshawar from March 2012 to March 2014 .In this descriptive study a total of 40 patients of abdominal tuberculosis were admitted in surgical department through emergency and outpatient department. This study included all those patients above 12 years of age, who were operated and later confirmed to have abdominal tuberculosis on histologic or bacteriologic examination of the specimens obtained during operation. Less then ten year age group was not included in this group. Patients referred from other units were also included in the study. A proforma containing all the variables according to objectives were constructed.

Those patients who presented in the casualty department as acute emergency were evaluated and preoperative diagnostic work up consisted of history taking, general and systemic examination and investigations .On the basis of symptoms and signs, patients were divided into two groups:

1. ***Obstructed*:** Those patients presenting with main symptoms of pain, vomiting and distension with clinical signs of intestinal obstruction with or without peritonitis.
2. ***Non-obstructed*:** Those patients presenting with chronic ill health, abdominal pain with or without distension but without signs of intestinal obstruction.

Tissue for biopsy was obtained from different sites depending on the site of involvement, like gut, peritoneum, omentum and mesenteric lymph nodes. Part of it was preserved and sent for acid fast bacilli staining and part of it was preserved and sent for histological demonstration of tuberculous granulomas. Patients who were received in the outpatient department as 'cold' cases, underwent more thorough diagnostic work up before surgery and the spectrum of investigations was extended to include procedures like Mantoux's test, sputum examination for acid fast bacilli, ascitic fluid analysis , ultrasound examination and barium studies. A definite diagnosis was established through biopsy in all the patients. All data analyses were performed using the SPSS program (version 11.5).

RESULTS

Out of 40 cases, 21 (52.5%) were males and 19 (47.5%) were females. The male to female ratio was 1.1:1. 30 (75%) cases were received and admitted through the casualty department while 7 (17.5%) cases admitted through OPD, 3 (7.5%) cases were first received and managed by other units and later referred to the surgical team.30 (75%) cases were operated in the emergency operation theatre, while 10 (25%) patients were explored electively in the main operation theatre.

Age group most commonly affected was 21-30 years ,16 (40%) . The 10-20 years age group included 10 (25%) . The minimum age recorded was 12 years and the maximum age recorded was 70 years. Mean age at the time of presentation was 32.3 years. Three (7.5%) patients had past history of affliction with pulmonary TB. 37 (92.5%) were Pakistani nationals, while 3 (7.5%) patients were Afghan refugees. Most of patients belonged to the periphery of Peshawar city while the 3 Afghan refugees were living in a local refugee camps. Six (18%) patients belonged to middle social class while the rest (82%) had a lower social background. 18 (45%) patients were having average living conditions, while the remaining patients (55%) were living in unhygienic and poor conditions. Abdominal Pain was the main symptom presented in all 40 (100%) cases, although its severity and character was variable. In 14 (35%) patients, it was acute in onset while in 19 (47.5%) patients; it was sub-acute with a waxing and waning character. In 7 (17.5%) patients, it was chronic and insidious in nature.

Pain was of colicky character and diffuses in nature in 22 (55%) patients who had acute or sub-acute obstruction, while it was reported to be vague and dull or gripping in character in 18 (45%) patients without obstruction. In 12 (30%) patients, pain was localized to one area of the abdomen. Ten (25%) patients presented with pain in the right iliac fossa. While 1 (2.5%) patient experienced pain in the right upper abdomen.

Vomiting was another common symptom present with variable intensity in 31 (77.5%) patients. It was pronounced in 21 (52.5%) patients with obstruction, while it was also reported in 10 (25%) cases that were not obstructed.

Constipation lasting for more than 48 hours was reported in 12 (30%) patients with obstruction, but in only 1 (2.5%) case without obstruction. Distension of the abdomen with acute or sub-acute onset was experienced by 20 (50%) patients who had intestinal obstruction. In 4 (10%) patients without obstruction, it was of chronic and progressive nature. Loose motions with frequency of more than 3/day were reported in 3 (7.5%) cases in the obstructed group and in 2 (5%) patients in the non-obstructed group. Alternating constipation and diarrhea was a feature in 2 (5%) patients,

both belonging to obstructed group. Chronic cough with duration of more than one month was reported in 7 (17.5%) patients, one patient had an experience of haemoptysis as well. Fever was reported in 18 (45%) patients in both the groups, ranging in duration from 2 days to 6 months. There was accompanying night sweats in 5 (12.5%) patients. Anorexia, weight loss, malaise and pallor was common in majority of the patients, present in 35 (87.5%), 27 (67.5%), 31 (77.5%) and 23 (57.5%) cases respectively.

Out of 40 patients received in the surgical department, 8 (20%) patients were received in a moribund state. 4 (10%) patients were severely dehydrated and 3 (7.5%) patients were in a state of shock. Twenty (50%) patients were clinically anemic. In one (2.5%) patients, there were palpable cervical lymph nodes. A tender abdomen was the leading sign, present in 19 (47.5%) patients with obstruction, while 14 (35%) patients in the non-obstructed group exhibited some degree of tenderness. Abdominal rigidity was present in 10 (25%) patients with obstruction, While 2 (5%) patients showed this sign in the non-obstructed group. Abdominal distension was obviously present in 20 (50%) patients with intestinal obstruction. Four (10%) patients without obstruction also showed some distension of the abdomen. Visible loops were seen in 10 (25%) patients who had obstructed intestine. Three (7.5%) of them also showed visible peristalsis. None of the patient in the non-obstructed group showed either visible loops or peristalsis. A distinct abdominal mass was observed in 6 (15%) patients, out of which 5 were located in the right iliac fossa while in one case a mass was palpable in lower central abdomen. Signs of ascites (fluid thrill and shifting dullness) were present in one (2.5%) case with obstruction while 5 (12.5%) non obstructed patients showed signs of ascites Fig (1).

Table 1. Common presenting symptoms of abdominal tuberculosis

SYMPTOMS	PERCENTAGE OF PATIENTS
Weight loss	67.5
Anorexia	87.5
Nausea or vomiting	77.5
Abdominal distention	05
Fever	45
Constipation	30
Abdominal Pain	100
Night swear	12.5
Chronic cough	17.5

DISCUSSION

Abdominal tuberculosis from the beginning has been a global problem. AIDS, which has become an epidemic in many western and some third world countries, is greatly contributing to the increase in its prevalence. Abdominal tuberculosis is said to be a disease of young adults. Mean age in this study was 32.3 years and most studies indicate that this disease most commonly occurs in the 3rd decade[10], and certainly this was the finding in our study as the most common age group affected was 21-30 years.

Males slightly predominated the females in this study 52.5%. This observation is quite different from other local studies in which a female predominance has been observed i.e., 65.6%.[11] It has been reported from many studies that the disease is more common in males in the western countries while in the developing countries, the women assume a nursing role among infected family members. In our study, most patients belonged to a lower middle class (82%). In fact tuberculosis is widely regarded to be a disease prevalent in regions lacking basic living facilities, proper nutrition and having neglected hygiene.[11,12]

In this study, local patients outnumbered Afghan refugees by 37 to 3. A recent national study has suggested an increase in the incidence of abdominal tuberculosis following the influx of Afghan refugees[13]. Most of the patients presented as acute emergency (77%). This is a similar finding to some local studies in which 83%[14] and 76%[15] of cases presented as emergency. Most investigators have found symptoms and signs of abdominal tuberculosis non-specific, vague and variable[16] which do not appear in a patho-gonomic syndrome. Abdominal pain is the commonest first observed symptom that was the predominant and most common symptom occurring in all patients. Large series have shown this to be the common first observed symptom, occurring in 74%[17] to 96%[6,18] of patients. Nausea and vomiting was another commonly experienced symptom (77.5%) which like pain was pronounced in patients with obstruction. This is similar to another local study in which 73.5% patients experienced it.[19]

Constipation (32.5%) was especially reported in cases with obstruction while a change in bowel habits like diarrhea or alternating diarrhea and constipation (5%) was reported far less frequently. Some studies state this feature to occur rather more frequently.[20] A distinct abdominal mass was observed in 12.5% patients, out of which 80% were located in the right iliac fossa. One patient, who presented to a gynecologist with a mass in the lower abdomen, was clinically diagnosed as a case of ovarian cyst. The presence of mass has been reported with varying frequencies of 25%[11], 13%[21], 19%[22], and 72%.[23]

A doughy abdomen which according to some authors is characteristic of plastic type of tuberculous

peritonitis was not found in any case in this study. Other authors have also found it to occur far less frequently 4.8%[18] and 9%.[21] Abdominal distension was present in 24 (60%) patients in our study but in some other local studies it was seen in 50%[15] and 88.8%.[19]

CONCLUSIONS

We concluded from this study that abdominal tuberculosis is still common in our country. This disease affects younger people usually in 3rd decade. This is a disease affecting poor or lower middle class people. Males and female are affected almost equally and patients are presented usually in acute emergency due to its non specific and vague signs and symptoms.

REFERENCES

1. Russel, Williams, Bulstrode. Bailey & Love's short Practice of surgery. 24th ed. London: Arnold; 2004: 1026-1271.
2. Cuschieri A, Steele RJC, Moossa AR editors.Haemorrhoids. Essential Surgical Practice Vol. II. 4th ed. New York: Arnold; 2005 : 634-5
3. Khan IA, Khattak IU, Asif S, Nasir M, Zia-ur-Rehman. **Abdominal** tuberculosis an experience at Ayub Teaching Hospital Abbottabad.J Ayub Med Coll Abbottabad. 2008 Oct-Dec;20(4):115-8.
4. Waris M, Cheema MA. Different presentations of abdominal tuberculosis at Mayo Sir Ganga Ram Hospital,Lahore. Ann King Edward Med Coll 2000;6: 68-9.
5. Jaffer AJ. Koch's Abdomen in Afghan refugees. J Surg Pak 1997; 2: 23-5.
6. Tariq S, Rauf A, Malik S, Rashid A. Presentations of tuberculosis in northern Pakistan.J Ayub Med Coll Abbottabad. 2011 ;23:40-2.
7. Mandal S, Arinaminpathy N.Int Health. 2015 ;7:114-20.
8. Auld SC, Kim L, Webb EK, Podewils LJ, Uys M. Completeness and concordance of TB and HIV surveillance systems for TB-HIV co-infected patients in South Africa . Int J Tuberc Lung Dis .2013 ; 17:186-91.
9. Vernon A. Treatment of latent tuberculosis infection. Semin Respir Crit Care Med. 2013;34:67-86.
10. Machado N, Grant CS, Scrimgeour E. Abdominal tuberculosis--experience of a University hospital in Oman. Acta Trop. 2001; 80: 187-90.
11. Shahzad R, Osman L, Akram R, Abid KJ, Khan SA, Shah TA, et al. Epidemiology, clinical presentation, site of involvement in abdominal tuberculosis-A retrospective study. Ann Pakistan Inst Med Sci. 1999; 5: 228-9.
12. Channa GA, Khan MA. Abdominal tuberculosis "Surgeons" perspective. J Surg Pak. 2003; 8: 18-22.
13. Jaffer AJ. Koch's Abdomen in Afghan refugees. J Surg Pak .1997; 2: 23-5.
14. Ghazinoor S, Desser T, Jeffrey R B. Increased through-transmission in abdominal tuberculous lymphadenitis. J Ultrasound Med .2004; 23: 837-41.15.
15. Naz F, Chaudhry ZA, Haq A, Ahad A, Ahmad A, Atiq A, et al. Abdominal tuberculosis- A review of 25 cases. Ann King Edward Med Coll. 1999; 5: 180-3.
16. Bernhard JS, Bhatia G, Knauer CM. Gastrointestinal tuberculosis: an eighteen-patient experience and review. J Clin Gastroenterol .2000; 31: 339-40.
17. Lambriandines AL. Abdominal tuberculosis. Br J Surg .1980; 67: 887-9.
18. Das P, Shukla HS. Clinical diagnosis of abdominal tuberculosis. Br J Surg.1976; 63: 941-6.
19. Baloch NA, Babar SA, Mengal MA, Babar KM. Abdominal tuberculosis: A review of 68 cases. Journal of Surgery Pakistan .2002; 7: 12-4.
20. Homan WP, Craft WR. A 43-year experience with tuberculous enteritis. World J Surgery .1979; 1: 245-50.
21. Muneef MA, Memish Z, Mahmoud SA, Sadoon SA, Bannatyne R, Khan Y, et al. Tuberculosis in the belly: a review of forty-six cases involving the gastrointestinal tract and peritoneum. Scand J Gastroenterol .2001; 36: 528-32.
22. Szmigieiski W, Venkatraman B, Ejeckam GC, Jarikre LN.Abdominal tuberculosis in Qatar: a clinico-radiological study. Int J Tuberc Lung Dis. 1998; 2: 563-8.
23. Reichel C. Splenic abscess and abdominal tuberculosis in patients with AIDs. Z Gastroenterol .1996; 494-6.

مانگنے والا گدا ہے صدقہ مانگے یا خراج
کوئی مانے یا نہ مانے، برو سلطان سب گدا

گریز از طرزِ جمہوری، غلام پختہ کارے شُو
کہ از مغزِ دو صد خر فکرِ انسانی نمی آید

اقبالؒ

M. Khalid Khan

ORIGINAL ARTICLE

Effectiveness of Autologous Blood Injection in Planter Fasciitis

Muhammad Khalid Khan FCPS[1], Samir Khan Kabir MBBS, MRCS[2]

Orthopaedics and Trauma Unit, Town Teaching Hospital, Peshawar

ABSTRACT

Background: Planter fasciitis is a painful musculoskeletal condition. Autologous blood injection, one of the conservative treatments, provides the necessary cellular and biological mediators to induce a healing process.

Objective: To determine the effectiveness of autologous blood injection in patients with planter fasciitis.

Material and Methods: This descriptive cross sectional study was carried out at Department of Orthopedics & Trauma, Town Teaching Hospital, Peshawar, from June, 2014 to March , 2015 recruiting 54 patients from OPD. In patients with plantar fasciitis, 2 ml of autologous blood mixed with 2ml of Xylocaine 2% were infiltrated in the planter fascia and effectiveness of autologous blood injection was determined in terms of improvement in at least one grade of pain on Visual Analogue Scale at 12 weeks follow up. Data was analyzed with SPSS version10.0.

Results: At 12 weeks follow up, the overall effectiveness of ABI was in 41 (75.92%) patients. After ABI, 19 (35.18%) patients improved from moderate pain to no pain and mild pain (Grade 0 and 1) while 22 (40.74%) patients with severe pain (grade 3) showed improvement to no pain (grade 0), mild and moderate pain (grade 1 and 2).

Conclusion: Autologous blood injection is very effective to control the pain of planter fasciitis as evident by the decrease in the baseline grades of VAS at 12 weeks follow up.

Key words: Autologous blood Injection; Planter fasciitis; Visual analogue Scale.

INTRODUCTION

Plantar fasciitis is the most common cause of inferior heel pain.[1] Musculoskeletal disorder primarily affecting the fascial enthesis.[2] In the United States affects approximately 2 million people annually and affects as much as 11-15% of the population over the course of a lifetime.[3] The condition affects active and sedentary adults of all ages.[4] But peaks in people between the ages of 40 to 60 years.[5] Male and females are equally affected.[6]

The plantar fascia proximally has attachment to the calcaneum. It has a triangular shape and develops from the medial process of the calcaneal tuberosity, and distally attached at the forefoot onto the plantar skin, the base of proximal phalanges (via plantar plate), the metatarsophalangeal (MTP) joints via the collateral ligaments and deep transverse metatarsal ligaments.[7]
Despite the high prevalence of PF, information about its pathogenesis is still limited. The fascia is usually markedly thickened and gritty. These pathologic changes are more consistent with fasciosis (degenerative process) than fasciitis (inflammatory process). Histologic findings also support the thesis that "plantar fasciitis" is a degenerative fasciosis without inflammation, not a fasciitis.[8]

PF has been associated with obesity, middle age, and biomechanical abnormalities in the foot, such as tight Achilles tendon causing reduced dorsiflexion, pes cavus, pes planus[9,10] and proximal leg muscles pathology.[11] Some authors have related calcaneal spur to PF[12] while other has doubted it.[13]

Severe heel pain upon initial weight bearing in the morning or after prolonged periods of inactivity is pathognomonic for PF.[14] Initially the pain presents diffusely, but over time it localizes to the area of the medial calcaneal tubercle. Pain typically subsides with activity but may return with prolonged weight bearing.[15] The most common examination finding in PF is pain at the medial calcaneal tubercle, which may be exacerbated with passive ankle dorsiflexion or first digit extension.[16] Ultrasound accurately diagnoses plantar fasciitis. Plantar fascia thickness of more than 4.0 mm is diagnostic of PF.[17] Additionally, a decrease in plantar fascia thickness correlates with a decrease in pain levels, and thus ultrasound can aid in monitoring treatment progress.[18]

Many nonsurgical treatment modalities have been used in managing the disorder, including rest, massage, nonsteroidal anti-inflammatory drugs, night

[1]Assisstant Professor, [2]Senior Registrar,

Correspondence: Dr. Muhammad Khalid Khan, Assistant Professor, Orthopaedics and Trauma unit, Town Teaching Hospital, Peshawar, Khyber Pakhtunkhwa, Email: drkkafridi@gmail.com, Cell: 0321-9081319, 0321-9081319, Flat No. 1, New Block, Doctors Flats, Khyber Teaching Hospital, Peshawar.

Received: Aril 2015 Accepted: May 2015

splints[19], heel cups/pads, custom and off-the-shelf orthoses, casts[20], injections[21], exercises[22] and shock wave therapy.[23] Nonsurgical management of plantar fasciitis is successful in approximately 90% of patients.[24]

Different injections like steroid, botulinum toxin and autologous blood has been used for the treatment of PF. Localized injection of autologous blood or platelet-rich plasma has recently gained favor among musculoskeletal specialists as a potential treatment for plantar fasciitis. Autologous blood has proved to be safe, more effective and long lasting. Chronic plantar fasciitis is a degenerative condition and thus is relieved when a mild inflammatory process is created that leads to healing as is provided by autologous blood.[25,27]

The aim of the study was to know the effectiveness of ABI in planter fasciitis. The results of this study will also help other health professionals. This will further help us in reducing the disease burden.

Autologous blood injection is very effective to control the pain of planter fasciitis as evident by the decrease in the baseline grades of VAS at 12 weeks follow up.

MATERIAL AND METHODS

This interventional non randomized control trial was carried out during june, 2014 to March, 2015 at Orthopaedics & Trauma Unit, Town Teaching Hospital, Peshawar, recruiting 54 patients by consecutive (non probability) sampling technique. planter fasciitis was diagnosed clinically as pain at the medial calcaneal tubercle, exacerbated with passive ankle dorsiflexion or first digit extension. All patients of either gender with planter fasciitis of moderate to severe pain between 20 to 70 years of age were ***included*** in the study. The ***exclusion*** criteria adopted was; patients with prior surgery of ankle, dislocation, tendon ruptures, fractures, local skin infection or osteomyelitis, and patients receiving steroid injections within three months. The purpose, benefits and drawbacks of the study were explained to the patient and a written informed consent was obtained. For injection infiltration, the patients were placed in a supine position with the affected foot abducted at 45 degrees. The most tender point of the planter fascia was identified by gentle palpation and infiltrated with 2 ml of autologous blood drawn from contra lateral upper limb cubital vein mixed with 2ml of Xylocaine 2%. The needle was inserted at 90 degrees down to the level of the bone and then pulled back 1 to 2 mm. After injection, the patients were kept for 30 minutes under observation in the OPD for hemodynamic stability and then the patients were discharged.

A detailed history was taken followed by detailed physical and systemic examination. Pain was assessed by visual analogue score (VAS) using a 10cm stripe as shown below;

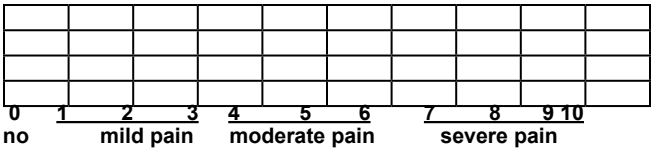

Pain

According to visual analogue scale (VAS), the pain of the planter fasciitis was graded as follows: Grade 0: no pain (VAS 0), Grade 1: mild pain (VAS 1-3), Grade 2: moderate pain (VAS 4-7), Grade 3: severe pain (VAS 8-10). Effectiveness of autologous blood in patients with planter fasciitis was determined by improvement in at one grade of pain on Visual analogue scale at 12 weeks follow up. The demographic variables were gender, age in years, age grouping and duration of symptoms and the research variables were Grade of Pain before injection and Grade of pain after injection. Qualitative variable were analyzed as number (frequency) and percentages (relative frequencies) and quantitative variables were analyzed as mean, SD, minimum and maximum.

Exclusion criteria was followed strictly to control confounding variables and bias in the study results. Data was analyzed by SPSS version10.0. Effectiveness was stratified among age, gender and severity of plantar fasciitis to see the effect modification. The results were presented as tables and graphs. Statistical tests like wilcoxon test/Fisher's test/ Chi-square test were applied where required for significance and the p value > 0.05 was considered significant.

RESULTS

There were 54 patients comprising of 22 (40.74%) males and 32 (59.26%) females with the mean ages of 33.61 years + 7.56SD. Age distribution of patients was; 20 to 30 years were 11 (20.37%), from 31 to 40 years were 26 (48.15%), from 41 to 50 years of age were 10 (18.51%) and from 51 years and above were 7 (12.96%). Age range was from 20 to 59 years.

The distribution of duration of symptoms was; 6 to 12 weeks were 21 (38.33%) and more than 12 weeks were 33 (61.11%). The mean duration of symptoms was 59.61 days + 35.09SD. The range of duration of symptoms was from 45 days to 95 days.

At 12 weeks follow up, the overall effectiveness of ABI was in 41 (75.92%) patients with improvement of at least 1 baseline grade of pain on visual analogue scale. The baseline grade of pain by VAS before autologous blood injection was moderate in 24 (44.44%) patients

and severe in 30 (55.56%) patients. After ABI, 19 (35.18%) patients improved from moderate pain to no pain and mild pain (Grade 0 and 1) at 12 weeks follow up, while 22 (40.74%) patients showed improvement to no pain (grade 0), mild and moderate pain (Grade 1 and 2) from severe pain. The p = 0.753 which is considered to be not statistically significant. Full detail is shown in Table no. 1

The maximum number of patients were 26 (48.15%) from the age group of 31-40 years and the effectiveness of autologous blood injections at 12 weeks follow up was 16 (29.62%) in this age group. Maximum effectiveness was also observed in this age group. According to gender, 15 (27.78%) males and 26 ((48.15%)) females showed effectiveness. Chi square equals 0.034 with 1 degrees of freedom. The two-tailed P value equals 0.8540, which is considered to be not statistically significant. Age and gender wise effectiveness of autologous blood injection is shown in detail in Table no. 2

TABLE No. 1, Effectiveness of autolougus blood injection in terms of improvement of pain on vas at 12 weeks follow up in planter fasciitis

Before ABI	After ABI				Effec-tiveness
	No Pain	Mild Pain	Moder-ate Pain	Severe Pain	
Moder-ate Pain N=24 (44.44%)	9 (16.67%)	10 (18.51%)	5 (9.26%)	0 (%)	19 (35.18%)
Severe Pain N=30 (55.56%)	10 (18.51%)	8 (14.81%)	4 (7.41%)	8 (14.81%)	22 (40.74%)
Total N=54	19 (35.18%)	18 (33.33%)	9 (16.67%)	8 (14.81%)	41 (75.92%)

P = 0.753

TABLE No. 2 Age and gender wise distribution of effectiveness of autologous blood injection in patients with planter fasciitis

Age	No Pain	Mild Pain	Moder-ate Pain	Severe Pain	Effec-tiveness	p value
20-30 years N=11 (20.37%)	4 (7.41%)	5 (9.26%)	2 (3.70%)	0 (0%)	10 (18.51%)	0.858
31-40 years N=26 (48.15%)	10 (18.51%)	5 (9.26%)	3 (5.56%)	8 (14.81%)	16 (29.62%)	
41-50 years N=10 (18.51%)	4 (7.41%)	4 (7.41%)	2 (3.70%)	0 (0%)	9 (16.67%)	
51 and above N=7 (12.96%)	1 (1.85%)	4 (7.41%)	2 (3.70%)	0 (0%)	6 (11.11%)	
Gender						
Male N=22 (40.74%)	6 (11.11%)	7 (12.96%)	4 (7.41%)	5 (9.26%)	15 (27.78%)	0.832
Female N=32 (59.26%)	13 (24.07%)	11 (20.37%)	5 (9.26%)	3 (5.56%)	26 (48.15%)	
Total	19 (35.18%)	18 (33.33%)	9 (16.67%)	8 (14.81%)	41 (75.92%)	

DISCUSSION

Planter fasciitis is one of the common painful conditions, originally described as an inflammatory process, the current consensus is that it is degenerative process than fasciitis. Histologic findings also support the thesis that "plantar fasciitis" is a degenerative fasciosis without inflammation, not a fasciitis8. Conservative treatment includes non-steroidal anti inflammatory drugs (NSAIDS), exercises, local steroid injection, lithotripsy and autologous blood injection, Autologous blood and steroid injections can bring quick relief of pain and improve function.[26]

Addressing our research questions, we found good evidence of effectiveness of AB for planter fasciitis at 12 weeks period follow up. Our study showed that AB diminished the severity of symptoms and effectiveness of autologous blood injection was 75.92%. Several studies have investigated the effectiveness of AB injection in the treatment of planter fasciitis and our findings are consistent with those of other studies. In a local study by Zahid Askar et al,3 female predominance was observed, as in our study, and the effectiveness of autologous blood injection was 92.38% at 6 weeks. Nuefeld SK et al[24], showed that nonsurgical treatment of plantar fasciitis has a success rate of 90%. Lee et al[26], compared autologous blood injections to corticosteroid injections for the treatment of chronic plantar fasciitis. The conclusion of this study was that autologous blood injection is more efficacious in lowering pain and tenderness in plantar fasciitis but corticosteroid is certainly more superior in terms of speed and improvement. However this study was comparative in design and patients were assessed over a period of 6 months whereas in our study assessment was done at 12 weeks interval. The overall effectiveness in both gender groups according to VAS at 12 weeks follow up was 75.92%.

The limitations of this study were lack of regular physiotherapy, NSAIDS and short follow up period. Also many patients reporting to us had already taken

multiple types of medication by themselves. Due to excessive use of so many drugs they were not responding to the treatment of plantar fasciitis. However the results of this study are very encouraging and further studies of longer duration and comparison may be needed to confirm our results.

CONCLUSIONS

From the results of this study it is concluded that autologous blood injection is very effective to control the pain of planter fasciitis as evident by the decrease in the baseline grades of VAS at 12 weeks follow up.

REFERENCES

1. Roxas M. Plantar fasciitis: diagnosis and therapeutic considerations. Altern Med Rev 2005 Jun;10(2):83-93.
2. Wearing SC, Smeathers JE, Urry SR, Hennig EM, Hills AP. The pathomechanics of plantar fasciitis. Sports Med 2006;36(7):585-611.
3. Askar Z, Shoaib M, Iqbal J, Khalid, Khan Kabir S. Effectiveness of autologous blood injections in patients with plantar fasciitis. J Med Sci (Peshawar) October 2012;20(4):155-8.
4. Riddle DL, Schappert SM. Volume of ambulatory care visits and patterns of care for patients diagnosed with plantar fasciitis: a national study of medical doctors. Foot Ankle Int 2004;25:303-10.
5. Peerbooms JC, van Laar W, Faber F, Schuller HM, van der Hoeven H, Gosens T. Use of platelet rich plasma to treat plantar fasciitis: design of a multi centre randomized controlled trial BMC Musculoskeletal Disorders 2010;11:69.
6. Taunton J, Ryan M, Clement D, McKenzie D, Lloyd-Smith D, Zumbo B: A retrospective case control analysis of 2002 running injuries. Br J Sports Med 2002;36:95-101.
7. Tahririan M A, Motififard M, Tahmasebi M N, Siavashi B. Plantar fasciitis. J Res Med Sci 2012 Aug;17(8):799–804.
8. Lemont H, Krista M. Ammirati, Usen. Plantar Fasciitis: a degenerative process (fasciosis) without inflammation. JAPMA 2003 May 1;93(3):234-7.
9. Riddle DL, Pulisic M, Pidcoe P, Johnson RE. Risk factors for plantar fasciitis: a matched case-control study [published correction appears in J Bone Joint Surg Am 2003;85–A:1338
10. LH Gill. Plantar Fasciitis: Diagnosis and conservative management. J Am Acad Orthop SurgMarch 1997;5(2):109-117.
11. Lori A. Bolgla, Malone R T. Planter fasciitis and the windlass mechanism: a biomechanical link to clinical practice. J Athl Train 2004 Jan-Mar;39(1):77–82.
12. Onwuanyi ON. Calcaneal spurs and plantar heel pad pain. Foot 2000;10:182–5.
13. Tountas AA, Fornasier VL. Operative treatment of subcalcaneal pain. Clin Orthop 1996;332:170–8.
14. Tountas AA, Fornasier VL. Operative treatment of subcalcaneal pain. Clin Orthop 1996;332:170–8.
15. Covey CJ, Mulder MD. Plantar fasciitis: how best to treat? J Fam Pract 2013 Sep;62(9):466-71.
16. Thomas JL, Christensen JC, Kravitz SR. The diagnosis and treatment of heal pain: a clinical practice guideline – revision 2010. J Foot Ankle Surg 2010;49(suppl):S1-S19.
17. McMillan AM, Landorf KB, Barrett JT. Diagnostic imaging for chronic plantar heel pain: a systematic review and metaanalysis. J Foot Ankle Res 2009;2:32.
18. Mahowald S, Legge BS, Grady JF. The correlation between plantar fascia thickness and symptoms of plantar fasciitis. J Am Podiatr Med Assoc 2011;101:385-9.
19. Roos E, Engström M, Söderberg B. Foot orthoses for the treatment of plantar fasciitis. Foot Ankle Int 2006 Aug;27(8):606-11.
20. Tisdel CL, Harper MC. Chronic plantar heel pain: treatment with a short leg walking cast. Foot Ankle Int 1996;17:41–2,
21. IM, R. Platelet rich plasma therapy: a comparative effective therapy with promising results in plantar fasciitis. J Clin Orthop Trauma 2013 March;4:31–5.
22. DiGiovanni BF, Nawoczenski DA, Lintal ME, Moore EA, Murray JC, Wilding GE, et al. Tissue-specific plantar fasciastretching exercise enhances outcomes in patients with chronic heel pain: a prospective, randomized study. J Bone Joint Surg Am 2003;85–A:1270–7.
23. Ogden JA, Alvarez R, Levitt R. Shock wave therapy for chronic proximal plantar fasciitis. Clin Orthop Relat Res 2001;387:47-59.
24. Neufeld SK, Cerrato R. Plantar fasciitis: evaluation and treatment. J Am Acad Orthop Surg 2008 Jun;16(6):338-46.
25. R Monto. Platelet rich plasma is more effective than cortisone for chronic plantar fasciitis. Sports Med Arthrosc Rev 2013;21:220–4.
26. Lee TG, Ahmad TS. Intralesional autologous blood injection compared to corticosteroid injection for treatment of chronic plantar fasciitis: a prospective, randomized, controlled trial. Foot Ankle Int 2007 Sep;28(9):984-90.
27. Logan LR, Klamar K, Leon J, Fedoriw W. Autologous blood injection and botulinum toxin for resistant plantar fasciitis accompanied by spasticity. Am J Phys Med Rehabil 2006 Aug;85(8):699-703.

خدا کے پاک بندوں کو، حکومت میں، غلامی میں
ذرہ کوئی اگر محفوظ رکھتی ہے تو استغناء

آہ کس کی جستجو رکھتی ہے آوارہ تجھے
راہ تو، رہبر بھی تو، منزل بھی تو، ساحل بھی تو

اقبالؔ

Zaffar Iqbal

ORIGINAL ARTICLE

Evaluation of Alvarado Score in Detecting Retrocecal Appendicitis

Zaffar Iqbal FCPS[1], Zeeshan Saboor Ahmad MBBS[2], Mian Tauseef ud Din FCPS[3]
Prof. Mazhar Khan FCPS, FRCS[4], Nasir Hassan FCPS[5]

ABSTRACT

Objective: To evaluate Alvarado score in detecting retrocecal appendicitis

Materials & Methods: This was a cross sectional study of 6 months duration, carried out from Jan 2014 to June 2014 in the department of general surgery, Hayatabad Medical Complex, Peshawar. A total of 153 patients were selected and admitted through emergency. Patients were diagnosed using the Alvarado score. Those patients who had a score of more than or equal to 6 were operated. Inclusion and exclusion criteria was set. In this study, the Alvarado score was slightly modified as those patients having superficial tenderness were given 2 marks and those who depicted deep tenderness were given 1 mark. Proforma was made which contain all details of selected patients.

Results: A total of 153 patients had an Alvarado score of ≥ 6 and were operated, out of these 43 patients had a retrocecal appendix and were included in this study. Out of these, 5 patients had an Alvarado score of 8, 11 patients had an Alvarado score of 7 and the remaining 27 had an Alvarado score of 6.Only 2 patients with retrocecal appendicitis presented with migrating right iliac fossa pain. 28 patients had anorexia, 29 patients had nausea or vomiting, 5 patients showed superficial tenderness and the remaining 38 patients had deep tenderness. All the 43 patients showed rebound tenderness, the Bloomberg sign. Just 3 patients had elevated temperature and leucocytosis with shifting to the left was a finding common to 39 patients.

Conclusions: Acute retrocecal appendicitis usually lacks the typical clinical features of acute appendicitis as in Alvarado score. This poses a diagnostic challenge for the surgeon and increasing the risk of development of complications in retrocecal appendicitis.

Key Words: Alvarado score, Retrocecal appendicitis, Rebound tenderness

INTRODUCTION

Vermiform appendix is a blind ended tube connected to the cecum 2 cm below the ileo-cecal junction. It is about 6-9 cm long and has a short mesentery, the mesoappendix.[1,2] It is supplied by the appendicular artery, a branch of the posterior cecal artery, an end-artery which renders the appendix to develop gangrene when the organ is inflamed.[1] The position of the appendix is extremely variable. It can be retrocecal (62%), pelvic (34%), pre-ileal (1%), or post-ileal (0.5%).[1,2]

Acute inflammation of the vermiform appendix is called acute appendicitis. The term appendicitis was first coined and described by Reginald H. Filz, an anatomo-pathologist at Harvard's. It is regarded as one of the commonest surgical emergencies and appendectomy constitutes a large proportion of the abdominal surgeries, accounting to 10% of abdominal surgeries.[3] The diagnosis of acute appendicitis is largely clinical based on history, physical examination and complemented by laboratory findings. Acute appendicitis needs prompt diagnosis and treatment to minimize the associated morbidity and complications.[3] Several scoring systems have been devised to aid decision making in doubtful cases, including the Ohmann, Alvarado, Eskelinen, Raja Isteri Pengiran Anak Saleha Appendicitis (RIPASA) and several others.[3] Among the many, the Alvarado and the modified Alvarado score are the most commonly used.[4] Despite all these scoring systems, the rate of negative appendectomies is as high as 15-30%[5] (Table 1).

Table-1: Alvarado score for acute Appendicitis

Characteristics	Score
Migrating right iliac fossa pain	01
Anorexia	01
Nausea or vomiting	01
Tenderness right iliac fossa pain	02
Rebound tenderness	01
Elevated temperature	01
Leucocytosis	02
Shift to the left	01
TOTAL	10

[1]Assistant Professor Surgery, Bacha Khan Medical Complex, Swabi (KPK), [2]Postgraduate Resident for Surgery, Peshawar, Hayatabad Medical Comples, Peshawar, [3]Senior Registrar Surgery, Bacha Khan Medical Complex, Swabi (KPK), [4]Professor of Surgery, Hayatabad Medical Complex, Peshawar, [5]Registrar Surgery, Hayatabad Medical Complex, Peshawar

Correspondence: Dr. Zaffar Iqbal, Assistant Professor Surgery, Bacha Khan Medical Complex, Swabi (KPK). Cell: 0300-5974858, E-mail: drkhan192@hotmail.com, Khursheed Medical Center, Old Emergency Gate, Lady Reading Hospital, Asamaae Road Peshawar, KPK.

Received: May 2015 Accepted: June 2015

In our set up, the most commonly used scoring system is the Alvarado scoring system. The rationale behind this study was to evaluate Alvarado score in detecting retrocecal appendicitis.

METHODOLOGY

This was a cross sectional study of 6 months duration, carried out from Jan 2014 to June 2014 in the department of general surgery, Hayatabad Medical Complex, Peshawar. Patients were diagnosed using the Alvarado score and only those patients who were >12 years of age and <60 years of age and who had a score of more then or equal to 6 were operated and those patients who had a retrocecal appendix on the operating table were included in the study. The exclusion criteria for this study were patients with American society of anesthesia (ASA) more than 2, those patients who had any chronic disease, mentally retarded and those who were not willing for the surgery; these were excluded from the study population. In this study, the Alvarado score was slightly modified as those patients having superficial tenderness were given 2 marks and those that depicted deep tenderness were given 1 mark.

Acute retrocecal appendicitis usually lacks the typical clinical features of acute appendicitis as determined by Alvarado score. These deviations pose a diagnostic challenge and increases the risk of complications. In such situations, CT diagnostic imaging with i.v. contrast, supplements the clinical findings.

A proforma was designed to include the patient's demographic details including age and sex. Proforma also contain intra-operative findings, clinical features and Alvarado score. All the patients were admitted through emergency. Patients were fully assessed by taking a detailed history followed by complete physical examination. The patients were investigated as indicated employing full blood count, renal and liver function tests, virology screening and cardio-respiratory investigations including chest x-ray and ECG for general anesthesia. After taking informed consent the patients were subjected to appendectomy.

RESULTS

In this study mean age was 22 years and standard deviation was calculated as 14.92. Most of the patients 81% were male while 19% patients were female. A total of 153 patients had an Alvarado score of ≥ 6 and were operated, out of these 43 patients had a retrocecal appendix and were included in this study. Out of these, 5 patients had an Alvarado score of 8. Eleven patients had an Alvarado score of 7 and the remaining 27 had an Alvarado score of 6.

Only 2 patients with retrocecal appendicitis presented with migrating right iliac fossa pain. 28 patients had anorexia, 29 patients had nausea or vomiting, 5 patients showed superficial tenderness and the remaining 38 patients had deep tenderness. All the 43 patients showed rebound tenderness, the Bloomberg sign. Just 3 patients had elevated temperature and leucocytosis with shifting to the left was a finding common to 39 patients as shown in the table below (Table 2).

Table-2: Clinical fetures in acute retrocecal appendiditis using Alvarado score

Alvarado score	No of patients showing
Migrating right iliac fossa pain	05
Anorexia	28
Nausea or vomiting	29
Superficial Tenderness	05
Deep tenderness	38
Rebound tenderness	43
Elevated temperature	03
Leucocytosis	39
Shift to the left	39

DISCUSSION

Acute appendicitis is one of the most common surgical abdominal emergencies.[10] Early diagnosis and treatment could reduce the mortality and morbidity of acute appendicitis significantly.[11] The most common position of the appendix is intra-peritoneal, and the second is in the retrocecal region.[9,12] Some studies report that as many as 50% of retrocecal appendicitis may present with atypical signs and symptoms and this may lead to a diagnostic confusion.[10] Acute retrocecal reported a case with acute retrocecal appendicitis presenting as peri-cholecystic fluid on ultrasound abdomen.[14] This diagnostic difficulty leads to high risk of complications like perforation, mass formation and abscess formation.[4] So patients with atypical appendicitis need to be diagnosed as early as possible to prevent the development of complications. These patients usually have an equivocal Alvarado score and need CT scan of the abdomen as a further investigating modality, showing a sensitivity of 90-100%, a specificity of 90-99.1%, a positive predictive value (PPV) of 90-95.7%, and a negative predictive value (NPV) of 90-100%, respectively.[5,6,7,8] and if serum inflammatory markers evaluation is added as an investigating modality the sensitivity in picking up the disease process further increases.[5]

In our study, the typical migrating right lower quadrant pain was depicted by only 5 patients (11.62%). In a clinical review by D. Mike Hardin, the right lower

quadrant pain was showed by only 50% of patients but the presence of the pain suggested a high likelihood of appendicitis.[15] This review also showed that the retrocecal appendicitis may often present with pain in the right lumbar region rather than the typical right lower quadrant pain.[15] Although the right lower quadrant tenderness to palpation is the most important physical examination finding, other signs may help confirm the diagnosis.[15] Our study showed that only 5 patients (11.62%) with retrocecal appendicitis showed superficial tenderness and 38 patients (88.37%) showed deep tenderness.

CONCLUSION

Acute retrocecal appendicitis usually lacks the typical clinical features of acute appendicitis as determined by Alvarado score. These deviations from the typical clinical features in Alvarado score pose a diagnostic challenge for the examining surgeon and indirectly increasing the risk of development of complications in case of retrocecal appendicitis. In such equivocal situations, CT diagnostic imaging with i.v. contrast supplements the clinical findings.

REFRENCES

1. Russel, Williams, Bulstrode. Bailey & Love's short Practice of surgery. 24th ed. London: Arnold; 2004: 1026-1271.
2. Cuschieri A, Steele RJC, Moossa AR editors.Haemorrhoids. Essential Surgical Practice Vol. II. 4th ed. New York: Arnold; 2005: 634-5.
3. Haider Kamran, Danish Naveed, Shawana Asad, Muhammad Hameed, Umar Khan. Evaluation of modified alvarado score for frequency of negative appendicectomies.Ayub Med Coll Abbottabad. 2010;22:46-9.
4. Karul, Murat, et al. "Computed tomography in adults with atypical clinical presentation of acute appendicitis: comparison of findings with inflammatory serum markers." Gastroenterological and Intestinal Systems.2013.
5. Ong EM[1], Venkatesh SK.Ascending retrocecal appendicitis presenting with right upper abdominal pain: Utility of computed tomography.World J Gastroenterol. 2009 ;15:3576-9.
6. Eugene Mun Wai Ong , Sudhakar Kundapur Venkatesh Petroianu A. Diagnosis of acute appendicitis. *Int J Surg*. 2012; 10:115-9.
7. Pooler BD, Lawrence EM and Pickhardt PJ. MDCT for suspected appendicitis in the elderly: diagnostic performance and patient outcome. Emerg Radiol. 2012; 19:27-33.
8. Tamburrini S, Brunetti A, Brown M, Sirlin C and Casola G. Acute appendicitis: diagnostic value of nonenhanced CT with selective use of contrast in routine clinical settings.Eur Radiol. 2007; 17:2055-61.
9. Ong EM, Venkatesh SK. Ascending retrocecal appendicitis presenting with right upper abdominal pain: utility of computed tomography. World J Gastroenterol 2009;15:3576-9.
10. Buluş H, Coşkun A. Subhepatik appendisit. Kolon Rektum Hast Derg .2010;20:29-32.
11. van Randen A, Laméris W, van Es HW, ten Hove W, Bouma WH, van Leeuwen MS, et al. Profiles of US and CT imaging features with a high probability of appendicitis. Eur Radiol 2010;20:1657-66.
12. Peletti AB, Baldisserotto M. Optimizing US examination to detect the normal and abnormal appendix in children. Pediatr Radiol 2006;36:1171-6.
13. Kim S, Lim HK, Lee JY, Lee J, Kim MJ, Lee AS. Ascending retrocecal appendicitis: clinical and computed tomographic findings. J Comput Assist Tomogr 2006;30:772-6.
14. Perikolesistik sıvı Oktay ALGIN, Evrim ÖZMEN, Ayşenur Şirin ÖZCAN, Şehnaz ERKEKEL, Mustafa Karaoğlanoğlu. Unusual manifestation of acute retrocecal appendicitis: pericholecystic fluid Akut retroçekal apandisitin sıra dışı bulgusu. Turkish Journal of Trauma & Emergency Surgery Case Report Ulus Travma Acil Cerrahi Derg 2013;19 :80-82
15. D. Mike hardin, JR., M.D.Acute Appendicitis: Review and Update Texas A&M University Health Science Center, Temple, Texas Am Fam Physician. 1999;60:2027-34.

Touseef-ud-Din

ORIGINAL ARTICLE

Pattern of Presentation of Peripheral Vascular Injuries

Mian Touseef-ud-Din FCPS[1], Arshad Amin FCPS[2], Zaffar IqbalFCPS[3]
Ishaq Ahmed FCPS[4], Gul Shareef FCPS[5]

ABSTRACT:

Objective: To find out common presentations of peripheral vascular injuries.

Materials & Methods: This analytic study was conducted at the department of general surgery in collaboration with Cardiovascular Unit of Lady Reading Hospital Peshawar from 1st January, 2010 to 30 September, 2012.A total of 25 cases were included in the study and on the basis of clinical assessment they were explored and findings of vascular injury confirmed per operatively. The relevant data included was age, sex, altered pulsation, expanding hematoma, arterial bleeding, bruit and neurological deficit. This data was recorded in a predesigned proforma and subjected to SPSS program version10.

Results: In total 25 patients, 20 [80%] patients were males and 5 [20%] were females. Mean age was 30.2 years. Altered distal pulses were recorded in 20 [80%] patients, expanding hematoma in 10 [40%], external bleeding in 8 [32%], bruit in 7 [28%] and neurological deficit in 6 [24%] patients. 6 patients presented within 6hours, 2 patients within 12 hours, 3 patients within 24 hours while 14 patients presented after 24 hours

Conclusion: Altered distal pulsation, arterial bleeding, bruit, expanding hematoma and neurological deficit are common presentations of peripheral vascular injury. Once these finding are found in a trauma patient then he should undergo surgical exploration rather than wasting time in time-consuming investigation like angiography.

Keywords: Peripheral vascular injuries, altered pulsation, expanding hematoma.

INTRODUCTION

Vascular injuries accounts for 2-3% of civilian trauma[1,2,3] and around 7% of combat related trauma.[4] Peripheral vascular injuries are common in our region of KPK as well as throughout the world. In peripheral vascular injury, the mechanism is an important prognostic factor. Shotgun, military rifle, limbs involved in bomb blast, road traffic accidents injuries as well as knee dislocations are particularly high risk for vascular injury.[5]

The time interval between injury and evaluation must be considered. "Warm" ischemia at body temperature for more than 6 hours results in irreversible nerve and muscle damage in 10% of patients.[6] Cooling the extremity may avoid this complication. Extremities vascular injuries can result in limb loss, serious life-long functional disability or even death in characteristically young victims. These vascular injuries may result from penetrating or blunt trauma to the extremities. If not recognized and treated rapidly, injuries to major arteries, veins, and nerves may have disastrous consequences resulting in the loss of life and limb. It is particularly tragic when such an unfavorable outcome can be traced back to delayed or failed recognition, incorrect or incomplete assessment of extent or severity of vascular injuries. A thorough knowledge of understanding of all clinical manifestation indicating the presence of vascular injury is mandatory for rapid and accurate diagnosis as the investigations which help in the diagnosis of these injuries are time-consuming and are also easily not available. By the time these investigations are done the patients have undergone irreversible changes in their traumatized extremities resulting in limb loss.[7,8] The objective of this study is to identify those findings which will help in the early diagnosis of peripheral vascular injury. This will prevent the morbidity and mortality associated with delayed or missed diagnosis of peripheral vascular disease.

[1]Senior Registrar, Department of Surgery, Bacha Khan Medical Complex Shahmansoor, Swabi, KPK, [2]Medical Officer, Surgery, Bacha Khan Medical Complex Swabi, [3]Assistant Professor Surgery, Bacha Khan Medical Complex Swabi, [4]Senior Registrar Orthopedic, Bacha Khan Medical Complex Swabi, [5]Senior registrar A & E Department, Lady Reading Hospital, Peshawar.

Correspondence: Dr. Mian Touseef-ud-Din FCPS, Senior Registrar, Department of surgery, Bacha Khan Medical Complex Shahmansoor Swabi, KPK. Cell: 0300-9175595, Email: miantauseefuddin@yahoo.com House No. 54, Street No. 1, Sector K, Sheikh Maltoon Town, Mardan KPK.

Received: March 2015 Accepted May 2015

In peripheral vascular injury, altered distal pulsation, arterial bleeding, bruit, expanding hematoma and neurological deficit are common presentations. Once these finding are found in a trauma patient, he should undergo surgical exploration rather than wasting time in time-consuming investigations like angiography etc.

METHODOLOGY

This analytic study was conducted at the Department of General Surgery in collaboration with Cardiovascular Unit of Lady Reading Hospital Peshawar from 1st January, 2008 to 30 December, 2014. All cases of vascular trauma were admitted through Causality Department. Each case was first assessed by causality medical officer and then referred to the surgical team on duty. Simple routine investigations were done. If clinical findings suggested vascular trauma then they were referred to surgical consultant for re-assessment. Majority of these cases were assessed clinically and on the basis of clinical assessment. They were then explored and findings of vascular injury confirmed per operatively. A total of 25 cases were included in this study for both upper and lower extremities vascular trauma. The relevant data included was age, sex, type and nature of injury, time interval when he was injured and brought to hospital if any associated fractures or neurological deficit. Each patient was thoroughly examined especially for altered pulsation, expanding hematoma, arterial bleeding, bruit, cyanosis, paraesthesia, proximity of injury to nearby vessels, neurological deficit and viability of limb. This data was recorded in a predesigned proforma and subjected to SPSS program version10.

RESULTS

In this study minimum age was 16 years and maximum was 68 years with a mean age of 30.2 years. Regarding gender distribution 20 [80%] patients were males and 5 [20%] were females. The most common type of injury were penetrating without any gunshot wounds observed in 8 [32%] patients followed by gunshot wounds observed in 6 patients. Other causes are shown in table no.1. Fourteen patients had sustained injuries to upper extremity, while 11 patients had lower extremity involvement as shown in table 2.

Altered distal pulses were recorded in 20 [80%] patients, expanding hematoma in 10 [40%] patients, external bleeding in 8 [32%] patients, bruit in 7 [28%] patients and neurological deficit in 6 [24%] patients (table 3).Time lag between wounding and restoration of blood circulation were more than 24 hours. In our study only 6 patients presented within 6 hours, 2 patients within 12 hours, 3 patients within 24 hours while 14 patients presented after 24 hours. Only in 4 patients vascular repair were undertaken within 6 hours. In majority of these case 56%[14 patients] the blood flow to the limb were restored after 24 hours. On exploration in 8 patients arteries were completely transected in 5 the injured arteries were only lacerated. 4 patients presented with arterio-venous fistula and 2 with false aneurysms of arteries. 7 patients [28%] had combined vascular and orthopedic injuries, they were explored with orthopedic surgeon and vascular repair were done after fixation of bones.

DISCUSSION

The mean age in our study is comparable with a local study done by Manan and Shoab[9] and also by Ayaz and his colleagues[10] and a global study by Bongard et al[11] plus another study conducted in Srilanka WDD de Silva et al[8] with same results. This young age patients are affected due to the facts that they are more aggressive, physically more active and are more involved in outdoor activities of socioeconomic affairs and travelling. Thus they are more prone to be involved in conflicts and confrontations resulting in accidents. Regarding distribution the male preponderance in our study is consistent with a local of Ayaz et al,[10] a global study by Pozo et al[12] and Aitken et al[13] WDD de Silva et al. [8]

In our study 80% patients were having altered distal pulses. This finding is in conformity with the observation of Robbs and Baker,[14] Sturm et al[15] according to which the most common acute sign of vascular trauma is a pulse deficit. In five patients we missed the diagnosis when they first presented in causality department, later they presented with gangrene of the limb requiring amputation. This is due to the fact that large collateral beds permit distal perfusion and transmission of pulse wave may proceed relatively uninhibited in an artery in which only a partial obstruction exists. Furthermore, the accurate palpation of pulses requires skill that is acquired only by frequent practice and is rarely achieved.[16]

In our study other presentations were arterial bleeding, bruit, expanding hematoma and neurological deficits. These findings were also noted by Blacklay et al[17] and Feliciano et al[18] according to which these findings occur with variable frequencies. In this study most of the patients presented after six hours following injury. Only four patients presented within six hours following injury and only in eight patients circulation was restored within first 12 hours of their admission. Moreover prolonged ischemia time was definitely one of the contributing factors in high amputation rate [32%] observed in our series.

Limitation: This is a single centre study having limited number of samples so further multiple centers studies are needed to evaluate these parameters.

CONCLUSION

Altered distal pulsation, arterial bleeding, bruit, expanding hematoma and neurological deficit are common presentations of peripheral vascular injury. Once these finding are found in a trauma patient then he

should undergo surgical exploration rather than wasting time in time-consuming investigation [angiography etc].

Recommendations: If a trauma patient present with altered distal pulsation, arterial bleeding, bruit and expanding hematoma then he should undergo surgical exploration rather than wasting time in time-consuming investigations e.g. angiography etc.

Vascular injury patient should be transferred to a teaching hospital as soon as possible to reduce the rate of avoidable amputation in these patients.

There should be more centers where vascular surgeries should be done as our province of KPK is deprived of it except Lady Reading Hospital, Peshawar.

REFERENCES

1. Austin OM, Redmond HP, Burke PE, et al. Vascular trauma-A review. J Am Coll Surg .1995; 181:91-108.
2. Compton C, Rhee R: Peripheral vascular trauma. Perspect Vasc Surg Endovascr Ther. 2005; 17:297-307.
3. Sugrue M, Caldwell EM, D'Amours SK, Crozier JA, Deane SA: Vascular injury in Australia.Surg Clin North Am. 2002; 82:211-219.
4. Fox CJ, Gillespie DL, O' Donnell SD, Rasmussen TE, Goff JM, Johnson CA, Galgon RE, Rich NM: Contemporary management of wartime vascular trauma. J Vas Surg. 2005; 41:638-644.
5. Mousa A, Chong B, Aburahma AF. Endovascular repair of subclavian/axillary artery injury with a covered stent. A case report and review of literature. Vascular. 2013.
6. Hafez HM, Woolgar J, Robbs JV. Lower extremity arterial injury: results of 550 cases and review of risk factors associated with limb loss. J Vasc Surg. 2001; 33:1212-9.
7. Wani, Sharief Ahmed, et al. "Pattern, Management, Results And Complications Of Vascular Injuries Of The Extremities. Report From A Hospital In Jammu." Internet Journal of Orthopedic Surgery 17.2 ,2010.
8. WDD de Silva*, RA Ubayasiri†, CW Weerasinghe† and SM Wijeyaratne.Challenges in the management of extremity vascular injuries: A wartime experience from a tertiary centre in Sri Lanka.World Journal of Emergency Surgery 2011, 6:24 .
9. Mannan P, shoab SS. Vascular Surgery at the Post Graduate Medical Institute Lady Reading Hospital, Peshawar. J PGMI 1990;4:19-33
10. Ayaz M Gondal K, Chaudhry ZU. The Mayo Hospital experience of vascular emergencies. J Surg PIMS 1993; 6 & 7:17-9.
11. Bongard FS, White GH, Klein SR. Management Strategy of complex extremity injuries. AM J Surg 1989;158:151-5.
12. Pozo JL, Pawell B, Andrews BG, Hutton PAN, Clarke J. The timing of amputation for lower limb trauma. J Bone Joint Surg (Br) 1990;72-B:288-92.
13. Aitken RJ, Matley PJ, Immelman EJ. Lower limb vein trauma: a long-term clinical and physiological assessment. Br. J.Surg. 1989;76:585-8.
14. Robbs JV, Baker LW. Cardiovascular trauma. Curr Probl Surg 1984;XXI:20-87.
15. Sturm JT, Bodily KC, Rothenberger DA, Perry JF. Arterial injuries of the extremities following blunt trauma. J Trauma 1980;20:933-6.
16. Rutherford RB. Diagnostic Evaluation of extremity vascular injuries. Surg Clin North Am 1988;68:683-91.
17. Blacklay PF, Duggan E, Wood RFM. Vascular Trauma: Review. Br J Surg 1987;74:1077-83.
18. Feliciano DV, Mattox KL, Graham JM, Bittando CG. Five year experience with PTFE grafts in vascular wounds. J Trauma 1985;25:71-82.

دِل توڑ گئی اُن کا، دو صدیوں کی غلامی
دارُو کوئی سوچ، اُن کی پریشاں نظری کا

وضع میں تم ہو نصاریٰ، تو تمدن میں ہنُود
یہ مسلمان ہیں، جنہیں دیکھ کے شرمائیں یہُود

اقبالؔ

Riaz Qadeer

ORIGINAL ARTICLE

Incidence of Firearm Injuries & Mortality in Peshawar (KPK)

Riaz Qadeer MBBS, DMJ[1], Rubina Salma Yasmin M.Phil[2], Rizwan ul Haq M.Phil[3]
Anwar ul Haq MPH, DMJ[4]

ABSTRACT

Background: Medico-legal autopsy is a valuable source of information to know whether death is natural or unnatural.

Study Design: This descriptive study is based on autopsy record which provides information regarding deaths occurring due to firearm injuries.

Duration of study: From 1st January 2013 to 23rd May 2013.

Methodology: This study was conducted in the department of Forensic Medicine & Toxicology Khyber Medical College, Peshawar. Data was collected from the record of autopsies performed from January 2013 to May 2013 and included all deaths due to firearm injuries from urban and rural areas of Peshawar.

Results: Out of total 400 autopsies 285 deaths were due to firearm injuries (71% of autopsies).More in males (262) than in females (23) and more in rural areas (207) than in urban areas (78).

Conclusion: Deaths due to firearm injuries in Peshawar are alarming and should be seriously looked at by the policy makers. By limiting firearm possession can save so many precious lives.

Key words: Firearm, Autopsy, un-natural death.

INTRODUCTION

Strong association has been reported between firearm possession and unnatural deaths in Peshawar. The methods of killing have changed over the time as weapons like knives and daggers are becoming outdated and are being replaced by firearm as the most common weapon. The head and chest are the most common sites of fatal injuries. Day to day tension, drug addiction, terrorism, lust, rage, jealously and revenge are the common factors leading to unnatural deaths by use of weapon like klashankov, pistol and revolvers. This study was conducted to know the deaths caused by use of lethal weapon like firearm. Examination of victims of firearm injuries need to ascertain the characteristics of entry wound such as muzzle imprint , burning (flame effect), smudging (the smoke effect), tattooing and the collar of abrasion (only in riffled weapon).The exit wound will not show these characteristics except the averted margins of different sizes.

[1]Associate Professor, Head of the Department, Forensic Medicine & Toxicology, Peshawar Medical College Peshawar, [2,3]Assistant Professor, Department of Forensic Medicine & Toxicology, Peshawar Medical College Peshawar, [4]Assistant Professor, Khyber Girls Medical College, Peshawar.

Correspondence: Major (R) Dr. Riaz Qadeer, Associate Professor & Head of the Department of Forensic Medicine & Toxicology, Peshawar Medical College, Warsak Road, Peshawar. Email: riaz563@yahoo.com, Cell: 0334-4087077

Received: May 2015 Accepted: June 2015

MATERIAL AND METHOD

The present descriptive study was conducted at the department of Forensic Medicine & Toxicology Khyber Medical College, Peshawar from first January 2013 to 23 May 2013. The study was conducted on the total available autopsy record of reported medico-legal deaths during the time period mentioned above and it consist of all cases referred by both urban as well as rural police stations. Deaths due to firearm injuries were selected from the total autopsies performed and victims were grouped on the bases of locality (urban/rural), gender, age, regions of body affected by firearm injuries. External examination of the whole body was conducted. The injuries were examined with naked eye as well as by using magnifying glass. The injuries were numbered, the size, shape and exact site of the firearm injury related to fixed anatomical land mark was established. Internal examination was done and the extent of internal injuries to various organs were determined. The data was entered in a proforma and results were summarized as under.

The high death rate due to firearm injuries in Peshawar especially amongst the youngsters is very alarming and must be an eye opener for the policy makers. They need more attention and training for adjustment in the society cool-mindedly. Moreover, culmination of easy access to lethal weapons needs religious injunctions as well as legislative control over the fire arms, to maintain peace and harmony in the society.

RESULTS

A total of 400 unnatural deaths were reported and subjected to autopsy examination. Out of these 285

deaths were caused by firearm injuries.

Body region	No. of firearm injuries	Percentage
Head	109	38.5%
Neck	09	3%
Thorax	121	42.5%
Abdomen	38	13.25%
Upper limb	03	1%
Lower limb	05	1.75%
TOTAL	**285**	

Distribution of Fire Arm Injuries on various body regions

Age	No. of firearm injuries	Percentage
Age up to 9 years	01	
Age 10 to 19 years	25	8.77%
Age 20 to 29 years	80	28%
Age 30 to 39 years	70	24.50%
Age 40 to 49 years	51	18%
Age 50 to 59 years	38	13.33%
Age 60 to 69 years	11	4%
Age 70 years & above	09	3.50%
TOTAL	**285**	

Various age groups affected by fire arm injuries

Area	No. of Firearm Injuries	Percentage
Rural	207	72.66%
Urban	78	27.34%
Total	**285**	

Gender	No. of Firearm Injuries	Percentage
Male	262	92%
Female	23	8%
Total	**285**	

DISCUSSION

Interpersonal conflicts have numerous adverse effects on the society which may range from minor to major effects like economical, social, psychological etc. Firearm injuries are the leading cause of death accounting for about 71% of the total 400 autopsies performed. Persons of all age groups were affected by firearm injuries with the majority being in age group 20 to 29 years (28%) and in age group 30 to 39 years (25%). The male to female ratio is 11 to 1 . Female appear to be spared due to their house hold duties, loyalty to husband and other family members. More over ladies hold an honored place in disputes and enmities. The number of firearm victims reported from rural areas was more as compared to urban areas. This may be due to better education and employment, better planning and better living conditions in the urban setup as compared to rural areas where disputes due to land are pending for years and year's. Upper regions of the body e.g. thorax and head neck regions were found more affected by firearm injuries (84%) as they are more vital areas. Firearm injuries on upper limb alone were non fatal but were seen on the dead bodies along with involvement of other vital regions of body. These results are comparable with the previous studies done in Peshawar on this topic. More involvement of males is understood as males are earning hands of the family, having more outdoor duties and being the head of the family are supposed to solve problems among the relatives. Males of age group 20 to 40 are more vulnerable to unnatural death due to firearm injuries is obvious from this as well as from the previous studies. Nature has made male more muscular and vigorous. Difficult living conditions in rural areas, lengthy and costly court procedures favors the young vigorous males to make decisions by using physical power, hence a vicious cycle of enmities starts resulting in loss of precious lives in an area where firearm weapons are within reach and are part of dress.

CONCLUSION

The high death rate due to firearm injuries in Peshawar especially among the young is very alarming and must be an eye opener for the policy makers. Young males of the population need more attention and training for adjustment in the society by not loosing temper on petty maters. Easy access to lethal weapons like firearm needs more strict control for maintaining the peace in the society. ***Quran says "that killing of one human being is like the killing of whole human humanity".***

REFERENCES

1. Temporal variation in United States firearm injuries 1993-2008: results from a national data base, Randall T. Loder J Inj Violence Res. 2014 January; 6(1): 1–15. doi: 10.5249/jivr.v6i1.351
2. Mixed Impact of Firearms Restrictions on Fatal Firearm Injuries in Males: A National Observational Study, Finn Gjertsen, Antoon Leenaars, Margarete E. Vollrath Int J Environ Res Public Health. 2014 January; 11(1): 487–506. Published online 2013 December 30.
3. Firearm Injuries A Study of 150 Cases, Pakistan Journal of Medical and Health Sciences 04/2012; 6(2):438-440. Arif Rasheed Malik King Edward Medical University, Muhammad Amjad Bhatti, Muhammad Alamgir Rana, Arif Rasheed Malik, Attiya Mubarak Khalid
4. Pattern of Firearm Injury and Outcome Aijaz A. Memon, Afsar Ali Bhutto, Ghulam Shabir Shaikh, Amanullah Jokhio and Quratul-ain Soomro JLUMHS MAY - AUGUST 2009; Vol: 08 No. 02
5. Analysis of homicidal deaths in district DI Khan: an autopsy study. J Ayub Med Coll Abbottabad. 2009 Jan-Mar;21(1):155-7 Humayun M1, Khan D, Fasee-uz-Zaman, Khan J, Khan O, Parveen Z, Humayun W.
6. Morbidity & mortality of firearm injury in Peshawar region J

Ayub Med Coll Abottabad Apr - Jun 2008;20(2):102-4. Shah MM1, Ali U, Fasseh-uz-Zaman, Khan D, Seema N, Jan A, Ahmad M, Arif M.

7. Brown-Sequard syndrome following firearm injury with a bullet lodged in the upper cervical canal J Coll Physicians Surg Pak May - May 2008;18(5):312-3. Nawabshah Medical College, Nawabshah, Brohi SR1, Brohi AR, Brohi QR.
8. Outcome of delayed minimally invasive plate osteosynthesis in firearm injuries of femoral shaft Ann King Edward Med Uni Jul - Sep 2007;13(3):212-4. Muhammad Hanif, S Azhar, M K Syed, I A Bhutta .
9. Analysis of homicidal deaths in Peshawar, Pakistan. J Ayub Medical College Abbotabad 2006; 18 (4): 30-3, Marri MZ1, Bashir MZ, Munawar AZ, Khalil ZH, Khalil Iu.
10. Homicidal deaths by firearms in Peshawar: an autopsy study. J Ayub Med Coll Abbottabad. 2006 Jan-Mar;18(1):44-7, Hussain Z1, Shah MM, Afridi HK, Arif M.

Saeed Zafar

ORIGINAL ARTICLE

Biometric Assessment of Cataract Cases by using Immersion Technique in Phacoemulcification with foldable IOL

M. Saeed Zafar Khan FCPS[1], Naeem Rustam FCPS[2], Ahmed Zeeshan Jamil FCPS[3]
Prof. Zahid Kamal Siddiqui FRCS, FCPS[4]

ABSTRACT

Objective: The purpose of this study was to determine the accuracy and safety of A scan immersion biometry by using prager shell in cases of cataract surgery by phacoemulcification with foldable intra ocular lens.

Materials and Methods: This retrospective study of 100 cases conducted at eye unit of university of Punjab and Iqra Medical Complex Lahore from March 2008 to December 2010. After history and complete ocular examination the clinical diagnosis of cataract was established. The biometric assessment was carried out by using immersion technique. All cases under went phacoemulicifaction with foldable IOL. The A scan instrument Axis 11 PR with Prager Shell (Quintal medical –France) was used.

Results: One hundred patients were included in this study. There were 45 male and 55 female patient. The right eye was studied in 47 % of cases while left eye in 53 % of patients .The mean age of the patient was 64+-11 years (TABLE 1).The post operative mean spherical equivalent was recorded ± 0.75 D in 65% of patients and between -0.75 to -1.50 D in 23 % of cases ,only 12 % of cases had +0.75 to +1.50 D of the intended results (table 2). The average keratometry readings of all the cases was recorded 44.78 (range was 41.25 to 47.25 diopter). The mean preoperative axial length was 22.86 ± 1.12 mm (range was 21.76 to 23.89 mm). The mean intraocular lens power was 21.25 ± 2.75 D with a range +18.50 to + 24.75 D (Table 4).

Conclusion: In conclusion, the immersion A scan biometry is a very useful diagnostic technique as it eliminates corneal compression by using prager shell. The same biometric equipment allowed the cataract surgeon with high predictability and reproducibility.

Key Words: Biometry, immersion technique, phacoemulcification.

INTRODUCTION

Cataract Surgery has been revolutionized being merely a visual rehabilitation procedure to a refractive surgery. The intra ocular lenses implantation introduced by Sir Nicholas Harold Ridley in 1949[1], has emerged as a supremely successful procedure in the 21 st century. Innovation and development of various techniques of phacoemulcification since Dr. Charles Kelman to date[2], has allowed the reduction of incision size from approximately 10mm to merely 1mm. New intra ocular lens designs, improved manufacturing techniques and quality controls has contributed great success in cataract surgery, while the results of cataract surgery implantation has improved today, improvement in intra ocular lens power calculation are needed.[3]

The ultrasound A-scan works by projecting a sound wave through the eye and then measuring reflections. A reflection happens at the junction of two different densities, such as the interface between the posterior lens capsule and the vitreous. These echoes are shown as tall spikes of high amplitude on the display hence the name A-SCAN. There are five primary amplitude peaks on an ocular A-scan, the cornea, anterior lens, the posterior lens, the retina and the sclera for the axial length measurement, the ultrasound will measure the distance from the cornea to the retina at the centre of the macula. The number appeared on A scan is then used for intra ocular lens calculation, along the patient keratometry readings.[4,5]

The exact measurement of axial length is important for measuring the IOL power, the global accuracy of the A scan is dependent upon firstly on the good alignment with the visual axis and secondly on the low pressure on cornea. By using the SRK 2 formula, a ± 0.2mm inaccuracy in measurement results in an IOL difference of 0.5 diopter. For the hypermetropic eye, the error will be more. The most common error seen in applanation type of scan is corneal compression and not proper centering of the cornea which result in short axial length with resulting postoperative ametropia.

[1]Consultant Eye Surgeon, Iqra Medical Complex, Lahore. [2]Assistant professor Fatima Memorial Hospital, Lahore. [3]Assistant professor, Rashid Lateef Medical College, Lahore. [4]HOD Department of Ophthalmology, FJMC / Sir Ganga Ram Hospital, Lahore

Correspondence: Dr. M. Saeed Zafar Khan, Consultant Eye Surgeon, Iqra Medical Complex, Lahore Email: ophth05@yahoo.com

Received: April 2015 Accepted: June 2015

The immersion A scan biometry is a very useful diagnostic technique as it eliminates corneal compression by using prager shell. The same biometric equipment allowed the

cataract surgeon with high predictability and reproducibility

MATERIAL & METHODS

This retrospective study was conducted in eye unit of university of Punjab and Iqra Medical Complex from March 2008 to December 2010. A total of 100 cases meeting the selection criteria were included in the study.

Inclusion Criteria: Patients of both sex, reporting at out patient department with blurring in vision diagnosed as age related cataract on slit lamp biomicroscopy, between ages of 50 to 75 years.

Exclusion Criteria: Patients with corneal scar and cataract secondary to trauma, keratoconus or had penetrating keratoplasty, cases of chronic uveitis, secondary cataract, glaucoma patients requiring surgery, patients with any retinal pathology, uncontrolled diabetics, hypertensive were excluded from the study.

All biometric assessment was done by one surgeon one to two days prior to surgery by using A scan Instrument AXIS 11PR with PRAGER Shell (Quintal medical-France), SRK 2 formula was used to calculate the IOL power in all cases. The accuracy of postoperative results was determined by calculating the disparity between actual refraction at four weeks postoperative with expected refraction.

Technique: One hundred patients meeting the inclusion criteria were selected for this study. Diagnosis was made on history, visual assessment and slit lamp biomicroscopy. In immersion technique, A scan eliminated corneal compression and instead of directly touching the cornea and risking abrasion and compression such as with applantation, it allowed measurements through the use of sclera shell. In our study we used pager sclera shell of appropriate size. The patient is reclined the eye is anesthetized with the topical proparacaine hydrochloride 0.5% eye drops and prager shell is gently applied. The ultrasound probe is fixed in the shell which is then filled with normal saline; it was used to couple the sound waves of the probe to the eye with no risk of corneal compression. Patient head is placed parallel to the ground and were asked to fixate their eyes on a ceiling mounted target, an automated sequence of 10 readings appeared on the screen. The measurement accuracy standard deviation was set at equal to +-0.04mm. All the data was collected in a systemic way and was analyzed with SPSS version 12. The variables were age, sex, laterality of eye, preoperative keratometry readings and axial length.

RESULTS

One hundred patients were included in this study.

There were 45 male and 55 female patient. The right eye was studied in 47 % of cases while left eye in 53 % of patients .The mean age of the patient was 64 ± 11 years (TABLE 1). The post operative mean spherical equivalent was recorded ± 0.75 D in 65% of patients and between -0.75 to -1.50 D in 23% of cases, only 12% of cases had +0.75 to +1.50 D of the intended / required results (table 2). Out of one hundred patients, thirty patients were in the age group 56-60 years and among these 93% achieved post operative visual acuity level from 6/6 -6/12. Similarly thirty two patients were in age group of 61-65 years and among these 87.5% attained visual acuity level from 6/6 6/12. Other age groups also attained good level of visual acuity (table 3). The average keratometry readings of all the cases was recorded 44.78 (range was 41.25 to 47.25 diopter). The mean preoperative axial length was 22.86 ± 1.12 mm (range was 21.76 to 23.89 mm). The mean intraocular lens power was 21.25 ± 2.75 D with a range +18.50 to +24.75 D (Table 4).

TABLE 1: Demographic Data

Sex	Male	45
	Female	55
AGE	mean± sd 64±11 years	
LATERALITY	Right eye	47
	Left eye	53

TABLE 2: Disparity in diopters from post operative refraction

DIOPTERS	% OF TOTAL CASES
± 0.75D	65%
_ 0.75D to _1.50D	23%
+ 0.75 to + 1.50D	12%

TABLE 3

AGE GROUP	LEVEL OF VISUAL ACUITY				
	6/6-6/9	6/12-6/9	6/18-6/12	6/24-6/18	TOTAL
50-55 YEARS	13	6	1	1	21
56-60 YEARS	20	8	2	0	30
61-65 YEARS	18	10	3	1	32
66-70 YEARS	5	2	1	3	11
71-75 YEARS	3	1	1	1	6

TABLE 4: Biometric Average Readings

Average Keratometry	44.78 D
Average axial length	22.86mm
Average IOL power	+21.25D

DISCUSSION

The success of cataract surgery in terms of post operative refractive results depends on the calculation of exact intra ocular lens power. The accuracy of preoperative measurements like keratometry and axial length are of significant importance due to the patient demand of preferred refractive outcome with quick visual rehabilitation. For the axial length measurement, the ultrasound will measure the distance from the cornea to the sensory retina. This number is then used for the calculation of intra ocular lens power measurements. The most common error in contact A scan is compression which gives false shorter axial length and higher intra ocular lens power and post operative myopic surprise. Secondly, due to the direct contact of probe to the cornea there is increased risk of bacterial contamination and corneal erosion. However the immersion technique will eliminates the corneal compression and risk of infection by using the sterile normal saline as a coupling agent for the non contact biometry

In our study the mean age of the patient was 64± 11 years as compared with Ibbas and Mehmood[6] the man age of the patient was 60.35 ± 7.92 years. There was female majority/preponderance compared to male in the present study however with a study of Navon and Edge, the male gender was in majority.[7] The mean axial length by immersion technique was 22.86 ± 1.27 as compared to Mehmood et al was 22.92 ± 1.2 and Kronbaur et al[8] was recorded 23.19 ± 1.32 which were comparable with the present study. The post operative mean spherical equivalent was within ± 0.75 D in 65% of cases which was comparable with 75% reported by Moin et al in their study by using partial coherence laser interferometery.[9]

Schelenz J, Kamamam J compared the contact and immersion techniques for axial length measurement and implant power calculation by reporting that the contact technique yielded shorter measuring values then the immersion technique and shorter measurement produced strong intra ocular lens power.[10] Trivedi RH, Wilson ME also reported shorter axial length with contact biometry then immersion technique. This difference was mainly due to the anterior chamber depth rather then the lens thickness values. There was stronger intra ocular lens power then is actually required and myopic shift was seen in post operative results.[11] Narva-i-ez et al had used immersion technique and partial coherence interferometry for axial length measurement and reported that in those eyes measured by both techniques there was no difference in measurement nor post operative refractive outcome.[12] Hrebcoca J et al in their study of contact and immersion technique of ultrasound biometry found the mean spherical equivalent in the group measured by contact technique was -0, 13 D compared to -0.25 D in immersion technique.[13] Schelenz J. and Trivedi ,both in their studies concluded that in peadriatric cataract cases contact A scan measurement resulted shorter axial length than immersion technique and reported that it lead to the use of an average 1D stronger IOL power than is actually required and it lead to induced myopia in post operative refraction.

CONCLUSION

Immersion A scan ultrasound technique eliminates corneal compression risking abrasion such as with the applanation tonometry, and it allowed the use of prager shell. The same biometric equipment allowed the predictability and reproducibility with no extra effort.

REFRENCES

1. Ridley H. Artificial intraocular lenses after cataract extraction. St Thomas hospital reports 1951; 7:12-14.
2. Kelman CD. Phacoemulcification and aspiration.A new technique of cataract removal; a preliminary report. Am J Ophthalmology1967 ;64:23.
3. Yanoff & Duker Ophthalmology,3rd ed; chapter 5.3, 2008. mosby, Elservier.
4. HolladayJT, Prager TC. Improving the predictability of intraocular lens power calculations. Arch Ophthalmol 1986.104:539-41.
5. Oslen T. The accuracy of ultrasonic determination of axial length in pseudophakic eyes.Acta Ophthalmol(copenh)1990;67:141-4.
6. Mehmood Tahir et al. Immersion Vs contact biometry for axial length measurement before phacoemulicifaction with foldable iol.Pak j ophthalmology 2009.vol 25 no 4,195-199.
7. Edge r, Navan S . Axial length and posterior staphloma saudai Arabian cataract patients. J cataract refract surg 199 ;25:91-5.
8. Kronbaur A L, Kronbaur EL ,Kronbaur CL. Comparative study of the biometric measurements made by immersion and contact techniques.Arq Bras Oftalmol 2006 ; 69 875 -80.
9. Moin M et al. Intraocular lens power calculation using the zeiss iol master(partial coherence laser interferometry). Pak j ophthalmol 2005, vol.21;3: 88-90.
10. Schelenz j, Kammann j. comparison of contact and immersion techniques for axial length measurement and implant power calculation. J cataract refract surg 1989 jul;15(4):424-8.
11. Trivedi RH, Wilson ME.Axial length measurements by contact and immersion techniques in pediatric eyes with cataract.Opht halmology.2011March;118(3):498-502.
12. Narv A iez J. Comparing immersion ultrasound with partial coherence interferometery for intraocular lens power calculation. ophthalmic surg lasers imaging-01-jan-2008;39(1):30-4.
13. Hrebcova j et al. comparasion of contct and immersion techniques of ultrasound biometry I n terms of target post operative refraction .cesk slov oftalmol-01-july-2009;65(4):143-6.

Riaz Qadeer

ORIGINAL ARTICLE

Mortality Due to Road Traffic Accidents in Peshawar

Riaz Qadeer DMJ[1], Rubina Salma Yasmin M.Phil[2], Rizwan ul Haq M.Phil[3]

Deptt. of Forensic Medicine & Toxicology, Peshawar Medical College, Peshawar

ABSTRACT:
Objective: To find out the frequency of deaths due to road traffic accidents in Peshawar.
Study design: Autopsy based descriptive study.
Place: This study was conducted in the department of Forensic Medicine & Toxicology of Khyber Medical College, Peshawar.
Duration of study: Autopsies conducted from 1st January 2013 to 23rd May 2013. (Total 400 cases).
Methodology: Data collected from the autopsy record of total autopsies done in the department of Forensic Medicine & Toxicology, Khyber Medical College, Peshawar from January 2013 to May 2013. It included all cases of unnatural deaths referred for autopsy from the rural as well as urban areas of police stations of Peshawar district.
Results: Out of total 400 autopsy cases 39 deaths (10%) were due to road traffic accidents. Most victims were of age 20 to 29 years (40%), male to female ratio was 4 to 1 and urban to rural areas ratio was 1 to 2.
Conclusion: Traffic accidents are the main cause of about 10% of deaths as autopsied. In fact the incidence could be higher. Precious lives can be saved through strict enforcement of law. Moreover, it is important to create awareness of honesty and importance of duty in drivers through religious injunctions and by legislative cover.
Key words: Mortality, road traffic accidents, autopsy, Peshawar, Pakistan.

INTRODUCTION

Accident is any happening which occur all of a sudden without any expectation or planning. Road traffic accidents occur all of a sudden unintentionally causing physical injuries like bruises, lacerations or fractures necessitating immediate medical treatment in a hospital. Road traffic accidents occur due various causes including (1) faults in the vehicle ie. In the brakes or in the engine of the vehicle, (2) faults in the environment eg. fog or (3) faults in the roads ie. slippery roads or (4) problems with the driver. The mental and physical health of driver is very important. epilepsy, diabetes mellitus, ischemic heart disease, painful joint or habit of smoking may badly affect his performance. Modern life has made people short tempered. People are in hurry and sometimes they do not bother about the social rights of others. Driver may be exhausted but he has to do his duty due to one reason or the other. Addiction among drivers is another cause of road traffic accidents leading to loss of precious lives. There may be head on collision, rear impact or side impact producing injuries among the passengers sitting inside the vehicle. A pedestrian may be hit by a moving vehicle and this may be primary or secondary impact or it may produce run over injuries.

[1]Associate Professor, Head of the Department, Forensic Medicine & Toxicology, Peshawar Medical College Peshawar. [2,3]Assistant Professor, Department of Forensic Medicine & Toxicology, Peshawar Medical College

Correspondence: Dr. Riaz Qadeer Associate Professor, Head of the Department, Forensic Medicine & Toxicology, Peshawar Medical College, Peshawar. Cell: 0334-4087077, Email: riaz563@yahoo.com

Received: April 2015 Accepted: June 2015

Traffic accidents are the main cause of about 10% of deaths as autopsied. In fact the incidence could be higher. It is a preventable cause of death which needs immediate attention of the policy makers. Precious lives can be saved by strict control in the issue of driving licenses, improving roads, developing under passes and over head bridges, proper checking of vehicles, controlling addiction amongst drivers, enforcing civic sense by improving literacy in them. Moreover, it is important to create awareness of honesty and importance of duty in drivers through religious injunctions and by legislation.

MATERIAL AND METHOD

This study was conducted in the department of Forensic Medicine & Toxicology, Khyber Medical College Peshawar which is the only centre for autopsy in the Peshawar district. Autopsy was performed on all 400 death cases referred by the police from the rural as well as urban police stations from 1st January 2013 to 23rd May 2013. The cause of death in 39 out of 400 was road traffic accidents . Autopsy report was issued while record of each case was maintained in the department. From the record information like age, sex,

main injures on the body , referred from rural or urban police station, died on the spot or was admitted in a hospital were entered in a performa and results were analyzed as under.

RESULTS

Most of the victims of road side accidents were male (82%) and were from rural areas (67) . Most were in the age group 20 to 29 years (40%) and only 40% of the victims were able to get any medical treatment in a hospital before death.

SEX	No.	Percentage
Male	32	82
Female	7	18
Total	**39**	

Gender Locality

AREA	No.	Percentage
Rural	26	67
Urban	13	33
Total	**39**	

Hospitalization	No.	Percentage
Admitted in the hospital	16	41
Not admitted in the hospital	23	59
Total	**39**	

HOSPITALIZATION

Body region involved	No.	Percentage
Head and Neck	29	74.5
Chest and Abdomen	9	23.0
Lower Limb	1	2.5
Upper Limb	nil	
Total	**39**	

VARIOUS AGE GROUPS

AGE	No	Percentage
1 to 9 years	4	9.5
10 to 19 years	4	9.5
20 to 29 years	15	39.0
30 to 39 years	3	8.0
40 to 49 years	7	18.0
50 to 59 years	3	8.0
60 to 69 years	3	8.0
70 years & above	nil	nil
Total	**39**	

DISCUSSION

In Pakistan police is the in charge of the dead body on behalf of state hence no consent of any one is required for autopsy. As authority is given to police to investigate all unnatural, sudden, suspicious deaths so if concerned SHO is satisfied that death is natural then no further investigations are required but if the concerned SHO needs the help of medical knowledge to find out the cause of death then he will request for autopsy. From the autopsy record 10% deaths were due to road traffic accidents. All other cases of death due to road traffic accidents settled by the police were not included in this study. People like to avoid autopsy as well as lengthy court procedures so actual deaths caused by road traffic accidents seems to be more than the deaths reported by the police for autopsy. Most of the victims (60%) were young of age 20 to 40 years & were male (62%) .This is because mostly young males are riding on a motorcycle. They are having more outdoor duties as they may be the only earning hands for the rest of the family members. More were from rural areas (67%), got injuries on head, neck and chest of their body (75%) so (60%) expired on the spot without getting any medical help in a hospital because vital areas of the body were involved. These results are not only comparable with the previous studies done on this subject in Peshawar but also are showing more deaths due to road traffic accidents. This is due to increase in population and urbanization. In the developing countries like Pakistan the infra structure is not developed. The life is becoming more comfortable due to more vehicles but it has added more tension in life resulting in more use of anxiolytic drugs which are habit forming with addiction. Complexities of modern life have made people self centered to their problems and they are least complacent for others. This may be the reason of 60% deaths without any medical help. No case of injury to upper limb alone was reported as it is non fatal. Only one case of fractures of bones of both the lower limbs was unable to survive hence referred for autopsy.

CONCLUSION

Roadside accidents are the cause of about 10% of deaths autopsied even suspected to be higher. This is a preventable cause of death and seeks attention of the policy makers. Precious lives can be saved by strict control in the issue of driving license, by improving roads, developing under passes and over head bridges, proper checking of vehicles, controlling addiction among drivers, improving education of the people and by making police more honest and dutiful .Religious training of the young generation that they should not

be impatient, openly accept the social rights of others, should be more considerate and sympathetic in order to avoid innocent deaths.

REFERENCES

1. Azam, Khizar, et al. "COMPARISON OF FATIGUE RELATED ROAD TRAFFIC CRASHES ON THE NATIONAL HIGHWAYS AND MOTORWAYS IN PAKISTAN." (2014)
2. Donato, Vincenzo, Samuele Camolese, and Alessandra Terenzi. "Traffic Analysis and Solutions." *Sustainable Social, Economic and Environmental Revitalization in Multan City*. Springer International Publishing, 2014. 199-210.
3. Syed Shahan Ali Shah, Mohammad Ayaz, Rawid Khan, Khan Shahzada, Hassan Khan, Zaigham Ali, "Traffic Analysis of Warsak Road Peshawar Pakistan", ISSN 2320-3439, Vol. 02, No. 03, May 2013, pp. 58-64.
4. Tahir, M. N., et al. "Road traffic crashes in Ramadan: an observational study."*EMHJ* 19 (2013): 3.
5. Aziz, K., and I. U. R. Khalil. "Road traffic accidents in Peshawar." *Ann King Edward Med Coll Lahore* 8.2 (2002): 103-4.
6. Rehman, Basheer, et al. "Characteristics of Maxillofacial fractures resulting from Road Traffic Accidents-an analysis of 250 patients." *JPDA* 19.3 (2010): 159.
7. Shaikh, M. A., A. Shaikh, and Z. Siddiqui. "Road rage and road traffic accidents among commercial vehicle drivers in Lahore, Pakistan." (2012).
8. Khan, Abdul Manan, and Ansa Tehreem. "Causes of road accidents in Pakistan." *Journal of Asian Development Studies* 1 (2012).
9. Gulzar, Shazia, et al. "Provincial Analysis of traffic accidents in Pakistan."*Traffic* 3.3 (2012).
10. Ameratunga, Shanthi, Martha Hijar, and Robyn Norton. "Road-traffic injuries: confronting disparities to address a global-health problem." *The Lancet*367.9521 (2006): 1533-1540.
11. Razzak, Junaid Abdul, and Lucie Laflamme. "Limitations of secondary data sets for road traffic injury epidemiology: a study from Karachi, Pakistan."*Prehospital Emergency Care* 9.3 (2005): 355-360.
12. Sarwar Shah, Syed Ghulam, Khalil Khoumbati, and Badaruddin Soomro. "The pattern of deaths in road traffic crashes in Sindh, Pakistan." *International journal of injury control and safety promotion* 14.4 (2007): 231-239.


Tariq Mahmood

ORIGINAL ARTICLE

Glycosaminoglycans (GAG) as a Marker of Progression of Diabetic Retinopathy in Patients with Type 2 Diabetes Mellitus

Tariq Mahmood Arain FCPS[1], Mohammad Fayyaz FCPS[2], Saleha Zafar FCPS[3]

Quaid-e-Azam Medical College, Bahawalpur

ABSTRACT

Purpose: We studied the association of diabetic retinopathy with Glycosaminoglycans (GAG's) concentration in tears of patients of Type 2 diabetes mellitus (DM).

Methods: Our study comprised 482 Type 2 diabetic out patients who were free of diagnosed hyperlipidemia at baseline. Retinal findings were classified based on fundoscopy (by a single ophthalmologist) to categories of no diabetic retinopathy, non-proliferative diabetic retinopathy and proliferative diabetic retinopathy. Outcomes measures were concentration of GAG's in tears of patients with good glycemic control and poor glycemic control.

Results: During 6 months of study duration, 482 participants with type 2 DM were undergone for fundus examination, after adjustment for age, body mass index, lipids profile, glycated haemoglobin and diabetes duration. Patients with poor glycemic control had a greater risk of retinopathic changes than those with good glycemic control. The mean concentration of GAGs in patients with NPDR is lower than those presenting PDR, but the difference is not statistically significant (p=0.489)

Conclusion: Diabetic retinopathy (especially in its more advanced stages) is associated with an increased concentration of GAG's in tears of patients with poorly controlled DM in patients of type 2 DM.

INTRODUCTION

Diabetic retinopathy is increasingly becoming a major cause of blindness throughout the world in the age group of 20-60 years.[1] Loss of productivity and quality of life for the patient with diabetic retinopathy will lead to additional socio-economic burdens on the community.[2] In type I diabetes, diabetic retinopathy is uncommon before the age of 13 years. The onset of puberty may influence retinopathy – although the duration of diabetes is a significant factor. In those with type II diabetes there is an increased frequency of retinopathy in those younger than 50 years.[3] Diabetes mellitus affects the metabolism of several components of extra-cellular matrix, including glycosaminoglycans (GAG). Alterations in the metabolism of GAG may play an important role in the development of diabetic complications.[4]

In most developing countries there are few ophthalmologists for every diabetic to be examined annually by an ophthalmologist.[5] If retinal photography is not possible, then the fundus may be examined by the diabetic physician, an optometrist, or an ophthalmic assistant. The current study has been conducted to see the relationship between diabetic retinopathy and GAG's concentration in tears of the patient with type 2 diabetes mellitus with poor glycemic control that could be helpful to prevent ophthalmic complications of diabetes mellitus.

[1]Associate Professor of Ophthalamology. [2]Associate Professor of Medicine. [3]Consultant Pathologist

Correspondence: Dr. Saleha Zafar, Consultant Pathologist, Q.A.M.C Bahawalpur. Email: salehazafar61@yahoo.com, Cell: 0333-6388685

Received: April 2015 Accepted. May 2015

Diabetic retinopathy (especially in its more advanced stages) is associated with an increased concentration of GAG's in tears of patients with poorly controlled DM in patients of type 2 DM.

MATERIAL AND METHODS

Study settings: Study has been conducted at QAMC, Ophthalamogy department in collaboration with department of Pathology and Medical Unit 4.

***Study duration*:** Study was commenced from 01-05-2014 to 31-10-2014.

***Inclusion criteria*:** All the patients with type 2 DM, who never developed ketoacidosis, were of normal weight and at least initially were controlled on oral hypoglycaemic agents, labelled as type 2 diabetics and included in study.

Exclusion criteria: Patients with known history of hypertension, type 1 DM, patients who were under weight or who had been suffered from ketoacidosis or required insulin for control of diabetes, labelled as type 1 DM and were excluded from the study.

Sample size: The relationship between diabetic retinopathy and GAG's concentration in tears has been estimated in 482 diabetic patients (type 2 diabetes mellitus (DM).

METHODOLOGY

The diagnosed cases of type 2 DM, were referred from Medical Unit 4 to ophthalmology OPD for fundoscopic examination for the assessment of retinopathy, where fundoscopy of patients was performed by an experienced consultant ophthalmologist. All the patients with diabetic retinopathy were isolated and their tear film was taken by consultant pathologist after taking consent. Tear samples were collected from both eyes of each subject included by placing for a period of 1 minute in the lower fornix of the eye 2 circular pieces of 3 mm chromatography paper of a diameter of 7 mm. Approximately 250 µl of tears were collected from each subject. Immediately after, the specimen collection papers were placed in sterilized plastic bags and stored. For the elution of tear specimens, these were placed in 5 ml polypropylene tubes. The GAGs were eluted by adding 1 ml of distilled water and gently rocked the sample for 20 minutes. The elute was used for GAG assay and protein estimation. GAGs were extracted from the tear samples by precipitation using CPC 1% in 0.3% NaCl. Precipitates were repeatedly treated with NaCl 2 M and absolute ethanol. For the GAGs assay, the uronic carbazole reaction was used as described by Bitter and Muir 1962. GAGs concentration was expressed as uronic acid value µg/ml mg of protein.

***Data analysis*:** Statistical analysis was performed by using SPSS 10.00. The two-tailed independent samples were used to analyze the statistical significance of differences between GAGs levels in tear samples of diabetic patients with good glycemic control and poor glycemic control. $p < 0.05$ was considered to indicate significance. Means concentration of gag's were obtained in tears of patients with retinopathy having poor or good glycemic control. Test of significance T-test was applied.

RESULTS

No	Age group	Gender distribution	
		Male	Female
1	40- 45	57	05
2	46- 50	126	58
3	51-55	112	36
4	56-60	61	27

Socioeconomic Status		Glycemic Control	
		Good	Poor
Income>10000/month	147	102	45
Income<10000/month	335	63	272

No.	Number of patients	Retinopathy	HbA_1C	GAG's concentration
1	165	present	<7.0	285µg/ml
2	317	present	>7.0	352µg/ml

To further analyze the increase of GAGs in tears of diabetic patients presenting signs of DR, we compared the amount of GAGs in tears between patients with good glycemic control and poor glycemic control. The mean GAGs concentration in patients with good glycemic control is equal to (285.17 ± 15.2 µg/ml [mean ± SEM]). The mean GAGs concentration in patients with poor glycemic control is equal to (352.72 ± 27.6 µg/ml [mean ± SEM]). Statistical analysis of the results reveals that GAGs concentration in tears of patients with poor glycemic control was significantly greater than the patients with good glycemic control ($p = 0.012$).

Moreover, we compared the NPDR group with the PDR in order to see if a correlation between the GAGs concentration in tears and the evolution of DR towards the NPDR or the PDR type is observed. The mean concentration of GAGs in patients with NPDR is lower than those presenting PDR, but the difference is not statistically significant ($p = 0.489$)

DISCUSSIONS

Diabetes is a major public health problem in the world. It has emerged as one of the major health problems in Pakistan.[6] There is no available curative treatment for this disease. With the advent of anti-diabetic drugs, the average life of diabetic patients has increased, but at the same time the incidence of diabetic retinopathy has unfortunately increased many folds.[1] Diabetes is the principal culprit for development of diabetic retinopathy.

The most abundant heteropolysaccharides in the body are the GAGs. They are located primarily on the surface of cells or in the extracellular matrix. Studies on the serum GAGs in diabetic patients showed a decrease in chondroitin-4 and an increase in hyaluronic acid concentrations. Later studies demonstrated that in diabetic patients total serum GAGs concentration was increased.[7] Our results showed that in patients with type 2 DM, the GAGs concentration in tears is significantly greater in patients with poor glycemic control than in the patients with good glycemic control.[8] There is poor control of diabetes in patients with low socioeconomic conditions[9], and majority of patients with proliferative retinopathy with poor glycemic control belongs to low socioeconomic conditions.[6] Results of our studies reveal that GAG's concentration is significantly higher

in patients with proliferative diabetic retinopathy as compared to those with non proliferative DR. Another study reveals enhanced urinary excretion of GAG's in patients of DM, possibly explained by pathological changes related with distortion of the charge selective barrier and increase permeability of the glomerular basement membrane.[10] In other words, the high urinary GAG concentration might be a marker of glomerular involvement in diabetes mellitus. In the same context, according to our results, the high tear fluid excretion of GAGs may be a marker of lacrimal gland involvement in diabetes mellitus. However the exact origin of these GAGs based on the data in this study is difficult to be identified, but the lacrimal gland can be listed as possible origin.

Our results revealed that the GAGs concentration in Type 2 diabetic patients with poor glycemic control is significantly higher than the patients with good glycemic control. This result is in agreement with other studies which showed that the total serum GAGs concentration is increased, particularly in patients with poor blood glucose control.[11] This increase is expected to bear on the altered glucose metabolism in diabetic patients.[8]

The results in this study showed that there is a significant relationship between the increase of tear fluid GAG concentration and the severity of diabetic retinopathy. We can use this as a tool to prevent the adverse outcome in form of progression of diabetic retinopathy. By measuring GAG's concentration in tears we can have an idea of disease progression that is a cost effective procedure with minimal invasion. However further studies are required in order to establish the exact origin of GAGs in tears and its biochemical role in diabetic retinopathy.

CONCLUSION

Diabetic retinopathy (advanced stages) is associated with an increased concentration of GAG's in tears of patients with poorly controlled DM in patents of type 2 DM.

REFERANCES

1. *Zhang X, Saaddine JB, Chou CF, Cotch MF, Cheng YJ, Geiss LS, Gregg EW, Albright AL, Klein BEK, Klein R. JAMA.Aug 2010;304(6):649-56.*
2. *Kayani H, Rehan N, Ullah N. Frequency of retinopathy among diabetics admitted in a teaching hospital of Lahore. J Ayub Med Coll. Abbottabad. 2003,15(4):53-6.*
3. Al-Amer RM, KhaderY. Prevelance and risk factors of diabetic retinopathy among Jordian patients with type 2 diabetes. Digital journal of ophthalamology. 2008;14(2):
4. Komosinska VK, Olezyk K, Kozma EM, et al. Alterations of glycosaminoglycan metabolism in the development of diabetic complications in relation to metabolic control. Clin Chem Lab Med. 2005;43(9):924-9.
5. Memon S, Ahsan S, Riaz Q, Basit A. et al. Frequency, severity and risk indicators of retinopathy in patients with diabetes screened by fundus photograph: a study from primary health care. PJMS.2014;30(2):366-72.
6. Ruta LM, MaglianoDJ, LeMesurier R, et al. Prevalence of diabetic retinopathy in type 2 diabetes in developing and developed countries. Diabetic Medicine. 2013;30(4):387-98.
7. Cadaval RAM, Kohlman O, Michelacci YM. Urinary excretion of glycosaminoglycans and albumin in experimental diabetes mellitus. Glycobiology. 2000:10(2);185-92
8. Han J, Zhang F, Xie J, Linhardt RJ, Hinebert LM. Changes in cultured endothelial cell glycosaminoglycans under hyperglycemic conditions and the effect of insulin and heparin. Cardiovascular Diabetology. 2009;8:46
9. Hassan K, Loar R, Anderson BJ, HeptullaRA. The role of socioeconomic status, depression, quality of life, and glycemic control in type 1 diabetes mellitus. The Journal of Pediatrics. October 2006;149(4):526-31.
10. Poughasam M, Nasiri E, Sum S, Shafi H. The assessment of early glycosaminoglycan concentration changes in the kidney of diabetic rats by critical electrolyte concentration staining. Int.J M Cell Med. 2013;2(2):58-63
11. Moschos MM, Rouvas AA, Papadimitriou S, Kolsolis A, Sitaras N, Apostolopoulos M. Quantitative determination of glycosaminoglycans in tears of diabetic patients. Clin Ophthalmol. 2008 sep; 2(3):581-4

11th Convocation of Rawalpindi Medical College (RMC) for the year 2012 & 2013

Dr. Muhammad Aslam

Mr. Ahsan Iqbal Chaudhary

Prof. Dr Muhammad Umar

RMC faculty with fresh graduates

Rawalpindi Medical College (RMC) held its 11th convocation to award degrees to graduates who have passed MBBS in the year 2012 and 2013 under University of Health Sciences (UHS), Lahore.

Federal Minister of Planning and Development Ahsan Iqbal Chaudhary was the chief guest, while the Vice Chancellor at the University of Health Sciences, Lahore Maj. Gen. (r) Muhammad Aslam was the guest of honour. The convocation ceremony was hosted by the Chairman Board of Management of Allied Hospitals Dr. Muhammad Aslam and the Principal & Chief of Allied Hospitals, Professor Dr. Muhammad Umar.

390 graduates received the degrees. Dr. Irsa Munir was declared as the best graduate of the RMC for the year 2012 while Dr. Asma Tameez ud Din was declared as the best graduate for the year 2013. Medals and certificates were awarded to the graduates who got distinctions in various examinations.

Speaking on the occasion, the chief guest advised the fresh graduates to work with devotion for the betterment of the ailing humanity especially serving population in peripheral areas of the country. The RMC Principal Prof. Dr Muhammad Umar, a devoted Rawalian, highlighted the academic and research activities of students and the faculty. Tracing the history, he said that the RMC was established in March 1974 at Faisalabad and was shifted to its present premises in November the same year. From the humble beginning, the college picked itself up to become one of the premier institutions of the country. So far 37 batches comprising 8422 doctors have already graduated from

this institution and they are now playing important role in the health care and medical education all over the world. Their level of academic and research achievements bear the testimony of their dedication and untiring efforts of the faculty.

Maj. Gen (R) Prof. Muhammad Aslam , Vice

Chancellor and Guest of Honor from University of Health Sciences, Punjab, Lahore expressed his complete satisfaction for the establishment of the state-of-the-art departments of Medical Education, Gastroenterology Unit, Department of Emergency and Critical Care (DEC), Department of Infectious Disease (DID) and Multi Organ Failure Unit (MOF) in its hospitals. He also noticed that the other departments are also being refurbished with infrastructure and equipments, and hectic efforts being made to improve the patient management at the RMC allied hospitals. He expected that the fresh graduates will spare no effort in bringing a good name to its Alma- Mater by ameliorating the sufferings of the ailing humanity through selfless service, good professional conduct and devotion to the duty.

Prof. Yasin Durrani

Chief Editor

Fruit & Health

AMAZING BENEFITS OF BANANA

S. Farheen Toor M.A

Students taking one banana at breakfast increases their mental alertness during examination.

Banana is a herbaceous flowering plant in the genus Musa. The fruits come from two wild species –*Musa acuminata*, (dessert bananas) *Musa balbisiana* and *Musa paradisiaca*. (cooking bananas). Banana cultivation goes back to at least 5000 BCE at Kuk Swamp in the Western Highlands Province of Papua New Guinea. Political maneuvers, which gave rise to the term Banana republic for states like Honduras and Guatemala played the international interests of the big powers, especially during the Cold War, to keep the political climate favorable to their interests. In east Africa, bananas are of greatest importance as a staple food crop. Bananas are prone to fungus *Fusarium oxysporum* and *Black Sigatoka* popularly known as Panama Disease which attacks the roots of the banana plant. If bananas are too green, they can be put in a brown paper bag with an apple or tomato overnight to speed up the ripening process.



Export bananas are picked green, and ripen in special rooms which are air-tight and filled with ethylene gas to induce ripening. Flavor and texture are also affected by ripening temperature. Bananas are refrigerated to between 13.5 and 15 °C (56.3 and 59.0 °F) during transport. The skin of ripe bananas quickly blackens at 4 °C (39 °F).

Bananas are naturally slightly radioactive, because of small amounts of the isotope potassium-40 found in naturally occurring potassium which helps in maintaining body's circulatory system. Bananas supply proper carbohydrates necessary to replace the muscle glycogen. Bananas are rich in vitamin B6 which regulates the blood glucose level. Due to the presence of vitamin B with other minerals which lessens the effect of nicotine with drawl by releasing tryptophane which is converted to serotonin. Students have noticed mental alertness during examination if they eat banana at breakfast. Finally it has been established that bananas are rich in iron which helps in improving the anaemia.

Bananas is a major staple food crop for millions of people in developing countries. In most tropical countries, green (unripe) bananas used for cooking similar to potatoes. Both can be fried, boiled, baked, or chipped and have similar taste and texture when served. One banana provides about the same calories as one potato. Bananas are among the most widely consumed foods in the world.

Nutritional value per 100 g (3.5 oz)

Energy: 371kJ (89 Kcal), Carbohydrates 2.84g, Sugars 12.23 g, Fiber: 2.6g, Protein: 1.09 g, Thiamine (vit. B_1) 0.031mg (3%) Riboflavin (vit. B_2) 0.073 mg (6%), Niacin (vit. B_3)0.665 mg (4%), Pantothenic acid: (B_5) 0.330.4 mg (31%), Vitamin B_6 0.4 mg (31%), Folate (vit. B_9) 20 µg (5%), Choline9.8 mg (2%), Vit-C 8.7 mg (10%), Iron 0.26 mg (2%), Magnesium 27 mg (8%), Manganese 0.27 mg (13%), Phosphorus 22 mg (3%), Potassium 358 mg (8%), Sodium 1 mg (0%), Zinc 0.15 mg (2%), Fluride: 2.2mg ug

Along with other fruits and vegetables, consumption of bananas may be associated with a reduced risk of colorectal cancer and in women, breast cancer and renal cell carcinoma. Banana ingestion may affect dopamine production in people deficient in the amino acid tyrosine, a dopamine precursor present in bananas. The banana's flavor is due to isoamyl acetate which is one of the main constituents of banana oil.

During the ripening process, bananas produce the gas ethylene and indirectly affects the flavor. Ethylene stimulates the formation of amylase, an enzyme that breaks down starch into sugar, influencing the taste of bananas. On the other hand, yellow bananas taste sweeter due to higher sugar concentrations. Banana chips are a snack produced from sliced dehydrated or fried banana, which have a dark brown color and an intense banana taste. Dried bananas are also ground to make banana flour. Bananas feature prominently in Philippine cuisine, being part of traditional dishes

and desserts like *maruya*, *turrón*, and *halo-halo*. It is a popular dessert in Malaysia, Singapore, and Indonesia.

Banana leaves are large, flexible, and waterproof. They are often used as disposable food containers or as "plates" in South Asia and several Southeast Asian countries. In Tamil Nadu (India) leaves are fully dried and used as packing material for food stuffs and also making cups to hold liquid foods. The banana plant has long been a source of fiber for high quality textiles. In Japan, banana cultivation for clothing and household use dates back to at least the 13th century. In the Japanese system, leaves and shoots are cut from the plant periodically to produce yarns and textiles all performed by hand. In a Nepalese system the trunk is used in rugs with a silk-like texture. These banana fiber rugs are woven by traditional Nepalese hand-knotting methods.

Religion and popular beliefs

In Burma, bunches of green bananas surrounding a green coconut in a tray form an important part of traditional offerings to the Buddha In all the important festivals and occasions of Hindus, the serving of bananas plays a prominent part. Traditionally in Tamil marriages, banana trees are tied on both sides of the entrance of houses to bless the newlyweds. In Thailand, it is believed that a certain type of banana trees may be inhabited by a spirit, **Nang Tani**, (shown in the picture) a type of ghost related to trees that manifests itself as a young woman. Often people tie a length of colored satin cloth around the trunk of the banana tree in order to thwart the spirit. In Malay folklore, the ghost known as Pontianak is associated with banana trees (*pokokpisang*), and its spirit is said to reside in them during the day.

Nang Tani, the female ghost of Thai folklore that haunts banana trees.

Other uses

The large leaves may be used as umbrellas. Banana peel may have capability to extract heavy metal contamination from river water, similar to other purification materials. In 2007, banana peel powder was tested as a means of filtration for heavy metals and radio nuclitides occurring in water produced by the nuclear and fertilizer industries (cadmium contaminant is present in phosphates). When added and thoroughly mixed for 40 minutes, the powder can remove roughly 65% of heavy metals, and this can be repeated. Banana peel has displayed antioxidant activity in vitro, especially from unripe extracts.